
Gamma globulin in experimental herpes simplex keratitis

Armstead B. Hudnell and Suydum Osterhout

The chronic keratitis resulting from the steroid treatment of acute herpes simplex infection of the rabbit cornea was significantly improved by the subconjunctival administration of either human or rabbit gamma globulin, the latter possessing no neutralizing antibody to herpes simplex virus. Virus titrations of this late lesion were consistently negative. The etiological and therapeutic implications of these observations will be discussed. It is suggested they provide additional support to the concept that this chronic inflammatory disease is not related to a continuing virus infection.

The major complication of recurrent herpes simplex corneal infections is the development of a poorly understood chronic inflammatory disease. This late stage of the illness is characterized by the absence of recoverable virus, ineffectiveness of IDU (idoxuridine), some improvement with short-term steroids, and intense stromal involvement.

Recent observations in our laboratory on the natural history of experimental herpes simplex keratitis in the rabbit have further confirmed that the occasional appearance

of this chronic lesion can be significantly increased and readily reproduced by steroid therapy during the acute infectious stage.^{1, 2} This paper will describe the beneficial effect of subconjunctival gamma globulin on this chronic keratitis, and will include related microbiologic observations.

Materials and methods

Virus. The methods used to prepare seed virus and to quantitate virus by plaque assay have been previously described.³ Briefly, primary human amnion tissue culture cells were grown in screw cap tubes to prepare seed virus or assay antibody neutralization tests. Monolayers of cells in two ounce prescription bottles were used for the plaque assay. Herpes simplex virus strain SV was used throughout. In the preparation of seed virus, small inocula were used. Tissue culture supernatant collected after a 40 hour period of incubation at 37° C., and clarified by centrifugation contained between 10⁶ and 10⁷ plaque forming units (PFU) per milliliter. Virus was stable when stored at - 56° C. in Eagle's medium containing 5 per cent horse serum. Seed virus used in the experiments reported was from the sixteenth human amnion cell passage. Virus for inoculation was prepared by diluting stock virus in Eagle's medium containing 5 per cent horse serum. Corneas for virus isolation studies were obtained by 10 mm. trephine, and were placed in tubes

From the Division of Ophthalmology, Bowman Gray School of Medicine, Wake Forest College, Winston-Salem, N. C., and the Department of Medicine and Division of Ophthalmology, Duke University School of Medicine, Durham, N. C. This study was supported in part by Special Fellowship BT-913 from the National Institute of Neurological Diseases and Blindness, National Institutes of Health, United States Public Health Service, and by the United Medical Research Foundation of North Carolina.

Presented before the National Meeting of the Association for Research in Ophthalmology, Atlantic City, N. J., June 20, 1963.

Table I

<i>Experiment</i>	<i>Interval (days)</i>	<i>Drug group</i>	<i>Total doses</i>	<i>Total eyes</i>	<i>Improvement</i>	<i>Worse</i>	<i>No change</i>	<i>Relapse</i>
A	43 to 62	Untreated control		2	0	2	0	0
		Human gamma globulin	1	4	2	1	1	2
B	27 to 49	Untreated control		4	0	4	0	0
		Human gamma globulin	2	4	3	1	0	2
C	20 to 52	Untreated control		2	0	2	0	0
		Human serum albumin	3	4	0	3	1	0
		Human gamma globulin	3	4	4	0	0	0
D	22 to 31	Rabbit beta globulin	3	2	0	2	0	0
		Human serum albumin	3	2	0	2	0	0
		Rabbit gamma globulin	3	2	2	0	0	0
		Human gamma globulin	3	2	2	0	0	0
Random cases	18 to 55 (variable)	Untreated controls		8	1	6	1	0
		Rabbit gamma globulin	1 to 3	7	5	2	0	2
		Human gamma globulin	1 to 3	5	4	1	0	1
Total	18 to 62	Various controls	0 to 3	24	1	21	2	0
		Gamma globulin	1 to 3	28	22	5	1	7
		Rabbit	1 to 3	9	7	2	0	2
		Human	1 to 3	19	15	3	1	5

Table II. Degree of improvement in gamma globulin treated animals

<i>Experiment</i>	<i>Drug group</i>	<i>Mild</i>	<i>Moderate</i>	<i>Marked</i>
A	Human gamma globulin	1	0	1
B	Human gamma globulin	1	1	1
C	Human gamma globulin	1	1	2
D	Human gamma globulin	0	1	1
	Rabbit gamma globulin	0	1	1
Random	Human gamma globulin	1	2	1
	Rabbit gamma globulin	3	1	1
Total	Gamma globulin	7	7	8
	Human	4	5	6
	Rabbit	3	2	2

containing 2.0 ml. of Eagle's medium with 5 per cent horse serum. After flame-sealing the tubes, they were frozen and thawed six times in an alcohol-dry ice bath. After clarification by centrifugation, the supernatant fluids were added to human amnion cell tissue cultures and observed two weeks for cytopathologic effect. Ten corneas with chronic keratitis, ranging from the eighteenth to the sixty-second postinoculation day, were studied by this method. In addition, 6 whole corneas were directly added to similar tissue cultures.

Steroids and virus inoculation. Following topical anesthesia with 0.5 per cent proparacaine hydrochloride, 4 mg. of methylprednisolone acetate was injected subconjunctivally to each eye of all rabbits one day prior to virus inoculation. After making

3 central interlocking circles with a 5 mm. trephine set to depth of 0.05 mm., one drop of diluted stock virus containing 200 to 500 PFU was placed on the cornea. With this method, 100 per cent takes were recorded.

Drugs and treatment. Human immune globulin* processed from a single lot of pooled blood plasma and containing 165 mg. per milliliter was used throughout. Electrophoresis showed it to be over 99 per cent gamma globulin. Neutralization tests against 200 to 300 PFU of herpes simplex virus showed it to contain a titer of 1:512 per milliliter. Human serum albumin* containing 250 mg. per milliliter was used as a control.

*Supplied by Squibb.

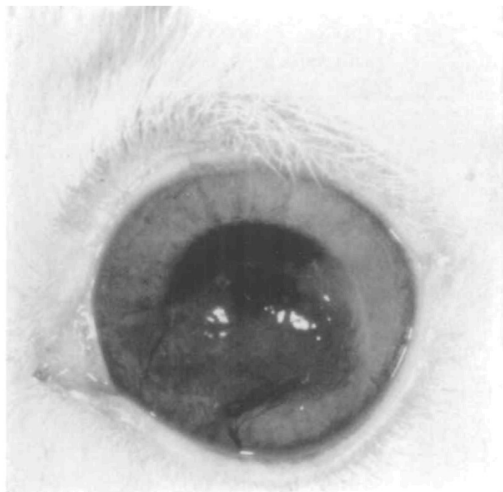


Fig. 1A. Rabbit with chronic herpetic keratitis from Experiment A on forty-third postinoculation day to serve as untreated control.

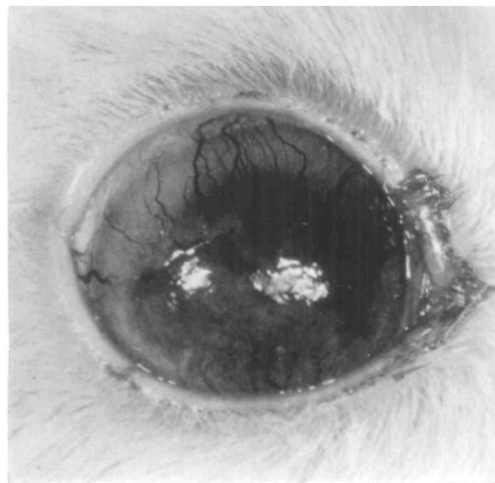


Fig. 2A. Rabbit with chronic herpetic keratitis from Experiment A on forty-third postinoculation day prior to receiving single dose of human gamma globulin.

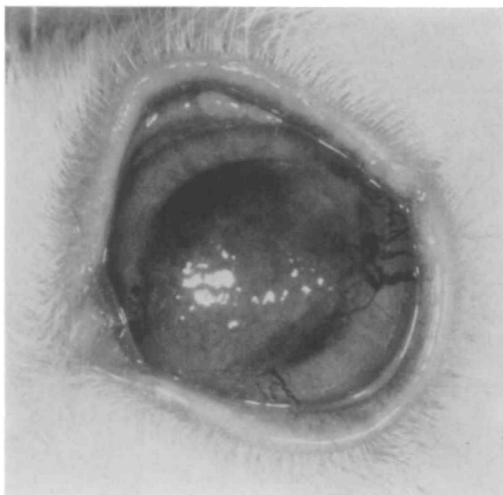

Fig. 1B. Same eye on sixty-second day. Vascularization has progressed.

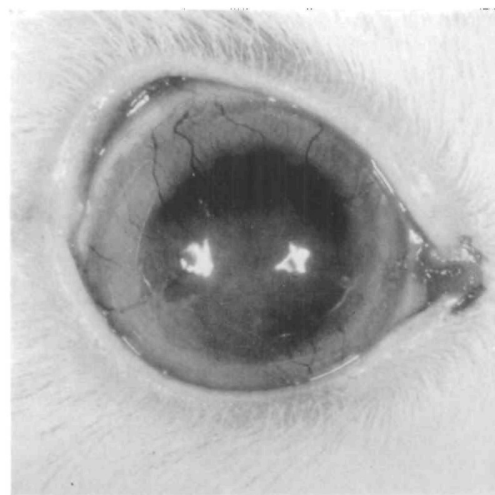


Fig. 2B. Same eye on sixty-second day. Minimal residual inflammation.

Rabbit gamma globulin over 98 per cent pure* was placed in a solution containing 174 mg. per milliliter. No antibody titer to herpes simplex virus could be demonstrated by neutralization tests. Rabbit beta globulin from the same source and prepared in a similar manner was also used as a control.

*Supplied by Pentex, Inc.

Following topical anesthesia, a standard amount of 0.5 ml. for gamma globulin and control solutions was injected subconjunctivally to both eyes of all animals even though the chronic keratitis may have been in one eye only. Repeat injections were given on consecutive days in experiments requiring additional doses.

Animals. Young male and female albino rabbits weighing 4 to 5 pounds were used throughout.

They were housed in separate cages and fed standard Purina rabbit chow.

Experimental procedure. Rabbits developing a chronic keratitis were selected and divided into treatment and control groups at varying times between the twentieth and sixty-second post-inoculation days. With a special ophthalmic camera (Corret Model, Coreco), external color photographs (Kodachrome II) were taken of all eyes prior to treatment, and at varying intervals until the experiment was terminated. All final evaluations were based on these photographic studies, and correlated well with the earlier clinical findings. Experiment D was conducted on a double-blind basis.

Results

The natural history of our chronic herpetic keratitis model was characterized by severe stromal involvement, progressive corneal vascularization, and consistent absence of recoverable virus (Figs. 1 and 3). The clinical course was not significantly altered by either rabbit beta globulin or human serum albumin (Fig. 5). Only one control (4 per cent) had improved by the time of final evaluation (Table I).

Gamma globulin consistently demonstrated a significant therapeutic effect (Table I and Figs. 2, 4, 6, and 7). Statistically, the over-all results, with or without the random group, were highly significant ($P < .01$), with improvement in 79 per cent of cases. Moderate to marked improvement was noted in 68 per cent of the ameliorated cases (Table II). The high relapse rate seen with 1 and 2 doses was eliminated by an increase to 3 doses.

Equivalent results were obtained with either human or rabbit gamma globulin (Tables I and II). Human gamma globulin and serum albumin were well tolerated subconjunctivally, but both rabbit beta and gamma globulin elicited a mild, local reaction, presumably because they had been resuspended in high concentration from a lyophilized state.

The anti-inflammatory effect of gamma globulin was usually evident within 24 hours, and particularly so in those animals with an associated iritis. However, the most impressive final results were obtained in

those with extensive corneal vascularization. Least impressive were the results obtained in chronic disciform type keratitis with minimal vascularization. Characteristically, these disciform lesions rapidly cleared peripherally after beginning treatment, but further improvement was very slow. During this phase of minimal change, 2 animals had mild, self-limiting relapses.

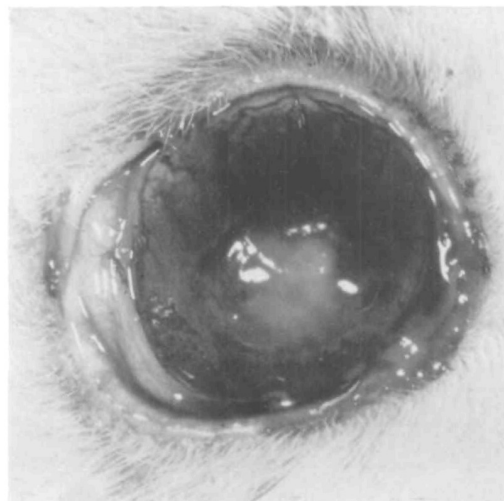


Fig. 3A. Rabbit from Experiment B on twenty-seventh day to serve as untreated control.

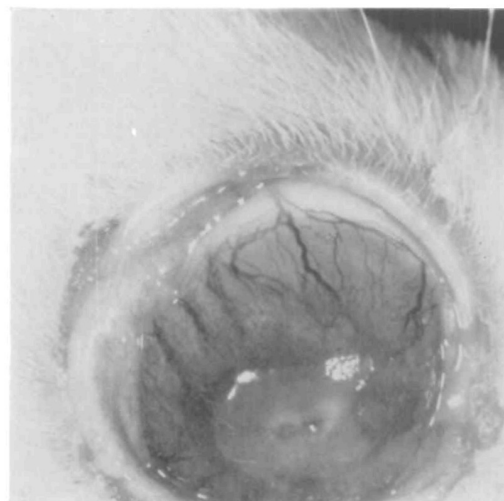


Fig. 3B. Same eye on forty-ninth day. Central area of clearing is seen extending from recent perforation, which has now partially healed.

There were corneal perforations in 3 eyes, all control cases. One was untreated (Fig. 3), but either albumin or beta globulin had previously been given the other two. These perforations were not followed by endophthalmitis but rather by a definite reduction in corneal inflammation and partial healing. This improvement tended to be self-limiting and was most

apparent in the immediate area of the perforation. Secondary bacterial infection could not be demonstrated in these eyes, however, it was documented in 3 of the 7 relapses following gamma globulin therapy.

Most animals with the severity seen in Fig. 7 had demonstrable evidence of secondary infection excluding them from this study, but bacteriologic studies on this eye

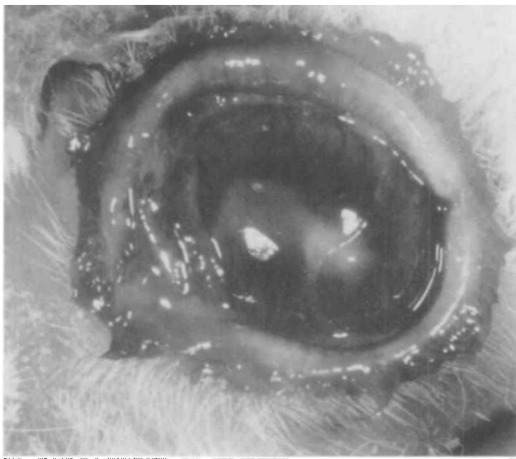


Fig. 4A. Rabbit from Experiment B on twenty-seventh day prior to receiving first of 2 doses of human gamma globulin.

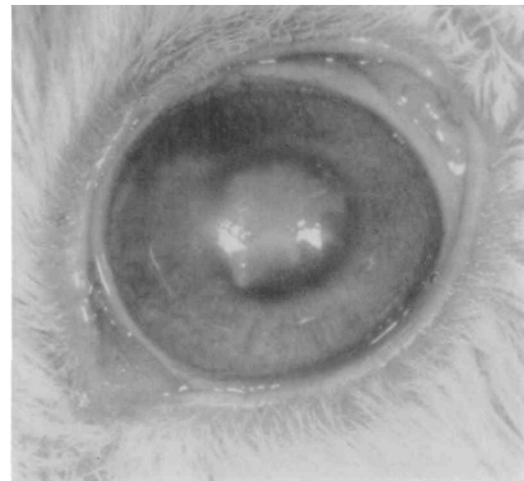


Fig. 5A. Rabbit from Experiment D on twenty-second day prior to receiving first of 3 doses of human serum albumin. Large central ulcer with minimal vascularization at 12:00 o'clock.

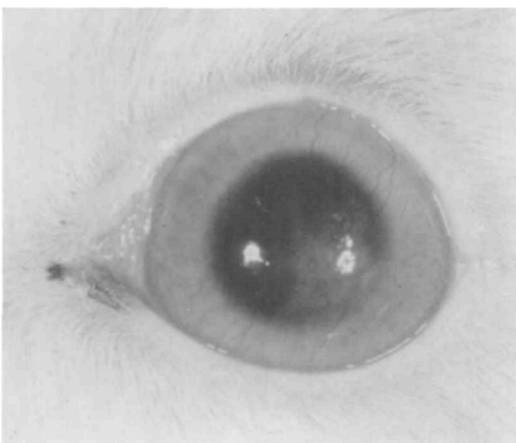


Fig. 4B. Same eye on forty-ninth day. No residual inflammation or staining. Marked regression of vascularization.

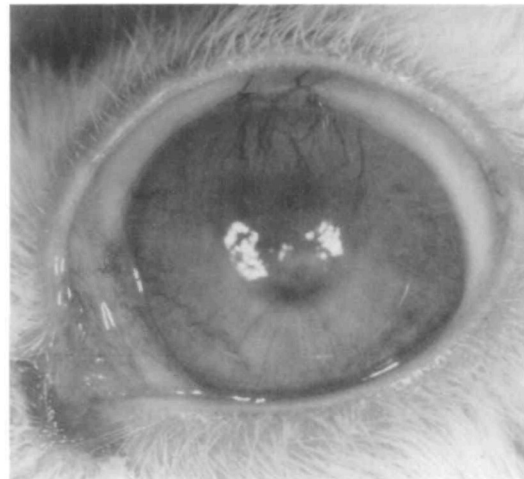


Fig. 5B. Same eye on thirty-first day. Ulcer smaller but marked progression of vascularization.

were negative, and its response to gamma globulin alone was impressive by any criteria. The significant improvement continuing long after the last dose noted in this case was characteristic of most animals receiving gamma globulin.

Discussion

All efforts to treat symptomatic virus infections with specific antibody have been uniformly unsuccessful. Our experience with human gamma globulin in the acute infectious stage of herpes simplex keratitis provided further confirmation.⁴ Thus, the improvement of the keratitis in the chronic stage following subconjunctival gamma globulin, both with and without specific antibody, provides another major distinguishing characteristic between the two stages.

Our failure to recover virus from the cornea during the chronic stage is consistent with the past efforts of others and with the apparent ineffectiveness of IDU therapy. On the basis of the available evidence, it must be concluded that the basic disease process operative during the chronic stage is not related to actual virus multiplication.

However, we have already shown that the same steroid dose used in this study to increase the incidence of chronic keratitis will also increase the yield of virus and temporarily prolong the phase of virus recoverability.¹ In normal rabbits, virus could be recovered from the cornea only through the ninth postinoculation day, but, with steroids, this period was extended up to 5 additional days. Significantly, there was no depression of the specific antibody response.

Nevertheless, there is no indication that the favorable corneal response associated with gamma globulin results from any direct viral effect. In fact, recent preliminary results suggest the earliest a beneficial effect can be definitely obtained with gamma globulin coincides approximately with the usual time of viral disappearance.

A high incidence of secondary bacterial

infection was associated with the use of steroids in these experiments. Because of this, it was difficult to obtain sufficient, typical, chronic stage cases for this study. Since bacteriologic studies were normally not carried out until time for final selection

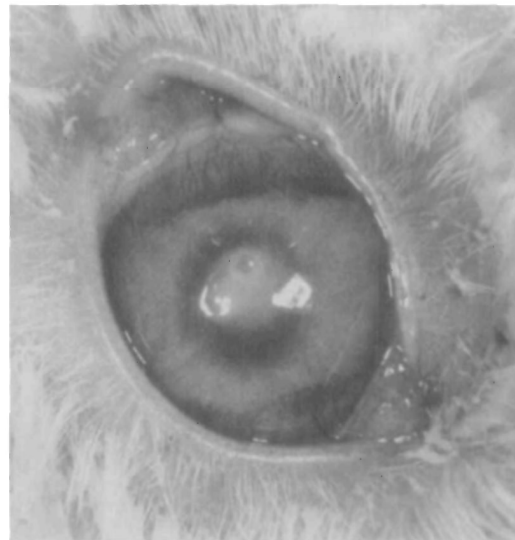

Fig. 6A. Rabbit from Experiment D on twenty-second day prior to receiving first of 3 doses of human gamma globulin. Central ulcer with mid-stromal defect. Vascularization at 6:00 and 12:00 o'clock.

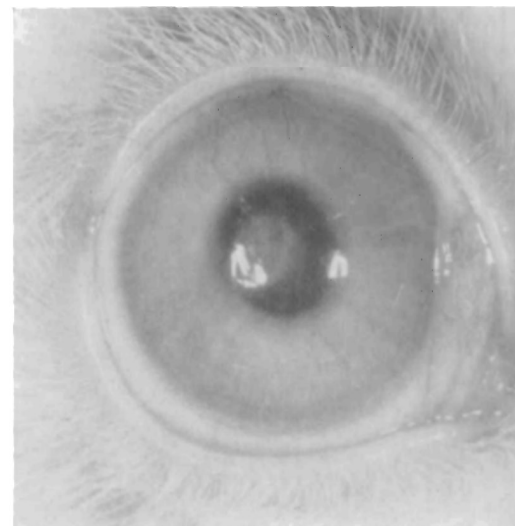


Fig. 6B. Same eye on thirty-first day. Residual stromal opacity but defect has disappeared and there was no perforation. Marked regression of vascularization.

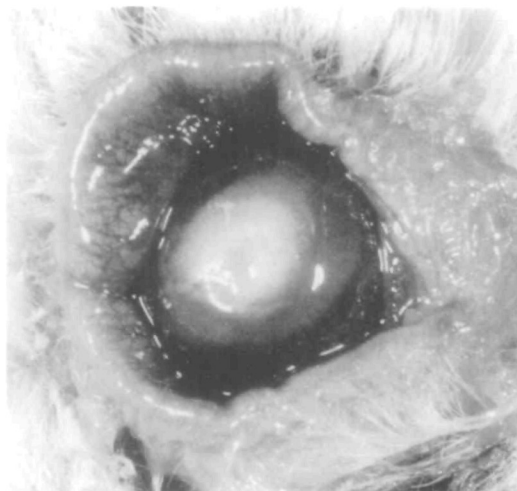


Fig. 7A. Unusually severe case from Experiment C on twentieth day prior to receiving first of 3 doses of human gamma globulin.

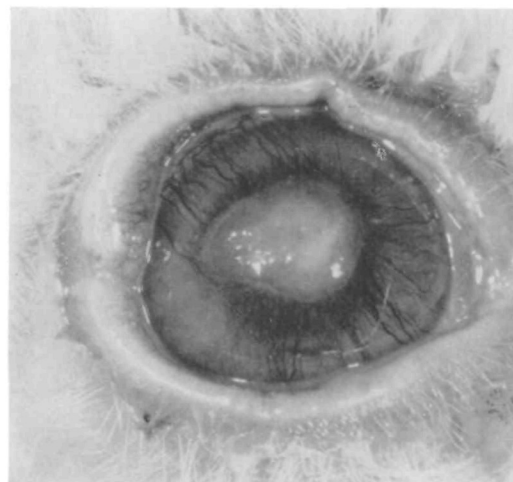

Fig. 7B. Same eye on twenty-sixth day. Considerable healing in only 6 days with no perforation. Central disciform lesion is twice normal thickness.

of animals for a particular experiment, it is possible that some rabbits included in this study had earlier developed a transient secondary infection. In fact, we have histologic evidence which suggests such a possibility. Several 9 and 12 day corneas from steroid-treated rabbits, which clinically did not appear to be secondarily infected, were found to have within the stroma small intense inflammatory foci surrounding a tiny cluster of bacteria. Conceivably, these minute areas of secondary infection could be eradicated by the host without the precise etiology of the intensified inflammatory response becoming clinically apparent. Interestingly, a recent study has demonstrated that a strain of *Staphylococcus aureus* grown in vivo was definitely more sensitive to human gamma globulin than the same strain grown in vitro.⁵

Surprisingly, there is little specific evidence either for or against the possibility of a relatively mild, transient, secondary bacterial infection serving as an etiological factor in the subsequent development of a chronic stage keratitis. Although many studies have demonstrated the adverse effect of steroids on the natural history of

herpes simplex keratitis, they have generally not attempted to evaluate the importance of secondary bacterial infection as a contributing factor.^{2, 6}

However, in an established chronic keratitis, there is already considerable evidence against a continuing bacterial or mycotic infection. Also, we still have no direct evidence that any of the rabbits used in this study were actually infected at the start of a particular experiment. Most animals selected had a distinctly different clinical appearance and course from those excluded because of proved secondary infection.

The paradoxical improvement following corneal perforation, which was noted in 3 control cases, probably represents, at least in part, an effect of endogenous gamma globulin (Fig. 3). Prior to the extensive prophylactic use of corneal grafts in such cases, this was a relatively common clinical observation. The usual and probably best explanation is that the resultant plasmoid aqueous, with its high gamma globulin content, is able to penetrate easily the diseased corneal stroma because the normal endothelial-Descemet's membrane barrier is obviously ineffective at the site of

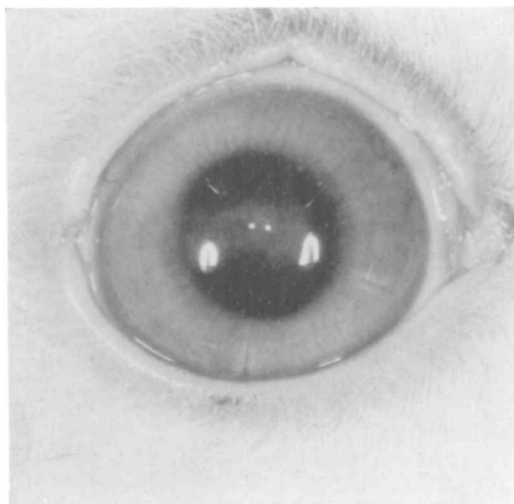


Fig. 7C. Same eye on fifty-second day.

perforation. The corneal clearing in all 3 rabbits began in the perforated area and then extended toward the limbus. Significantly, this improvement was apparently self-limiting, presumably because the perforation rapidly healed, thus restoring an effective barrier to gamma globulin.

The initial results of gamma globulin therapy in humans with chronic herpetic keratitis have been encouraging. Of 6 patients treated, only 1 failed to improve and this case was essentially unchanged. All doses, averaging about 0.3 c.c., were given subconjunctivally and were well tolerated. The subsequent use of short-term

topical steroid therapy in 3 cases resulted in still further improvement.

The traditional roles of antibody in immunity are being significantly modified as cellular factors are receiving increasing emphasis.⁷ The unique and unexpected nature of the problems associated with cases of hypogammaglobulinemia has invalidated many of the established concepts concerning gamma globulin. It now seems apparent that gamma globulin performs vital functions in areas not previously considered.

REFERENCES

1. Osterhout, S., and Hudnell, A. B.: The effects of steroids on herpetic keratitis, *Clin. Res.* 11: 211, 1963.
2. Kimura, S. J., Diaz-Bonnet, V., and Okumoto, M.: Herpes simplex keratitis. An experimental study, *INVEST. OPHTH.* 1: 273, 1962.
3. Osterhout, S., and Tamm, I.: Measurement of herpes simplex virus by the Plaque technique in human amnion cells, *J. Immunol.* 83: 442, 1959.
4. Hudnell, A. B., and Osterhout, S.: Unpublished data.
5. Beining, P. R., and Kennedy, E. R.: Characteristics of a strain of *Staphylococcus aureus* grown in vivo and in vitro, *J. Bact.* 85: 732, 1963.
6. Howard, G. M., and Kaufman, H. E.: Herpes simplex keratitis (Special review), *A. M. A. Arch. Ophth.* 67: 373, 1962.
7. Wolstenholme, G. E. W., and O'Connor, C. M., editors: *Cellular aspects of immunity*, Ciba Foundation Symposium, Boston, 1960, Little, Brown & Company.