
The oculorespiratory cardiac reflex in the dog

William S. Joffe and Andrew J. Gay

Intraorbital and intracranial electrical stimulation as compared with manual eye pressure indicates that in the dog the afferent pathway for the oculorespiratory cardiac reflex is carried by the ophthalmic division of the fifth cranial nerve. The effects on cardiac and respiratory arrhythmia produced by using intravenous atropine have demonstrated that, although reflex bradycardia can be abolished, respiratory arrest is more profound and lasts for a significantly longer period of time.

Electrical stimulation studies in the cat have defined the afferent pathway of the oculorespiratory reflex.^{6, 8} Although no cardiac changes were observed in the cat, Aserinsky and others^{1, 2, 3, 5} have indicated that in the dog bilateral manual pressure on the eyes produced both respiratory and cardiac changes. The present study was designed to determine the afferent pathway of this combined reflex in the dog, to compare the effect of ocular pressure to that of electrical stimulation, and to investigate the role of atropine in modifying this reflex.

Methods and materials

Electrical stimulation, dissections of the orbit, and recording of respiration and electrocardiogram were performed as described previously.⁶

Twenty-six adult dogs, weighing 13.5 to 25 kilograms, were selected for study. The criterion for selection was that under Diabital^o anesthesia

the dogs gave a positive oculorespiratory cardiac reflex in response to manual pressure on the eye. With few exceptions, it was found that positive responders were among the older animals (7 years or older).

In twenty animals ungraded manual pressure was applied to each eye separately until an oculorespiratory cardiac reflex occurred. The pressure was continued until the spontaneous resumption of a normal respiratory rhythm was observed. This procedure was carried out on each eye separately and the response compared with simultaneous binocular pressure. Following this, in all animals, the intraorbital contents were dissected, the nerves to the extraocular muscles, and the frontal branch of the fifth cranial nerve were isolated and each stimulated with voltages varying between 3 and 10 v., with a frequency of 150 c.p.s. and a duration of 0.01 msec.

Subsequent to intraorbital stimulation, in a few animals, the ipsilateral intracranial portion of the ophthalmic division of the fifth nerve was isolated and stimulated immediately rostral to the Gasserian ganglion.

Atropine was administered intravenously to six animals following manual orbital pressure. Monocular or binocular pressure was reapplied five, fifteen, thirty, and forty-five minutes post injection, and the pre- and postatropine responses were compared.

In five animals atropine was given until the cardiac reflex was completely abolished. This amounted to a dosage of 0.015 mg. per kilogram to 0.016 mg. per kilogram. In one dog, weighing 13.5 kilograms, the drug was given intravenously in a stepwise fashion beginning with 0.006 mg.

From the Department of Ophthalmology and Oscar Johnson Institute, Washington University School of Medicine, St. Louis, Mo.

This investigation was supported in part by Research Grants NB 00621-11 and NB 03693-04 from the National Institute of Neurological Diseases and Blindness, National Institutes of Health, United States Public Health Service.

^oPentobarbital sodium, 60 mg. per milliliter.

per kilogram. The respiratory-cardiac reflex was repeatedly evaluated as atropine was increased to a total of 0.023 mg. per kilogram.

Results

A. Manual pressure. Immediately following digital pressure to one eye there was a relative expiratory arrest. Concomitantly, there occurred a transient bradycardia. No essential difference was noted between pressure applied to the right or the left eye. Simultaneous binocular pressure usually produced a more profound respiratory arrest associated with similar bradycardia (Fig. 1).

B. Intraorbital and intracranial stimulation. Stimulation of any of the individual nerves to the extraocular muscles invariably produced a similar expiratory

arrest that was determined by the strength of the stimulus usually resulting in a transient apnea and bradycardia (Fig. 2, A). Increasing the voltage resulted in a more profound apnea and respiratory dysrhythmia, occasionally leading to an irreversible respiratory arrest with concomitant cardiac slowing (Fig. 2, B).

While intraorbital stimulation of the third, fourth, and sixth cranial nerves produced consistent respiratory prolongation but variable cardiac responses, intracranial stimulation of the ophthalmic division of the fifth cranial nerve consistently led to respiratory and cardiac changes of the same order of magnitude as that produced by monocular digital pressure (Fig. 2, C).

C. Atropine effect. In all animals which gave a positive respiratory and/or cardiac

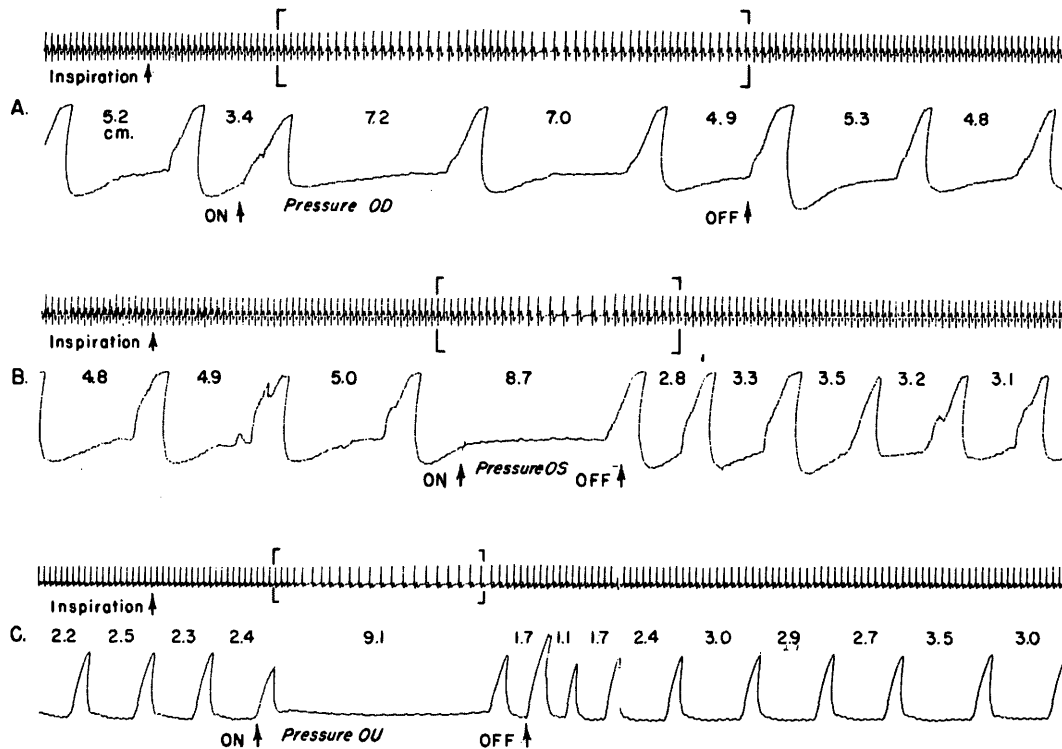


Fig. 1. Illustrates the effects on respiration (below) and electrocardiogram (above) from manual digital pressure on each eye separately. A, right eye; B, left eye. Compare with simultaneous binocular pressure, C. Note typical expiratory prolongation with concomitant bradycardia in each instance which is more pronounced in C when both eyes are compressed. (Recorder speed at 3 mm. per second.)

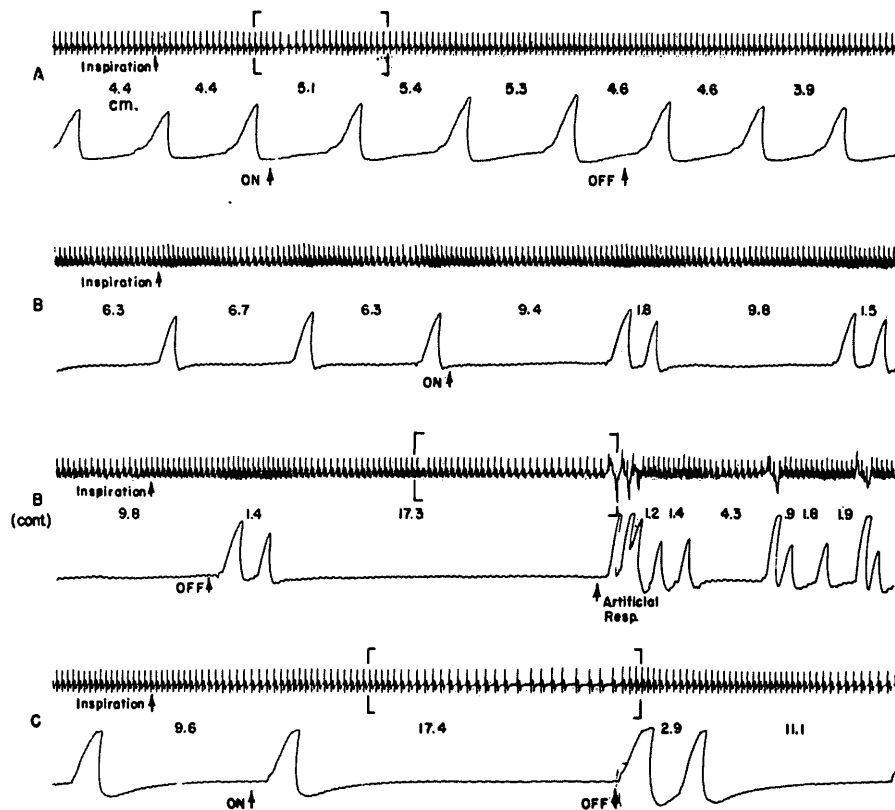


Fig. 2. Demonstrates in the same animal the respiratory and electrocardiographic changes elicited by intraorbital electrical stimulation of the fourth nerve, *A*, the third nerve (to the inferior oblique), *B*, and the ipsilateral intracranial stimulation of the ophthalmic division of the fifth *C*. Note the mild expiratory slowing with transient bradycardia in *A*. In *B*, 10 volts produced marked expiratory slowing and dysrhythmia leading to a complete respiratory arrest, *B cont.* with concomitant bradycardia. Ipsilateral intracranial stimulation of the ophthalmic division of the fifth *C*, with 10v. produced apnea and bradycardia comparable to manual pressure on either eye separately (compare with Figs. 1*A*, and 1*B*).

response to either monocular or binocular digital pressure, there was a profound and reproducible effect produced by intravenous atropine. Following drug injection in physiologic doses, the respiratory arrest was enhanced. Further increases in intravenous atropine produced more profound apnea especially when sufficient quantities were administered to eliminate bradycardia. In other words, the prolongation of the respiratory reflex occurred at smaller doses than that required to abolish cardiac arrhythmia. Thus, when bradycardia was eliminated, a complete respiratory arrest occurred and persisted for a significantly

longer period of time (Figs. 3, *A*, 3, *B*, 3, *C*, and 3, *D*).

Discussion

Previous electrical stimulation studies of the nerves to the extraocular muscles in the cat showed only respiratory dysrhythmia.^{6, 8} However, in the dog, with similar techniques, we were able to produce a respiratory and cardiac slowing from stimulation of these same nerves. The differences in this species response is not thought to be due to a variation in the types of peripheral afferent muscle receptors, since an oculocardiac reflex can be

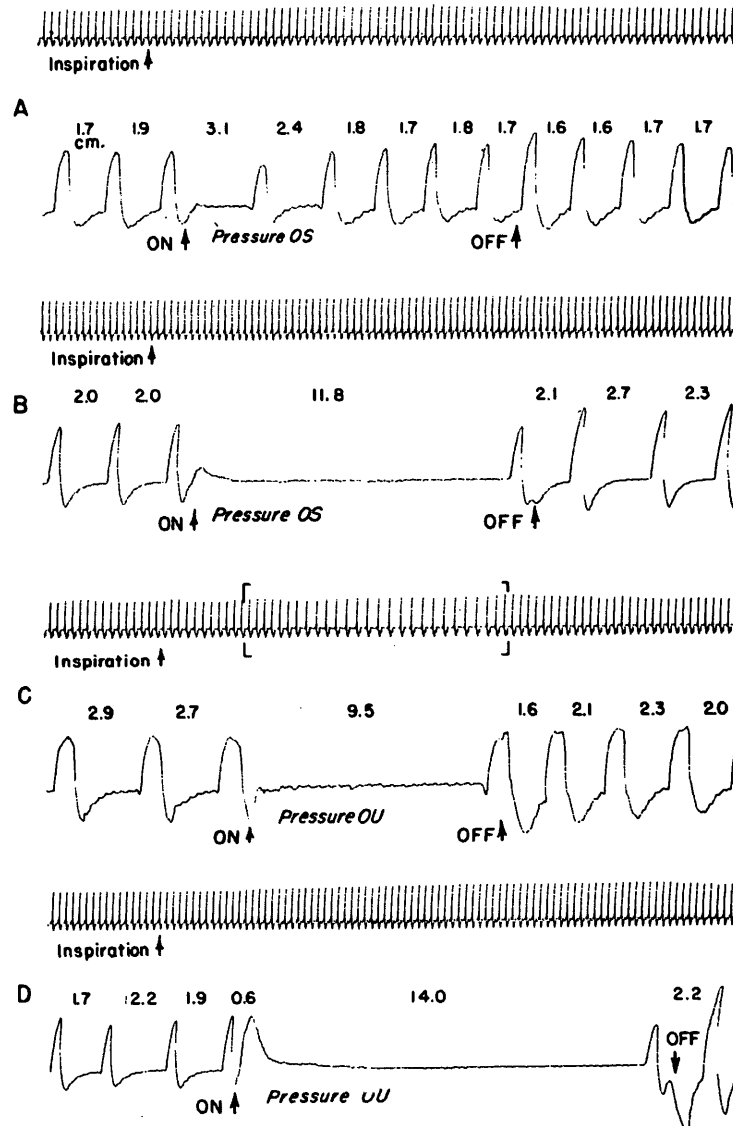


Fig. 3. Changes in respiration and bradycardia, when present, are demonstrated by either monocular, A, B, or binocular, C, D, digital pressure before and after the administration of intravenous atropine. In A the initial effect on respiration by pressure on the left eye before atropine is illustrated. Note the profound apnea, B, occurring 15 minutes post atropine injection. In C, both expiratory slowing and bradycardia are present from simultaneous ocular pressure. In D, bradycardia is abolished but respiratory arrest is significantly enhanced.

produced in the monkey which has been shown to be lacking muscle spindles.^{7, 14} Thus, it is more likely to be the result of some unknown central brainstem mechanism.

Of greater importance is the fact that oculo-respiratory cardiac reflexes can be

produced by intraorbital stimulation of the nerves to the extrinsic muscles of the eye and that these effects are more profound when the ophthalmic division of the fifth is stimulated intracranially. This would suggest that the oculo-respiratory cardiac reflex in the dog as described by Aserinsky

and others^{1, 2, 3, 5} is mediated over the same afferent pathway as that defined for the oculorespiratory reflex in the cat.^{6, 8}

Since previous clinical studies indicate that atropine abolishes the cardiac component of this reflex,^{4, 9, 10, 12, 13} it is of significant interest that this drug has the opposite effect on respiration. This differential effect of atropine on cardiac and respiratory components is most likely related to the differences in their efferent pathways since it has been shown that cardiac arrhythmia can be abolished by vagotomy without altering respiratory changes.^{2, 5} In the present study, in each instance, respiratory arrest was always more profound and persisted for longer periods of time following intravenous atropine. While this is contrary to the results of a previous study,¹¹ the discrepancy is probably attributable to the fact that extremely small doses of atropine were used in this earlier investigation. In the present study, atropine was given in amounts comparable to those recommended clinically for the abolition of the oculocardiac reflex.^{4, 9, 10, 12, 14} For instance, previous investigators have indicated that it is frequently necessary to augment the routine preoperative atropine with one or more doses intravenously at the time of surgery. In the dog, at doses of atropine comparable to the above combined clinical dosage, there was profound enhancement of the oculorespiratory arrest.

These findings strongly suggest that the recommended use of atropine to suppress the oculocardiac reflex in ophthalmic surgery may not be without untoward respiratory effects.

The authors gratefully acknowledge the criticisms and helpful suggestions made by Dr. William Landau, of the Department of Neurology, and Dr. Robert Dodd, of the Department of Anesthesiology.

In addition, the authors extend their appreciation to Miss Robyn Knefel and Mrs. Winona Layne for the technical assistance given.

REFERENCES

1. Aschner, B.: Concerning a hitherto not yet described reflex from the eye on circulation and respiration, *Wien. klin. Wchnschr.* **21**: 1529, 1908.
2. Aserinsky, E., and BeBias, D. A.: Ocular compression causing CNS reaction other than the oculocardiac reflex, *Fed. Proc.* **19**: 300, 1960.
3. Aserinsky, E., and DeBias, D. A.: Suppression of the oculocardiac reflex by means of respiratory movements, *Physiologist* **4**: 5, 1961.
4. Bosomworth, P. P., Ziegler, C. H., and Jacoby, J.: The oculocardiac reflex in eye muscle surgery, *Anesthesiology* **19**: 7, 1958.
5. Delava, P.: Study of effects of ocular compression on circulation and respiration, *Bull. Acad. roy. Belgique clin. sc.*, p. 196, 1964.
6. Gay, A. J., Joffe, W. S., and Barnet, R.: The afferent course of the oculorespiratory reflex of the third, fourth, and sixth cranial nerves, *INVEST. OPHTH.* **3**: 451, 1964.
7. Gay, A. J., Barnet, R., and Joffe, W. S.: Personal observations in the monkey.
8. Joffe, W. S., Gay, A. J., and Antrim, C. A.: Trigeminal pathway for afferent fibers from the oculomotor nerves, *INVEST. OPHTH.* **5**: 222, 1966.
9. Mendelblatt, F. I., Kirsch, R. E., and Lomberg, L.: A study comparing methods of preventing the oculocardiac reflex, *Am. J. Ophth.* **53**: 506, 1962.
10. Mougeot, A.: Constant suppression of the oculocardiac reflex by atropine, *Compt. rend. Soc. biol.* **76**: 162, 1914.
11. Petzetkis, M.: Oculorespiratory reflex and oculovasomotor reflex in the normal state, *Bull. Soc. méd. hôp. Paris* **37**: 816, 1914.
12. Reed, H., and McCaughey, T.: Cardiac slowing during strabismus surgery, *Brit. J. Ophth.* **46**: 112, 1962.
13. Sorenson, E. J., and Gilmore, J. E.: Cardiac arrest during strabismus surgery, *Am. J. Ophth.* **41**: 748, 1956.
14. Whitteridge, D.: *Handbook of physiology*, in Field, J., Magoun, H. W., and Hall, V. E., editors: *Central Control of the Eye Movements*, Baltimore, 1960, The Williams & Wilkins Company, vol. 2, sec. 1.