

# Herpetic Keratitis in Experimental Vitamin A Deficiency

Diane L. Harchell,\* William J. O'Brien,†† Jerry L. Taylor,†† and Robert A. Hyndiuk†

**Herpes simplex virus type I (KOS) was instilled onto the eyes of rabbits with experimentally induced xerophthalmia (vitamin A deficient) and control animals fed a vitamin A supplemented diet. The severity of the herpes virus-induced corneal disease, assessed by biomicroscopic examination and by counting the number of corneal lesions as well as by determining the virus titers, was significantly less in vitamin A deficient animals than in controls. Infection of the corneas of the vitamin A deficient rabbits with herpes simplex virus did not precipitate keratomalacia. The few lesions present on the corneas of the vitamin A deficient animals were in the corneal periphery, which was less keratinized than the central cornea. Electron microscopy suggested that virus was capable of replicating in the basal and wing cells in the peripheral corneal lesions in the vitamin A deficient animals. These studies indicate that vitamin A deficiency alone may not predispose the host to more severe ocular herpesvirus infections. Invest Ophthalmol Vis Sci 28:238-242, 1987**

An association between measles infection, herpetic corneal infection, and severe xerophthalmia and keratomalacia has been recognized for several years.<sup>1-6</sup> Severe corneal ulceration in malnourished and vitamin A deficient children frequently follows measles infection by 1-4 wk.<sup>1-4</sup> In one report, it was noted that eye scrapings of 16 of 34 malnourished children presenting with "active" corneal ulcers following measles infection produced positive cultures for herpes simplex virus.<sup>4</sup> The children ranged in age from 7 to 42 months. Herpetic lesions have also been observed in the orofacial regions of children with concomitant measles and malnutrition in Africa and elsewhere.<sup>2,4,5</sup> The mechanism which predisposes vitamin A deficient children to severe orofacial and corneal herpes virus infections has not been fully elucidated. Sommer states that herpetic infection may be yet another manifestation of severe underlying malnutrition and that its contribution to the development of measles associated corneal dissolution remains to be determined.<sup>6</sup> The purpose of this study was to determine if acute infection with a strain of herpes simplex virus type I (KOS), known to

produce mild epithelial keratitis in normal rabbits,<sup>7,8</sup> would result in more severe herpetic keratitis or precipitate keratomalacia in vitamin A deficient rabbits.

## Materials and Methods

### Animal Model

One group of New Zealand white rabbits (2.5 to 3.0 kg) was maintained on a diet deficient in vitamin A (test diet No. 77227, Teklad; Madison, Wisconsin). A second group of rabbits was maintained on the same diet supplemented with vitamin A to serve as controls (Teklad; test diet No. 78403). Vitamin A deficient rabbits were selected for entry into the study after maintenance on the vitamin A deficient diet for at least 3 months, after attainment of a plateau in weight gain and presentation with corneal signs of vitamin A deficiency.<sup>9</sup> Animals at this stage are known to have reduced serum vitamin A, whereas those maintained on the supplemented diet have normal levels of serum vitamin A.<sup>9</sup>

During the course of these studies, 20 eyes of 10 vitamin A deficient rabbits were infected with herpes simplex virus type 1 (HSV-1). The corneas of all rabbits in this group presented with a lusterless graying of the epithelium and a central dry, glazed "peau d'orange" appearance prior to infection. Eleven of the 20 eyes also possessed keratinized xerotic plaques in the area of the interpalpebral fissure. Stromal infiltration, necrosis, or neovascularization was not observed in any of the animals entered into the study. Eight rabbits were selected from the group of animals fed the vitamin A-supplemented diet to serve as controls. The corneas of these animals showed no unusual corneal pathology on slit-lamp examination or fluorescein staining.

---

From the Departments of Ophthalmology and Physiology, \*Duke University and Durham Veterans Administration Medical Center, Durham, North Carolina and Departments of Ophthalmology† and Microbiology,‡ Medical College of Wisconsin, Milwaukee, Wisconsin.

Supported in part by NIH grants EY02834, EY01931, EY05279, Veterans Administration Medical Research funds, and an unrestricted grant from Research to Prevent Blindness, Inc.

Dr. Hatchell was a Research to Prevent Blindness, Inc., William and Mary Greve International Research Scholar during the course of this study.

Submitted for publication: September 13, 1985.

Reprint requests: William J. O'Brien, PhD, The Eye Institute, Department of Ophthalmology, The Medical College of Wisconsin, 8700 W. Wisconsin Avenue, Milwaukee, WI 53226.

The eyes of all animals were examined by slit-lamp biomicroscopy and fluorescein staining daily for 7 days after infection and on alternate days thereafter. The clinical appearance of the corneal epithelium and the number and location of herpetic lesions were recorded. The upper and lower cul-de-sac were swabbed with a sterile cotton tipped applicator prior to each clinical examination for determination of HSV-1 titers.

Animals from each group were killed on days 6, 7, and 14 postinfection. The eyes were enucleated and fixed in 2.67% glutaraldehyde in 0.1 M sodium phosphate buffer (pH 7.6). The corneas were excised after 24 hr, rinsed, and postfixed in 2% OsO<sub>4</sub> in the same buffer. This tissue was washed, dehydrated in a graded series of ethanol, embedded in an epoxy resin, and sectioned. Thick sections stained with methylene blue were used to evaluate the extent of epithelial keratinization and to locate epithelial lesions. Thin section of selected areas were examined by transmission electron microscopy.

**Virus**

The KOS strain of herpes simplex virus type 1, used to infect the rabbits, was propagated in a rabbit kidney cell line (RK-13). This strain of virus was selected because it produces discrete, punctate epithelial lesions with minimal stromal involvement. The nature of these lesions in normal rabbits is well characterized by electron microscopy,<sup>7</sup> and the severity of disease can be assessed by counting lesion numbers.<sup>8</sup>

All animals were infected by instilling 10<sup>6</sup> plaque-forming units of virus in both eyes of each rabbit without corneal scarification. The upper and lower cul-de-sac of each eye was swabbed daily and swabs placed in Hanks' balanced salts and frozen at 80°C until assay. The titer of virus shed was determined in Vero cells by assaying the eluant of the swabs by the TCID<sub>50</sub> method.<sup>10</sup>

**Results**

All of the rabbits in the vitamin A deficient and control groups developed herpes virus corneal infections. However, the severity of the herpetic keratitis (based on the number of herpetic lesions and virus titer) was less in vitamin A deficient animals than in controls (Figs. 1, 2). During the period of most severe disease, the number of herpes lesions per cornea was 43 ± 18 ( $\bar{x}$  ± SD) in the animals fed the control diet and 5 ± 7 in the animals fed the vitamin A deficient diet. The few lesions in the vitamin A deficient animals occurred primarily in the peripheral cornea. In contrast, the many lesions present in the eyes of control animals were randomly distributed on the corneal surface. Lesions were of similar size in both groups.

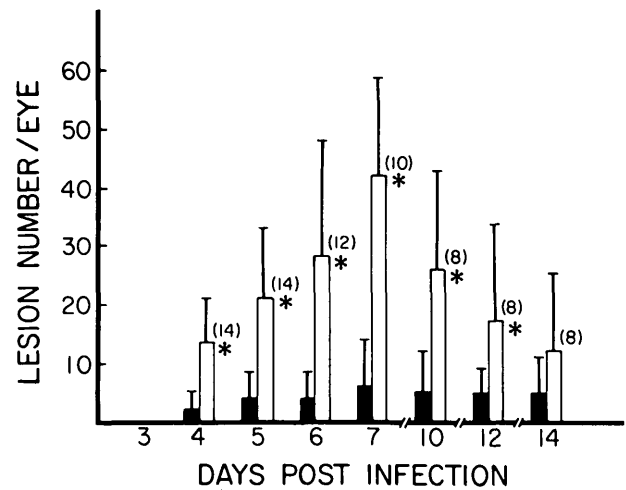


Fig. 1. The effect of vitamin A deficiency on the number of HSV-induced eye lesions on days 4 through 14 postinfection. The fluorescein-staining dendritic lesions characteristic of the KOS strain of HSV were counted with the aid of a slit lamp. Mean lesion number was plotted for the various days postinfection. The open bars represent the mean ( $\bar{x}$ ) and standard deviation (SD) for the pair-fed controls. The solid bars represent the  $\bar{x}$  and SD for the vitamin A deficient animals. Significant difference is shown by (\*), as determined by the student t-test. The number of eyes in each group is contained in the parentheses.

Maximum virus titers were reached on days 5 and 6 in the control and vitamin A deficient groups (Fig. 2). During the period of maximum virus titer, the titers were significantly lower in the vitamin A deficient animals. The mean maximum titer obtained post-infection was 4.0 × 10<sup>4</sup> pfu/eye in controls and 4.0 × 10<sup>2</sup> pfu/eye in deficient animals. The range and standard deviation were large for both groups; however, only 1 of 14 eyes of the control group possessed a titer less

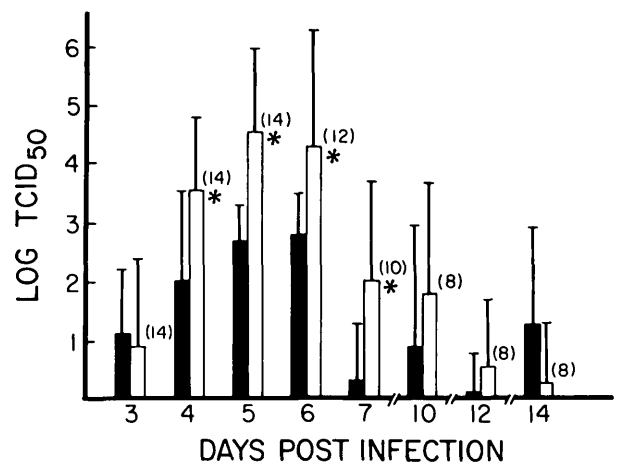


Fig. 2. The effect of vitamin A deficiency on virus titer in the eye. TCID<sub>50</sub> ( $\bar{x}$  ± SD) of HSV obtained from swabs and the upper and lower cul-de-sacs was determined in Vero cells. The symbols are the same as indicated for Figure 1.

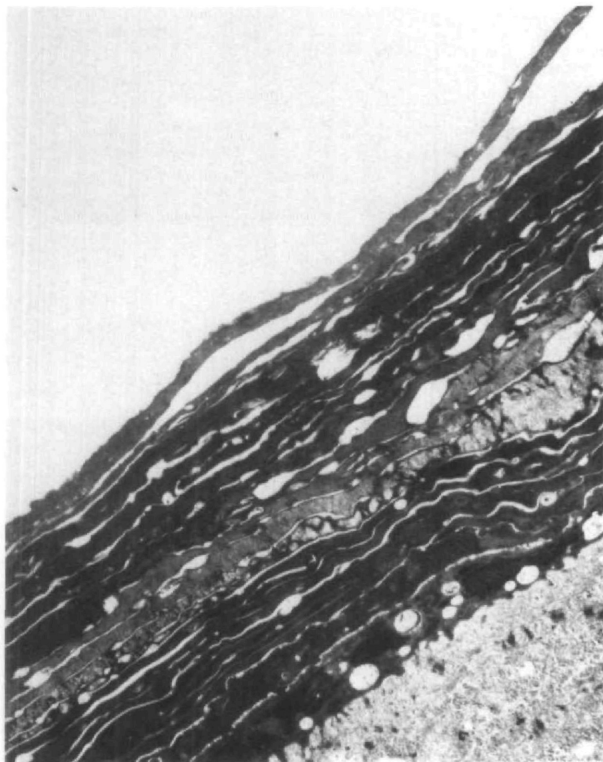


Fig. 3. Accumulation of anucleate keratinized epithelial cells on surface of central cornea in vitamin A deficient rabbit ( $\times 5,300$ ).

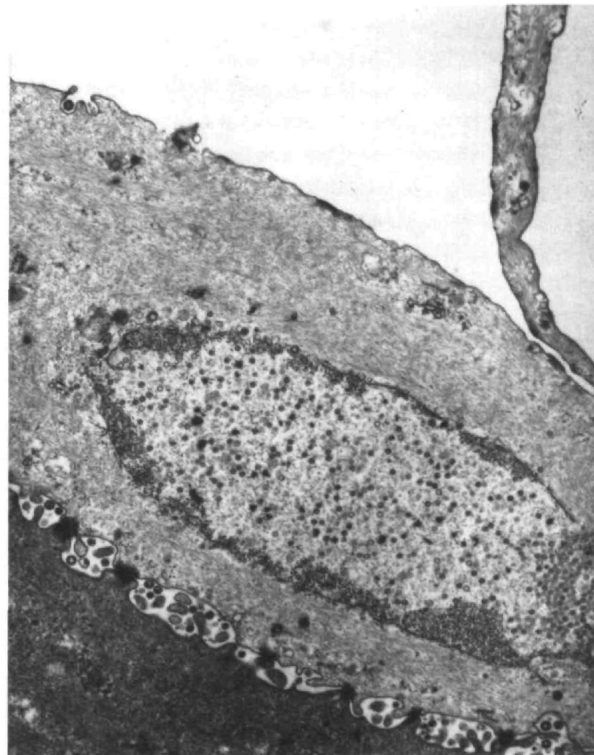


Fig. 5. Single sloughing superficial epithelial cell and herpes virus infected wing cell in lesion in peripheral cornea of a vitamin A deficient rabbit ( $\times 10,200$ ).

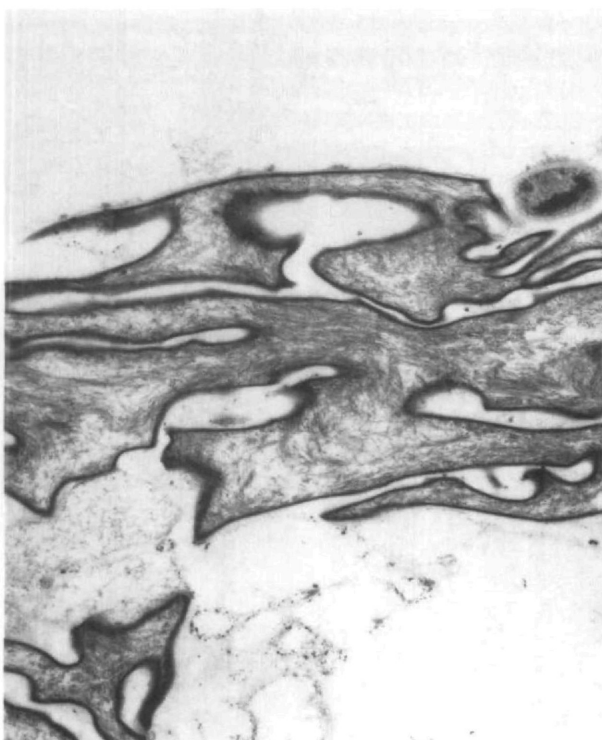


Fig. 4. Thickened cell membrane (cornified envelope) of keratinized epithelial cells in central cornea of vitamin A deficient rabbit ( $\times 7,400$ ).

than  $10^4$  pfu/eye on days 5 and 6 postinfection, whereas only 3 of 14 eyes in the vitamin A deficient animals possessed titers of greater than  $10^4$  pfu/eye. Chi-square analysis showed that significantly greater number of eyes produced high titer virus in the control group than in the vitamin A deficient group.

Multilayers of keratinized superficial epithelial cells were present on the surface of the central cornea (Figs. 3 and 4) of animals fed the vitamin A deficient diet. Keratinization was less extensive in the peripheral cornea. Herpes simplex virus was observed in the wing and basal epithelial cells in the peripheral lesions of corneas from vitamin A deficient animals (Figs. 5, 6) as well as in lesions throughout the corneas of control animals. The presence of large numbers of nonenveloped viral particles in the nuclei and enveloped particles in the cytoplasm supports the hypothesis that virus actively replicated within accessible cells of the cornea of vitamin A deficient animals as well as control animals.

### Discussion

The nutritional status of the host clearly plays an important role in the pathogenesis of infectious diseases. Vitamin A deficiency has been shown to result in compromised epithelial barriers that permit the es-

establishment of opportunistic pathogens such as *Pseudomonas*.<sup>11</sup> In addition, the vitamin A deficiency appears to result in immunological deficiencies in the host that can complicate the course of infection.<sup>12</sup> The mechanisms by which vitamin A alters the pathogenesis of infectious agents are not fully understood. Therapy with retinoids is capable of reducing the severity of herpes virus infections as well as overcoming the immunosuppressive effects of corticosteroids in animals that are not vitamin A deficient.<sup>13,14</sup> The effects of vitamin A in these circumstances, however, are probably not due to direct selective antiviral activity.<sup>13</sup>

The results of this study were surprising in that the eyes of the vitamin A deficient rabbits developed clinically less severe infections (fewer lesions and lower virus titers) than did the control animals. Electron microscopy clearly demonstrated herpes virus in the peripheral lesions of the corneal epithelium of xerophthalmic corneas, but the number of lesions and the number of eyes that possessed high titers of virus was significantly lower among the vitamin A deficient rabbits compared to control animals. The superficial layers of corneal epithelial cells in the interpalpebral fissure in vitamin A deficient rabbits achieve a high degree of morphological and biochemical keratinization (abundant keratohylin granules and anucleate superficial cornified cells with thickened envelopes).<sup>9,15</sup> These cells may not be able to permit the penetration or support the replication of the virus. As a result, only the cells in the periphery apparently served as permissive hosts for virus replication.

In studies recently reported by Nauss et al,<sup>16</sup> the onset of herpetic eye infections was more rapid and clinically more severe in vitamin A deficient rats as compared to pair-fed controls. It should be noted, however, that the animals were infected early in the course of the deficiency when the epithelial layers of the cornea are less keratinized and that the clinical manifestations of the herpes infection were evaluated by a combined rating scale that included a summation of scores for epithelial and stromal disease, conjunctivitis, and iritis. Under the conditions of their experiments, there appeared to be no significant difference in the severity of corneal disease when the animals were infected with high titers of virus ( $3 \times 10^4$  pfu). Principal differences were observed in the iris and ciliary body, which were not evaluated in our study. Nauss et al<sup>16</sup> reported that when animals were infected with lower doses of virus, it appeared that the vitamin A deficient animals were more susceptible to infection. Although some immunological functions of spleen cells were reduced in vitamin A deficient rats, cells of the cervical lymph nodes from vitamin A deficient animals were actually more responsive to mitogens than those of controls.<sup>12</sup> Further, vitamin A deficient animals, when tested early in

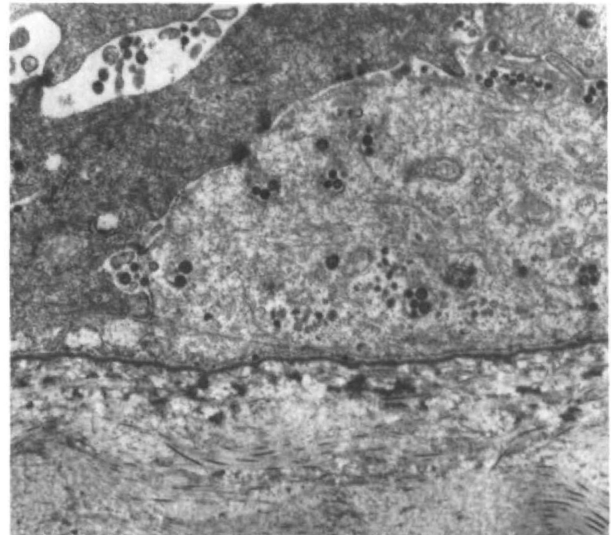


Fig. 6. Herpes viruses between and within basal epithelial cells of the herpetic lesion shown in Figure 3 ( $\times 17,600$ ).

the course of deficiency, were capable of making a local inflammatory response to ocular HSV infections.<sup>12</sup>

The acute infection produced by the strain of HSV-1 used in our study did not precipitate a rapid onset of keratomalacia in vitamin A deficient rabbits. Mere establishment of herpetic keratitis is apparently not sufficient to trigger stromal dissolution. We purposefully selected the KOS strain of virus because it produces a mild, well-characterized epithelial disease that is normally uncomplicated by stromal keratitis. Infections by strains of virus, such as RE or Shealy, which produce more severe corneal disease, might be capable of inducing stromal dissolution, but distinguishing the contribution of severe herpetic disease from other processes contributing to keratomalacia would be difficult.

The role of measles virus infection in precipitating keratomalacia is unclear. A previous or concomitant measles virus infection may be a significant contributing factor leading to corneal dissolution in vitamin A deficient children. Both vitamin A deficiency and measles infections are known to be immunosuppressive.<sup>1,6,12</sup> The resulting immunosuppression in children afflicted with both conditions may be adequate to permit severe secondary infection with herpes or other infectious agents or result in reactivation of latent herpes virus.

**Key words:** vitamin A, Herpes simplex virus, xerophthalmia, keratomalacia

## References

1. Sandford-Smith JH and Whittle HC: Corneal ulceration following measles in Nigerian children. *Br J Ophthalmol* 63:720, 1979.
2. Sauter JJM: Xerophthalmia and Measles in Kenya. Doctoral

- Thesis, University of Groningen, The Hague, Dr. W. Junk B. W., 1976.
3. Sommer A: Mortality associated with mild, untreated xerophthalmia. *Trans Am Ophthalmol Soc* 81:825, 1984.
  4. Whittle HC, Sanford-Smith J, Kogbe OI, Dossater J, and Duggan M: Severe ulcerative herpes of the mouth and eye following measles. *Trans R Soc Trop Med Hyg* 73:66, 1979.
  5. Sach U and Marcus M: Bilateral herpes keratitis during measles. *Am J Ophthalmol* 91:796, 1981.
  6. Sommer A: Nutritional Blindness, Xerophthalmia and Keratomalacia. New York, Oxford University Press, 1982, pp. 129-136.
  7. Francois J, Miraglia O, Victoria-Troncoso V, and Lentini F: Experimental herpetic keratitis: in situ and in vitro study in scanning microscopy. *Ophthalmic Res* 12:205, 1980.
  8. O'Brien WJ and Taylor JL: Chemotherapy of herpetic keratitis induced by acyclovir-resistant strains of herpes simplex virus type 1. *Am J Med* 73,1A:294, 1982.
  9. Van Horn DL, Schutten WH, Hyndiuk RA, and Kurz P: Xerophthalmia in vitamin A deficient rabbits: clinical and ultrastructural alterations in the cornea. *Invest Ophthalmol Vis Sci* 19:1067, 1980.
  10. Klement V and Nicolson MO: Methods for assay of RNA tumor viruses. *In Methods in Virology*, Maramorosch K and Koprowski H, editors. New York, Academic Press, 6:87, 1977, pp. 87-88.
  11. DeCarlo JD, Van Horn DL, Hyndiuk RA and Davis SD: Increased susceptibility to infection in experimental xerophthalmia. *Arch Ophthalmol* 99:1614, 1981.
  12. Naus KM and Newberne PM: Local and regional immune function of vitamin A deficient rats with ocular herpes simplex virus (HSV) infections. *J Nutr* 115:1316, 1985.
  13. Taylor JL and O'Brien WJ: The effects of retinoids on the replication of herpes simplex virus type 1. *Curr Eye Res* 3:481, 1984.
  14. Smolin G, Okumoto M, Friedlaender M, and Kwok S: Herpes simplex keratitis treatment with vitamin A. *Arch Ophthalmol* 97:2181, 1979.
  15. Tseng SCG, Hatchell DL, Tierney W, Huang AJ-W, and Sun TT: Expression of specific keratin markers by rabbit corneal, conjunctival, and esophageal epithelia during vitamin A deficiency. *J Cell Biol* 99:2279, 1984.
  16. Naus KM, Anderson CA, Conner MC, and Newberne PM: Ocular infection with herpes simplex virus (HSV-1) in vitamin A deficient and control rats. *J Nutr* 115:1300, 1985.