

Treatment of Experimental Preretinal Neovascularization Using Photodynamic Thrombosis

Charles A. Wilson,* Peter Saloupis,* and Diane L. Hatchell*†‡

Retinal or preretinal neovascularization (NV) is the result of many ischemic conditions of the retina and is an important factor leading to severe visual loss in diabetic retinopathy. Panretinal photocoagulation does not always control its growth or bleeding sequelae. A potential new treatment modality, photodynamic therapy (PDT), was evaluated for limiting the progression of experimental NV in the rabbit eye. The NV was produced by injecting cultured dermal fibroblasts into the preretinal vitreous space after combined enzymatic and mechanical vitreolysis. This method results in traction retinal detachment with a rapid and consistent growth of NV. After administration of the photosensitizing dye rose bengal (20 mg/kg intravenously), PDT was done using a slit-lamp light source focused through a fundus contact lens (45 J/cm²). The NV was treated on two separate occasions during the active phase of growth (on days 13 and 21 after fibroblast injection). Control animals were exposed to light before injection of rose bengal. Eight randomly assigned animals in each group were followed between treatments and for 28 days after the second treatment. The appearance of NV was documented by frequent photography and fluorescein angiography. The PDT resulted in thrombosis of NV for at least 3 days. Reperfusion, however, was consistently noted at 7 days. Thrombosis was associated with a delay in the growth and maturation of NV fronds, which resumed after reperfusion. Twenty-eight days after the second treatment, NV in both experimental and control eyes had undergone atrophy. At that time (the conclusion of follow-up), however, the size of treated NV fronds (estimated from computerized image analysis of fluorescein angiograms) was significantly less than that of controls. Thus, PDT offers promise as an adjunctive means of temporarily obliterating or stemming the growth of NV in the proliferative retinopathies. Invest Ophthalmol Vis Sci 32:2530-2535, 1991

Preretinal neovascularization (NV) is a manifestation of diabetic retinopathy and many other diseases. Untreated NV may progress to severe visual loss due to vitreous hemorrhage or, more significantly, retinal detachment. Panretinal photocoagulation usually produces regression of NV, for reasons which are uncertain. The practice of focally treating new vessels to occlude them, although advocated during the development of photocoagulation treatment, generally requires light energies which also produce extensive, full-thickness retinal damage.¹ Therefore, focal treatment of NV has been replaced largely by scatter photocoagulation techniques that require less energy and

produce less thermal effects on inner retinal layers. Despite recommended amounts of laser treatment, however, progression of NV has been observed in some individuals.² We wished to develop an alternative treatment for NV that avoids the thermal effects of laser photocoagulation and, therefore, evaluated a potential new modality, photodynamic therapy (PDT), in an animal model of preretinal NV.

In PDT, a photosensitizing dye is administered systemically and activated in blood vessels or other tissues by light of a suitable wavelength. Biologically reactive molecules are produced which lead to tissue damage or, in the case of blood vessels, thrombosis. Most importantly, the photobiologic effects can be produced without substantially heating tissues.³ Potential ophthalmologic uses of PDT that have been explored in animal models include the treatment of corneal⁴⁻⁶ and iris⁷ NV and uveal tumors.^{3,8-10} One photosensitizing agent, hematoporphyrin derivative, has been used in humans for the treatment of choroidal melanoma preliminarily.¹¹

Our study examined the effect of PDT on actively growing NV tufts in a recently developed rabbit model of vitreoretinal fibroblast proliferation.¹² The model was chosen because of its rapid and consistent production of NV tufts over the optic disc and medul-

From the *Department of Ophthalmology, the †Department of Cell Biology, Duke University Medical Center, and the ‡Durham Veterans Administration Medical Center, Durham, North Carolina.

Supported by Veterans Administration medical research funds and National Institutes of Health research grant EY02903 and core grant EY05722. Dr. Hatchell is a Research to Prevent Blindness, Inc. Senior Scientific Investigator.

Submitted for publication: February 9, 1991; accepted April 12, 1991.

Reprint requests: Diane L. Hatchell, PhD, Department of Ophthalmology, Duke University Medical Center, Box 3802, Durham, NC 27710.

lary rays. Rose bengal, previously shown to be effective in producing photochemical thrombosis of normal retinal vessels in the rabbit eye,^{13,14} was used as the photosensitizer.

Materials and Methods

Animals

These experiments were done in accordance with the ARVO Resolution on the Use of Animals in Research. The 16 Dutch-belted rabbits (weight range, 1.0–1.9 kg) used in this study were divided randomly into two equal groups (treatment and control) on day 12 after fibroblast implantation (*vide infra*), at which time the presence of NV could be documented clinically.

Before treatment or examination, the rabbits were anesthetized with ketamine HCl (25–50 mg/kg intramuscularly) and xylazine HCl (5–10 mg/kg intramuscularly). For treatment, the pupils were dilated using cyclopentolate 1% and phenylephrine 2.5%. Pupillary dilation was maintained between follow-up examinations with atropine 1% ointment, which was applied after each examination or treatment.

Production of Preretinal NV

The method developed by Antoszyk et al¹² was used because it produces a high yield of NV. In their study, 95% of eyes developed clinically evident NV by day 14 after intravitreal injection of homologous dermal fibroblasts. Briefly, the method consists of repeated preretinal injection and aspiration of 1 IU of hyaluronidase (in 0.1 ml phosphate-buffered saline [PBS]) over the optic disc and medullary rays. Studies in normal rabbit eyes showed that this dose of hyaluronidase was well tolerated by the retina.¹⁵ Vitreolysis was assisted by sweeping a 25-gauge needle over the medullary rays. Residual hyaluronidase solution and vitreous was aspirated eventually (0.2 ml). Homologous dermal fibroblasts, harvested and cultured as described previously,¹² were injected into the area of vitreolysis (2.5×10^5 cells/0.1 ml PBS) and allowed to disperse in the area of the medullary rays.

PDT

The PDT was done by first positioning the animal on a adjustable stage mounted on a Topcon photo slit lamp (model SL-5D; Paramus, NJ) and stabilizing its head in a stereotactic device. The light intensity of the slit lamp was set to high, and the heat-absorbing filter resident on the instrument was positioned. This filter's transmission is less than 12% at wavelengths greater than 900 nm. The resulting irradiance, measured with a YSI-Kettering model 65A radiometer

(Yellow Springs Instrument, Yellow Springs, OH), was 73 mW/cm². A circular spot of light, 2–5 mm in diameter (slit-lamp setting), was centered and focused on the NV through a plano fundus contact lens, taking care to avoid direct light exposure of the iris. The smallest spot diameter was selected that covered the entire visible area of NV.

Rose bengal (certified purity 90%; Sigma, St. Louis, MO) was prepared in a concentration of 20 mg/ml in normal saline and sterilized by aspiration through a 0.22- μ m filter. With the animal in position as described, the dye was injected (20 mg/kg) through a marginal ear vein. Light exposure was continued for another 10 min (45 J/cm²), after which the rabbit was transferred to a dimly lit room and allowed to recover. Treatments were done during the active phase of NV proliferation: 13 days after fibroblast injection and 8 days later. Control animals underwent the same procedure, except that the rose bengal was injected after the light exposure was completed.

Clinical Examinations

Follow-up examinations consisted of indirect ophthalmoscopy, color fundus photography, and fluorescein angiography at baseline (1 day before the first treatment [12 days after fibroblast injection]); 1, 3, and 7 days after the first treatment; and 1, 3, 7, 14, and 28 days after the second treatment. In the model, NV undergoes spontaneous involution within 42 days.¹² Accordingly, an observation period of 49 days was allowed.

Image Analysis

The size of the NV tufts was estimated by measuring the area of perfused NV in all fluorescein angiograms. To avoid inaccuracies from fluorescein leakage and spread, early-phase photographs were studied. Image analysis was facilitated by the focal nature of NV in the model. One control eye, however, was excluded from analysis because its NV was multicentric and could not be photographed adequately.

Photographic negatives were placed on a light box and viewed by a video camera through a Zeiss dissecting microscope (Carl Zeiss, Inc., Thornwood, NY). Images were digitized and captured on a video board mounted in a International Business Machines 386 microcomputer (Boca Raton, FL) operating JAVA software (Jandel, Corte Madera, CA). The system was calibrated using a standardized area (a notch) found at one corner of each photographic field. This area was defined as 100 square units. The NV was measured by outlining the fluorescein-filling area with the mouse-directed cursor. The area in the outline was computed using the software.

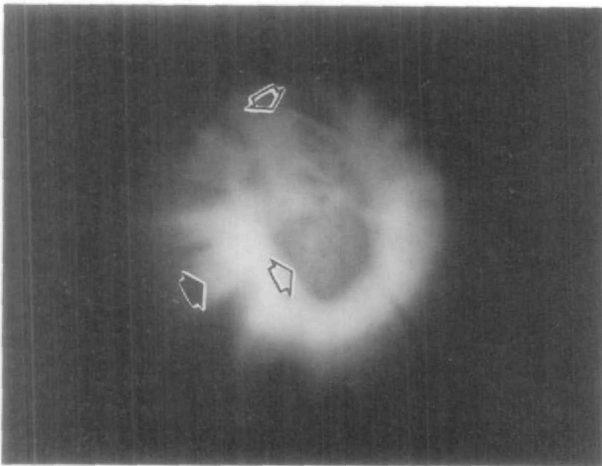


Fig. 1. Fundus photograph showing the slit-lamp biomicroscopic appearance of neovascularization during photodynamic treatment. The illuminated area (solid arrow) includes the neovascular tuft (open arrows). Detached retina surrounds the tuft.

Results

The PDT resulted in a change in the color of the NV tuft from bright to dark red during the 10-min course of light exposure (Fig. 1). Near the end of the treatment, stagnant blood (as evidenced by interruptions in the continuity of the red cell column) occasionally could be visualized in some vessels. When normal myelin wing vessels were in the field of illumination, they underwent partial or complete thrombosis during the course of treatment. Control eyes showed no clinically apparent changes during light exposure.

After treatment, fluorescein angiography revealed nonperfusion of preretinal NV (Fig. 2). Total nonperfusion was seen on posttreatment day 1, with NV silhouetted against the background of choroidal fluorescence. By posttreatment day 3, however, some eyes showed small areas of fluorescein filling and leakage,

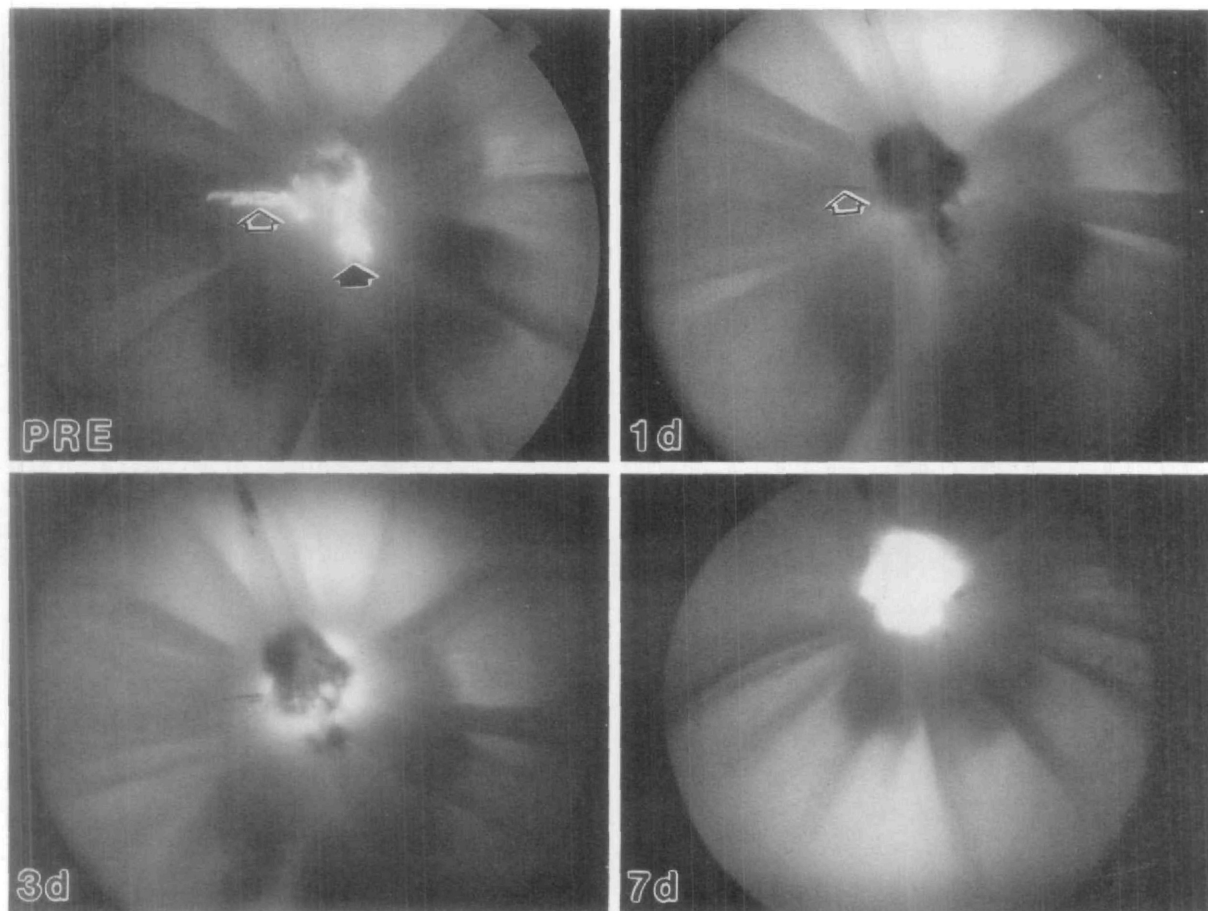


Fig. 2. Angiographic appearance of neovascularization pre- and 1, 3, and 7 days after the first photodynamic treatment. Before treatment, early neovascular growth is noted (solid arrow) adjacent to normal medullary ray vessels (open arrow). Total nonperfusion of both new and normal (open arrow) vessels is observed on post-treatment day 1. At day 3, fluorescein leakage appears behind the neovascular tuft. Finally, at day 7, the neovascularization appears completely reperfused.

usually at the base of the NV tuft. At day 7, NV in all eyes showed complete or near-complete reperfusion. The second treatment reproduced these events. Hemorrhagic complications were not observed at any time. Control eyes showed no angiographic evidence of nonperfusion after light treatment.

The PDT significantly decreased the perfused area of NV (estimated from fluorescein angiograms by computerized image analysis) compared with controls at most follow-up examinations (Fig. 3). After each treatment, there was a reperfusion of NV within 7 days, manifested as a rapid increase in perfused area. Between 7 and 28 days after the second treatment, there appeared to be a slower, parallel rate of increase in NV area in the treated and control groups, with the treated NV consistently remaining smaller. The difference between groups was significant ($P < 0.05$) at both 1 and 3 days after the first treatment and at all examinations after the second treatment (Figs. 3, 4).

Discussion

The clinical effects of PDT on the growth of preretinal NV was examined in a rabbit model of vitreoretinal fibroblast proliferation. Two treatments, 8 days apart, each produced temporary occlusion of NV. Reperfusion generally occurred between 3 and 7 days posttreatment. Growth and maturation of NV was delayed by treatment but not prevented. Treated NV

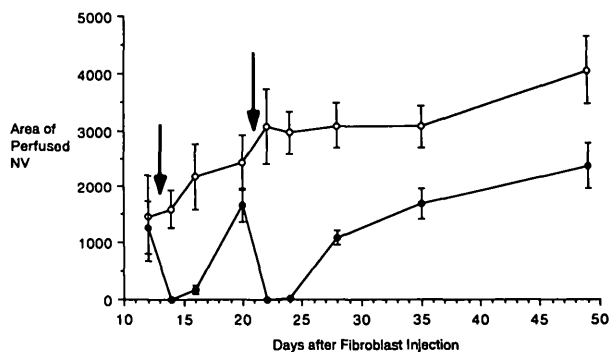


Fig. 3. Area of perfused neovascularization versus days following intravitreal fibroblast injection. Control neovascularization (open circles) showed progressive increase in area, whereas treated neovascularization (closed circles) was temporarily occluded by PDT on days 13 and 21 (arrows). All means represent eight eyes, except at day 3 after the second treatment, when five control and three treated eyes were measured. Statistical comparisons (student t-test, two-tailed) of groups at each follow-up examination were as follows: 12 days ($P = 0.75$), 14 days ($P < 0.001$), 16 days ($P = 0.003$), 20 days ($P = 0.19$), 22 days ($P < 0.001$), 24 days ($P < 0.001$), 28 days ($P < 0.001$), 35 days ($P = 0.01$), 49 days ($P = 0.03$). Variances represent the SEM.

continued to enlarge after reperfusion, but they were smaller than control NV.

The duration of NV occlusion in this study was similar to photodynamic occlusions produced in normal rabbit medullary ray vessels.^{13,14} In these studies, reperfusion occurred by 3 days in major arterioles and by 7 days in major venules. Other reports were mixed regarding the duration of photodynamic vascular occlusion. In the cat eye, rose bengal-sensitized damage of the retinal microvasculature and choriocapillaris produced extensive areas of occlusion with relatively little reperfusion after 4 months of follow-up.¹⁶ Although the major retinal vessels remained perfused, they were not directly targeted during treatment. In a rabbit model of corneal NV, PDT using rose bengal produced long-lasting vessel occlusion.⁶ The mechanism of vessel injury, however, was unclear since argon laser irradiation (514.5 nm) was used at a sufficient power to generate a combined thermal-photodynamic reaction. Another photosensitizing agent, hematoporphyrin derivative, was used to obliterate iris NV in a primate model of branch retinal vein occlusion.⁷ Two of four treated eyes were followed longer than 1 day. Of these, one eye had recurrent (or reperfused) iris NV 8 days after the initial treatment. A second treatment abolished iris leakage for the duration of follow-up (2 months).

There are several factors that may influence the duration of vascular occlusion after PDT. Among these are the composition and size of the clot. Previous studies showed that the initial event leading to vascular thrombosis in PDT is endothelial cell injury and platelet adherence.¹⁷ The resulting clot is fibrin poor, and consequently it is believed to resist the effects of degradation initiated by tissue plasminogen activator.^{6,18} However, fibrin polymer stabilizes platelet plugs, and its scarcity could result in a less stable occlusion. In addition, relatively small clots may not occlude vessels completely or could become fragmented by hemodynamic forces. Another factor that could influence the duration of vascular occlusion is the rate of endothelial cell repair or regeneration. In actively growing NV, a number of retinal endothelial cells are already in a proliferative state. Provided that the initial stimulus for proliferation remains after PDT, uninjured endothelial cells could repopulate damaged vessel lumina or form additional new vessels rapidly. Because mature NV fronds were not evaluated in our study, their response to PDT is uncertain.

The NV growth was estimated by computerized image analysis of fluorescein angiograms. This technique has several obvious disadvantages. First, it is only capable of detecting NV growth in two dimensions; and second, it is subject to error related to ante-

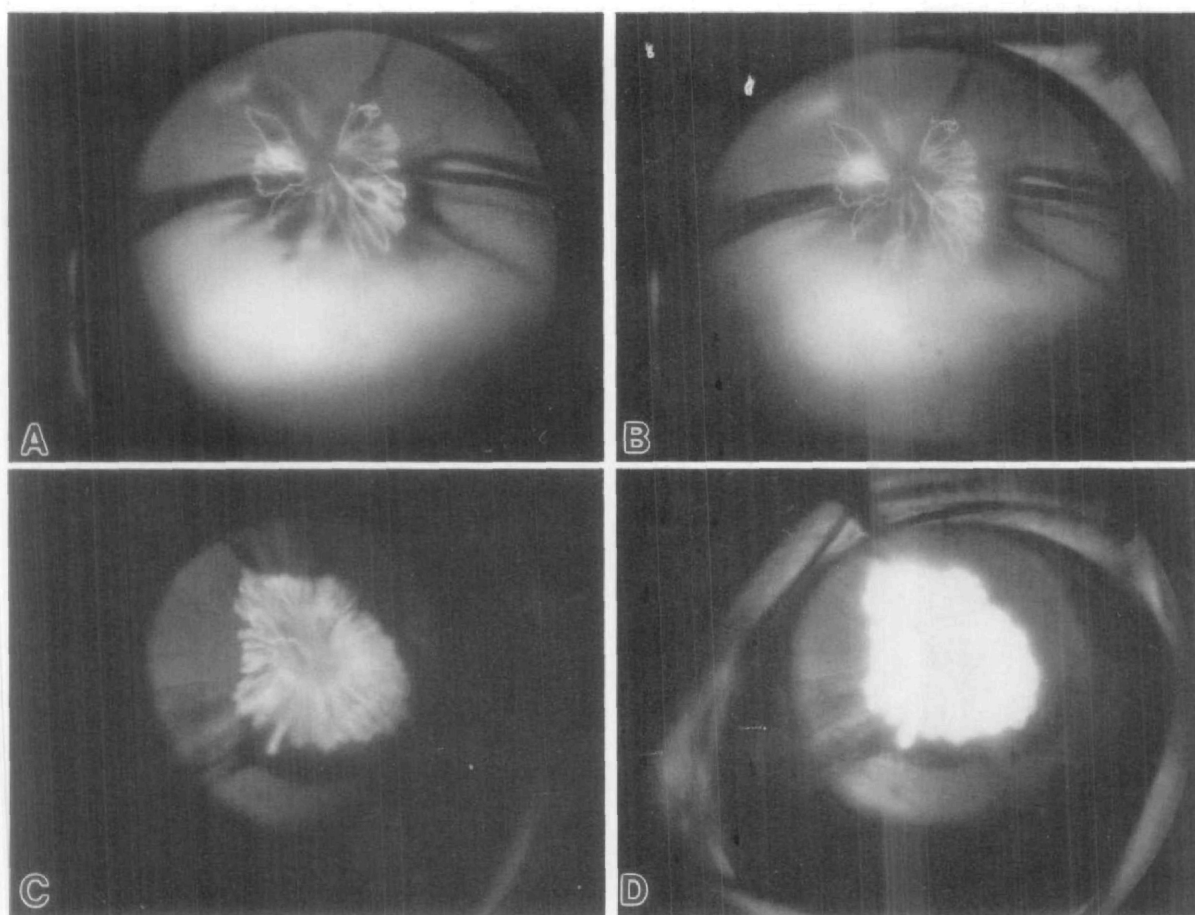


Fig. 4. Angiographic appearance of a representative treated (A, B) and control (C, D) neovascularization 28 days after the second treatment. Early phases are shown in (A) and (C); late phases are shown in (B) and (D). The control neovascularization is slightly larger and shows greater fluorescein leakage than the treated frond.

rior displacement of NV from the fundus which produces a change in image magnification. Fortunately, magnification changes would tend to reduce rather than increase the observed difference between large and small NV tufts. This is because large, extensive NV fronds generally were highly elevated, frequently growing onto and along the posterior lens surface. Small tufts, by virtue of a more posterior location, were relatively magnified. Despite these limitations, image analysis provided an objective estimation of NV growth *in vivo* that would not have been possible otherwise.

There are several mechanisms by which PDT could limit the growth of NV. Most directly, thrombosis of parent vessels deprives potential newer vessel buds of blood supply. Decreased blood supply could also "starve" surrounding tissues including fibroblast colonies. In this case, fibroblasts and perhaps other host cells might either stop proliferating or die, thus interrupting the process of vitreoretinal fibroplasia. Fibroblasts produce a collagen matrix that could be im-

portant for the development of NV. A prominent, multilayered extracellular matrix has been associated with developing NV in a similar rabbit model.¹⁹ Collagen is also one striking feature of many preretinal fibrovascular membranes in severe proliferative diabetic retinopathy.²⁰

The cause of NV in this rabbit model is uncertain. Therefore, its relevance to the proliferative retinopathies in humans must be viewed with uncertainty. However, the model does provide a reproducible form of NV that is localized conveniently and documented and treated easily. The development of NV was described in the rabbit eye using methylmethacrylate vascular casts.²¹ The new vessels budded from retinal veins as early as 3 days after autotransplantation of dermal fibroblasts. They grew into a fibrous tissue matrix and, as early as 4 weeks, formed distal tortuosities and glomerular-like structures. After 3 months, there was an apparent reduction in the overall number of new vessels. In a more recent study, the ultrastructural features of rabbit NV were examined

at various stages of development and were found to resemble those seen in retinopathy of prematurity and proliferative diabetic retinopathy.¹⁹

Effective treatments were developed that lower the risk of complications from proliferative retinopathy. In proliferative diabetic retinopathy, laser panretinal photocoagulation generally is indicated, but sometimes it does not prevent progressive NV.² Therefore PDT potentially is useful in these instances as an adjunctive treatment. One drawback of this approach is that PDT damages normal vessels and NV. It therefore might be better suited for treating peripheral NV than proliferations in the posterior pole. Other photosensitizing agents have been identified (ie, hematoporphyrin derivative and phthalocyanine dyes³) that may be selectively retained in certain tissues, particularly in vascularized tumors. These agents also could be evaluated to determine if photothrombosis can be produced more selectively in NV. Another drawback of PDT is that occlusion of NV is not permanent, even after a second treatment. Perhaps, a combination of low-intensity laser (thermal) and photochemical damage would extend the duration of vascular closure. We currently are exploring these possibilities.

In summary, dye-sensitized photothrombosis of preretinal NV was evaluated in a rabbit model. Two treatments, separated by an interval of 8 days, each completely occluded visible areas of NV. Reperfusion occurred generally from days 3–7. The growth of NV was delayed by treatment, and the size of the NV tuft during the follow-up period was less than that of controls.

Key words: photodynamic therapy, rose bengal, retina, neovascularization, singlet oxygen

Acknowledgments

The authors thank James S. Tiedeman, MD, PhD, for his assistance in the preparation of this manuscript.

References

- Davis MD: Proliferative diabetic retinopathy. *In* Retina, Ryan SJ, editor. St. Louis, CV Mosby, 1989, pp. 367–402.
- Vine AK: The efficacy of additional argon laser photocoagulation for persistent, severe proliferative diabetic retinopathy. *Ophthalmology* 92:1532, 1985.
- Panagopoulos JA, Svitra PP, Puliafito CA, and Gragoudas ES: Photodynamic therapy for experimental intraocular melanoma using chloroaluminum sulfonated phthalocyanine. *Arch Ophthalmol* 107:886, 1989.
- Mendelsohn AD, Watson BD, Alfonso EC, Lieb M, Mendelsohn GP, Forster RK, and Dennis JJ: Amelioration of experimental lipid keratopathy by photochemically induced thrombosis of feeder vessels. *Arch Ophthalmol* 105:983, 1987.
- Huang AJW, Watson BD, Hernandez E, and Tseng SCG: Photothrombosis of corneal neovascularization by intravenous rose bengal and argon laser irradiation. *Arch Ophthalmol* 106:680, 1988.
- Corrent G, Roussel TJ, Tseng SCG, and Watson BD: Promotion of graft survival by photothrombotic occlusion of corneal neovascularization. *Arch Ophthalmol* 107:1501, 1989.
- Packer AJ, Tse DT, Gu X-Q, and Hayreh SS: Hematoporphyrin photoradiation therapy for iris neovascularization. *Arch Ophthalmol* 102:1193, 1984.
- Gomer CJ, Doiron DR, White L, Jester JV, Dunn S, Szirth BC, Razum NJ, and Murphree AL: Hematoporphyrin derivative photoradiation induced damage to normal and tumor tissue of the pigmented rabbit eye. *Curr Eye Res* 3:229, 1984.
- Sery TW and Dougherty TJ: Photoradiation of rabbit ocular malignant melanoma with hematoporphyrin derivative. *Curr Eye Res* 3:519, 1984.
- Winward KE, Dabbs CK, Olsen K, Watson BD, Hernandez E, and DiBernardo C: Encircling photothrombotic therapy for choroidal Greene melanoma using rose bengal. *Arch Ophthalmol* 108:588, 1990.
- Tse DT, Dutton JJ, Wcingest TA, Hermsen VM, and Kersten RC: Hematoporphyrin photoradiation therapy for intraocular and orbital malignant melanoma. *Arch Ophthalmol* 102:833, 1984.
- Antoszyk AN, Gottlieb JL, Casey R, Hatchell DL, and Machermer R: An experimental model of preretinal neovascularization in the rabbit. *Invest Ophthalmol Vis Sci* 32:46, 1991.
- Nanda SK, Hatchell DL, Tiedeman JS, Dutton JJ, Hatchell MC, and McAdoo T: A new method for vascular occlusion: Photochemical initiation of thrombosis. *Arch Ophthalmol* 105:1121, 1987.
- Royster AJ, Nanda SK, Hatchell DL, Tiedeman JS, Dutton JJ, and Hatchell MC: Photochemical initiation of thrombosis: Fluorescein angiographic, histologic, and ultrastructural alterations in the choroid, retinal pigment epithelium, and retina. *Arch Ophthalmol* 106:1608, 1988.
- Gottlieb JL, Antoszyk AN, Hatchell DL, and Saloupis P: The safety of intravitreal hyaluronidase: A clinical and histologic study. *Invest Ophthalmol Vis Sci* 31:2345, 1990.
- Wilson CA, Royster AJ, Tiedeman JS, and Hatchell DL: Exudative retinal detachment following photodynamic injury. *Arch Ophthalmol* 109:125, 1991.
- Povlishock JT, Rosenblum WI, Sholley MM, and Wei ED: An ultrastructural analysis of endothelial change paralleling platelet aggregation in a light/dye model of microvascular insult. *Am J Pathol* 110:148, 1983.
- Watson BD, Dietrich WD, Prado R, and Ginsberg MD: Argon laser-induced arterial photothrombosis: Characterization and possible application to therapy of arteriovenous malformations. *J Neurosurg* 66:748, 1987.
- deJuan E Jr, Humayun MS, Hatchell DL, and Wilson D: Histopathology of experimental preretinal neovascularization. *Invest Ophthalmol Vis Sci* 30:1495, 1989.
- Hamilton CW, Chandler D, Klintworth GK, and Machermer R: A transmission and scanning electron microscopic study of surgically excised preretinal membrane proliferations in diabetes mellitus. *Am J Ophthalmol* 94:473, 1982.
- Tano Y, Chandler DB, and Machermer R: Vascular casts of experimental retinal neovascularization. *Am J Ophthalmol* 92:110, 1981.