

Early Multifocal Electroretinogram Findings during Intravitreal Ranibizumab Treatment for Neovascular Age-Related Macular Degeneration

Claudio Campa,^{1,2} Richard Hagan,² Jayashree N. Sabni,^{1,2} Malcolm C. Brown,² Nicholas A. V. Beare,^{1,2} Heinrich Heimann,^{1,2} and Simon P. Harding^{1,2}

PURPOSE. To evaluate changes in the multifocal electroretinogram (mfERG) in patients with neovascular age-related macular degeneration (nAMD) undergoing ranibizumab treatment.

METHODS. This was an observational, longitudinal, prospective study. Treatment-naïve patients with nAMD who met the inclusion and exclusion criteria underwent a course of monthly injections of ranibizumab over 3 months. At baseline and month 3, each subject was evaluated with best corrected visual acuity (BCVA), contrast sensitivity (CS), fluorescein and indocyanine green angiography, optical coherence tomography (OCT), and mfERG. Additional mfERGs were performed at weeks 1 and 4 and BCVA and OCT at weeks 4 and 8.

RESULTS. Eighteen patients were enrolled. Between baseline and week 12, median BCVA improved from 59 to 69 ETDRS letters ($P = 0.001$), median CS improved from 29 to 30 letters ($P = 0.05$), mean OCT central foveal subfield thickness (CFT) decreased from 294 to 199 μm ($P = 0.005$), mean P1 amplitude density of the mfERG central zone increased from 35.85 to 51.55 nV/deg^2 ($P = 0.009$). The mfERG response correlated positively with BCVA ($F = 22$; $P < 0.0001$) and negatively with CFT ($F = 12.73$; $P = 0.00078$).

CONCLUSIONS. Intravitreal ranibizumab therapy appears to induce an increase in mfERGs centrally in patients with nAMD at least in the short term. Longer term studies to investigate the prognostic value of mfERG responses to predict changes in visual acuity in nAMD and other diseases are warranted. (ClinicalTrials.gov number, NCT01023971.) (*Invest Ophthalmol Vis Sci.* 2011;52:3446–3451) DOI:10.1167/iovs.10-6588

The treatment of neovascular age-related macular degeneration (nAMD) has changed enormously during the past decade. Ranibizumab, an agent that binds all isoforms of vascular endothelial growth factor (VEGF), offers patients a more than 90% chance of maintenance of vision and a more than 30% chance of a significant improvement with monthly administration of the drug.^{1,2} However, the frequent injections present a substantial burden to patients and health care systems. For these reasons, different treatment regimens have been investi-

gated with the intent of maintaining efficacy with a reduced number of injections or visits.^{3–5} Studies to date have used ophthalmoscopy, visual acuity and optical coherence tomography (OCT) criteria to guide retreatment but have as yet failed to show improved effectiveness with changes in regimen.⁶ There is a need to develop other markers of response to guide retreatment as well as to give additional useful information on the functional and structural changes during anti-VEGF therapy.

Multifocal electroretinography (mfERG) is a technique developed by Sutter, which allows detailed study of localized disorders affecting the outer retinal layers.^{7,8} The test gives an objective evaluation and mapping of retinal function from several retinal areas and is thought to reflect the cone-mediated responses from the photoreceptor and bipolar cells under normal test conditions.⁹ Eyes with nAMD show reduced mfERG responses,^{10–12} and they remain largely unchanged during a course of photodynamic therapy.^{13–14} Observational studies have reported fairly consistent short-term improvements in mfERG after varying regimens of intravitreal bevacizumab.^{15–18} Little is known regarding the changes of mfERG in patients receiving ranibizumab. To the best of our knowledge, only one small case series of three subjects has been published to date.¹⁹

We investigated the effects on mfERG of a course of monthly injections of ranibizumab for 3 months, the current standard initiation-phase regimen, in eyes with nAMD involving the foveal center. We also correlated with best corrected visual acuity and spectral domain optical coherence tomography (OCT).

METHODS

An observational, longitudinal, prospective, single-center study was conducted in the Clinical Eye Research Centre of St. Paul's Eye Unit, Royal Liverpool University Hospital, according to the tenets of the Declaration of Helsinki. The study was approved by the local research ethics committee. Inclusion criteria were (1) nAMD in first or second eyes with angiographic signs of active choroidal neovascularization (CNV) involving the foveal center (i.e., leakage in late phases of fluorescein angiogram); (2) best corrected visual acuity (BCVA) ≥ 35 ETDRS letters; (3) any lesion type (classic, predominantly classic, occult, minimally classic CNV, retinal angiomatous proliferation); (4) stable fixation; and (5) mentally and physically fit. Exclusion criteria were (1) any previous treatment for nAMD in the study eye; (2) spherical equivalent ≥ -6 D; (3) clinical/angiographic signs of fibrosis $\geq 75\%$ of the lesion; (4) no features of AMD; (5) unstable medical status (in particular cardiovascular disease which in the opinion of the investigator would preclude participation in the study); (6) amblyopia in the study eye; (7) any other ocular disease that could affect macular function in the study eye (e.g., glaucoma, diabetic retinopathy).

From the ¹Department of Eye and Vision Sciences, University of Liverpool, Liverpool, United Kingdom; and the ²St. Paul's Eye Unit, Royal Liverpool University Hospital, Liverpool, United Kingdom.

Supported by Foundation for the Prevention of Blindness
Submitted for publication September 16, 2010; revised January 7 and February 5, 2011; accepted February 6, 2011.

Disclosure: C. Campa, None; R. Hagan, None; J.N. Sabni, None; M.C. Brown, None; N.A.V. Beare, None; H. Heimann, None; S.P. Harding, None

Corresponding author: Claudio Campa, St. Paul's Eye Unit, Royal Liverpool University Hospital, Prescot Street, Liverpool L7 8XP, UK; claudio.campa@yahoo.com.

TABLE 1. Summary of the Investigations Performed at Each Time-Point of the Study

Time Point	BCVA	Reduced Vision Protocol	CS	Complete Ophthalmic Examination	Color Fundus Photos	FA/ICGA	OCT	mfERG	IVT
Baseline	+		+	+	+	+	+	+	+
Week 1				+				+	
Week 4		+		+			+	+	+
Week 8		+		+			+	+	+
Week 12	+		+	+	+	+	+	+	+

After a prescreening evaluation by a panel of at least three retinal specialists, the patients underwent a full ophthalmic examination, including BCVA and contrast sensitivity (CS) measurement, dilated fundus examination, OCT, color fundus photos, fluorescein and indocyanine green angiography. BCVA and CS were measured in a full refraction protocol with standardized illumination by externally accredited optometrists and recorded as letters read at 4 m on Early Treatment Diabetic Retinopathy Study (ETDRS) charts and 1 m on Pelli-Robson charts, respectively. If a patient read less than 20 letters at 4 m, then the BCVA test was performed at 1 m. Final BCVA letter score was calculated by the number of letters read at 4 m plus 30 (or letters read at 1 m). After an explanation of experimental procedures, patients who consented to join the study received a course of monthly intravitreal injections of ranibizumab for 3 months and underwent mfERG before the first injection and at weeks 1, 4, and 12. The time between diagnosis of CNV and treatment did not exceed 6 weeks. At weeks 4 and 8, the patients were studied only with OCT and a reduced visual acuity protocol, using the baseline refraction. All investigations were repeated at week 12 as performed at baseline. Study investigations at each time point are summarized in Table 1.

OCT scans were all obtained with the same machine (Topcon 3D OCT-1000; Topcon Medical Systems, Inc.). Central foveal thickness (CFT) was calculated from the mean of the central subfield by the on-board software from the map generated by raster scans composed of 256×512 (vertical \times horizontal) axial scans covering a 6×6 -mm region centered on the foveal center. Any segmentation errors at the internal limiting membrane and/or at the apical retinal pigment epithelium within the central foveal region (center 1 mm) were identified and corrected manually before analysis (Fig. 1).

Stereoscopic 35° fluorescein and indocyanine green angiography were performed with a scanning laser ophthalmoscope (Heidelberg

Retina Angiograph [HRA]; Heidelberg Engineering GmbH, Heidelberg, Germany).

The mfERG was recorded with a CRT monitor (Retiscan; Roland Consult, Wiesbaden, Germany) projecting stimuli from 19 segments scaled 4:1, across 43° of the field, and a red fixation cross extending to all four corners of the screen, to facilitate central fixation. We choose this pattern of stimuli to increase the amount of signal per hexagon, improving SNR (signal-to-noise ratio) per unit time. The larger hexagons (the central spot was 5.3° in diameter) also reduce reliance on central fixation which is often compromised in patients with advanced central loss of vision. Furthermore, the patients were coached for steady fixation and observed throughout the test. The stimulus from each of the 19 segments was controlled by a binary sequence (m-sequence). Each stimulus step comprised the presence or absence of a single frame flash ($2 \text{ cd} \cdot \text{s/m}^2$) followed by four black frames. mfERGs were recorded monocularly from each eye with DTL thread electrodes referenced to each outer canthus and a ground electrode placed at Fpz (middle of forehead). mfERGs were acquired at 2 to 200 Hz and digitally filtered between 1 and 50 Hz. The 19 responses were then averaged into three concentric rings containing 1, 6, and 12 segments (radii were 2.65°, 2.65–10.75°, and 10.75–21.75°, respectively), cursor and described by the P1 amplitude density (nV/deg^2) and latency (ms). The P1 amplitude was measured from N1 trough to P1 peak whereas the P1 latency was the time from the onset of the light stimulus until the P1 peak.

For statistical analysis, the Shapiro-Wilk test was used to evaluate the distribution of data. For data with normal distribution comparisons between different time points were performed with paired *t*-test for two time points or repeated-measures ANOVA followed by post hoc analysis for more than two time points. For data with non-normal distribution, the Wilcoxon test was used in the case of two time points

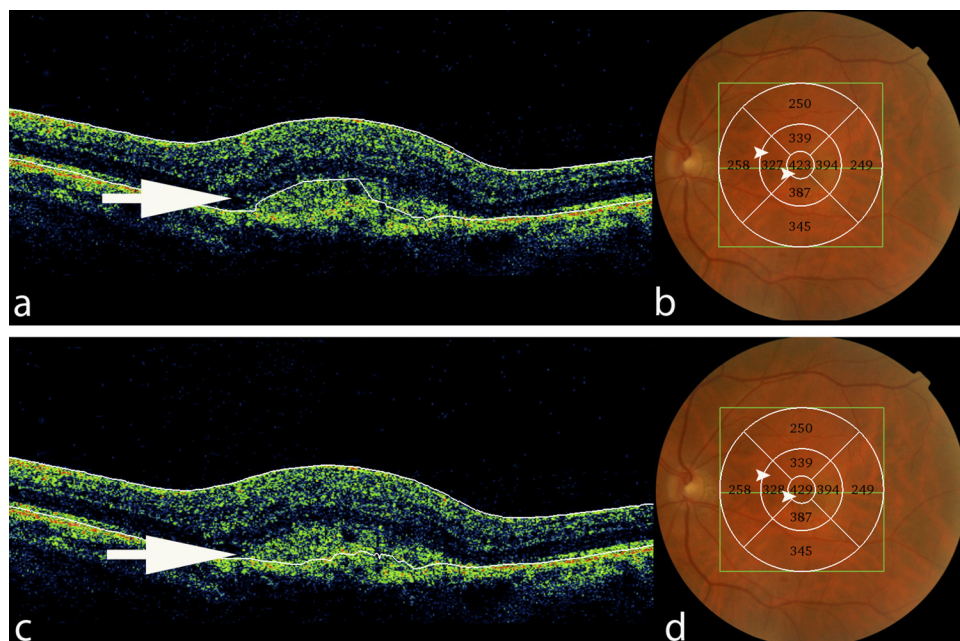


FIGURE 1. Example of OCT measure: in this image, a segmentation error in the retinal pigment epithelium line (a, arrow) was manually corrected (c, arrow). This correction caused a change in the retinal thickness (b, d, arrowheads).

or the Friedman test followed by post hoc analysis for more than two time points (IBM SPSS Statistics 18; SPSS Inc., Chicago, IL, and R, <http://cran.r-project.org/>).

RESULTS

Between January and October 2009, 40 subjects were screened: 18 met the inclusion-exclusion criteria and were included in the study. They were 5 men and 13 women with a mean age of 76.67 (SD \pm 5.6; range, 64–84) years. Classic CNV was diagnosed in three eyes, predominantly classic in one, minimally classic in one, occult in eight, and retinal angioma-tous proliferation (RAP) in five.

Mean BCVA at baseline was 56.72 (SD \pm 13.96; range, 36–79) ETDRS letters. Changes in BCVA over the 3 months are shown in Figure 2. A statistically significant difference from baseline was noted only at week 12 ($P = 0.001$; Friedman test followed by a multiple comparison procedure based on the Tukey-Kramer critical value).

Mean CS increased from 28.55 (SD \pm 3.48; range, 20–33) letters at baseline to 30.11 (SD \pm 2.51; range, 23–33) at week 12: this difference was not statistically significant ($P = 0.053$).

Mean CFT before treatment was 294.22 (SD \pm 115.05; range, 141–478) μ m: a statistically significant reduction of CFT was observed as early as 4 weeks of therapy ($P = 0.03$) and persisted at 8 ($P = 0.01$) and 12 ($P = 0.005$) weeks (repeated-measures ANOVA with LSD test; Fig. 3).

This change in CFT may at least in part explain the decrease in median spherical equivalent from 1.93 D at baseline to 1.37 D at week 12 ($P = 0.02$, Wilcoxon test). In particular, the median CFT decreased from 325 μ m at baseline to 193.5 at week 12. Since a 1-mm change in axial length is equivalent to approximately 3 D, a 131.5- μ m change would mean a change in refractive status of approximately -0.4 D.

mfERG responses showed a statistically significant progressive improvement after each ranibizumab injection. The mean P1 amplitude density of the central ring increased from 35.85

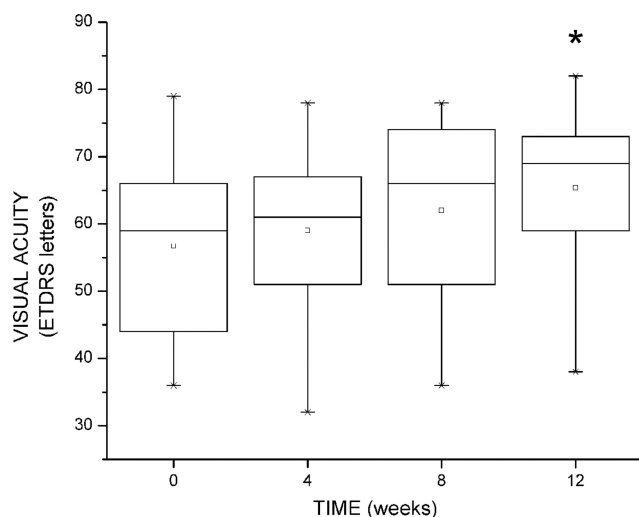


FIGURE 2. Boxplots of visual acuity at baseline (week 0) and weeks 4, 8, and 12. Visual acuity was measured with a full refraction protocol at weeks 0 and 12 and with a reduced protocol at weeks 4 and 8. The *top* edge (hinge) of the box indicates the 75th percentile and the *bottom* hinge indicates the 25th percentile of data. The *line* and the *square* in the box indicate the median and the mean values, respectively. The ends of the vertical lines (*whiskers*) indicate the minimum and maximum data values. Mean visual acuity in Snellen equivalent was approximately 20/72, 20/66, 20/57, and 20/50 at 0, 4, 8, and 12 weeks, respectively. * $P = 0.001$.

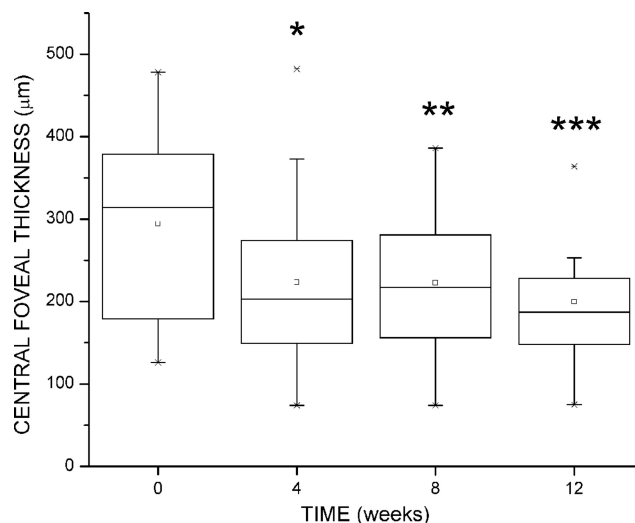


FIGURE 3. Boxplots of central foveal thickness (mean central subfield) at baseline (week 0) and weeks 4, 8, and 12. Details on box plot interpretation are given in Figure 2. Points outside the ends of the whiskers are outliers or suspected outliers. * $P = 0.03$, ** $P = 0.01$, *** $P = 0.005$.

(± 22.24) to 48.82 (± 23.34) nV/deg² ($P = 0.01$) at week 4 and remained significantly increased at week 12 ($P = 0.009$; repeated-measures ANOVA with LSD test; Fig. 4). Particularly, the mean normalized P1 amplitude (i.e., P1 amplitude divided by the amplitude at baseline) for the central ring showed a progressive increase to 1.18 (SE \pm 0.09), 1.65 (SE \pm 0.21), and 1.87 (SE \pm 0.33) at weeks 1, 4, and 12, respectively. No statistically significant changes were detected for the amplitude density of the second and third ring, or for the latency in any ring.

Three linear regression models were built taking into consideration the variables BCVA, mfERG response (P1 amplitude density in the central ring), and CFT observed at baseline, month 1, and month 3. Because of the reduced sample size, we set an a priori threshold of 0.0033 for the significance level (corrected with the Bonferroni formula). mfERG response showed correlation both with VA ($F = 22$, $P = 0.00002$; first model) and CFT ($F = 12.73$, $P = 0.00078$; second model). In

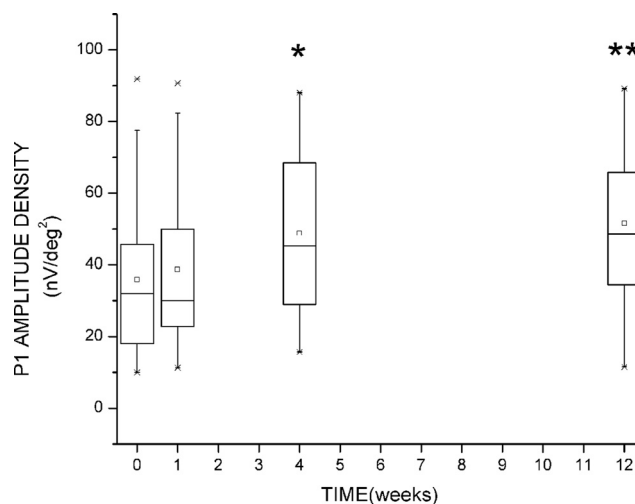


FIGURE 4. Boxplots of P1 amplitude density at baseline (week 0) and weeks 1, 4, and 12. Details on box plot interpretation are given in Figure 2. * $P = 0.01$, ** $P = 0.009$.

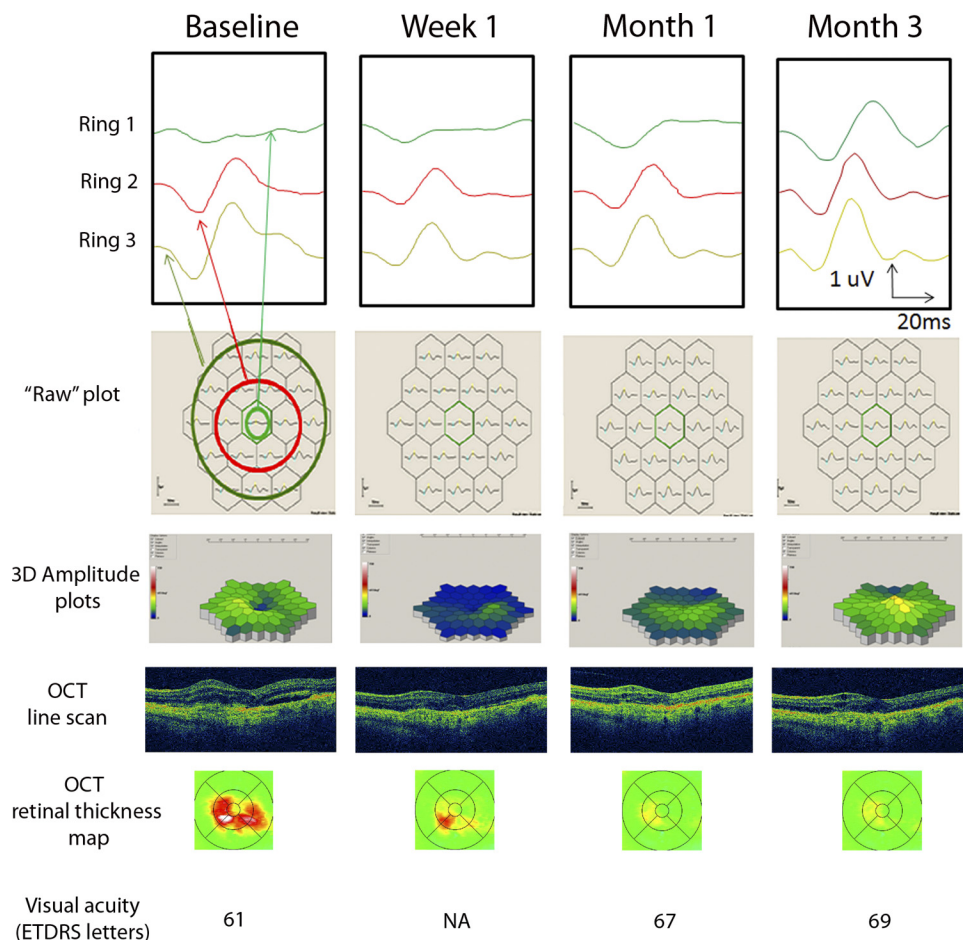


FIGURE 5. Example of the changes in one patient in mfERG response, OCT, and VA, during the course of treatment.

both cases, there was not a strong variation in time ($F = 0.96$, $P = 0.39$ for the first model; $F = 5.9$, $P = 0.02$ for the second model).

No significant correlation was found between VA and CFT ($F = 2.09$, $P = 0.15$; third model). The variation in time was not significant ($F = 4.35$, $P = 0.04$). Pearson's partial correlation coefficients between mfERG and VA were $\rho = 0.61$ with $P = 0.000012$; between mfERG and CFT, $\rho = -0.30$ with $P = 0.027$; between VA and CFT, $\rho = -0.19$ with $P = 0.17$.

An example of the changes in mfERG response, OCT and VA for one patient during the course of treatment is given in Figure 5.

Frequency distribution of changes in BCVA, CFT, and mfERG response between baseline and week 12 for all the study population are shown in Table 2. Responses were grouped into categories taking into consideration the reproducibility of each test and/or the clinical significance of the data.²⁰⁻²² The percentage of patients who did not experience any change was much higher when referring to BCVA (50%) than to CFT (17%) or mfERG (28%). On the other hand, patients with a definitive improvement were more evident when measuring CFT (44%) or mfERG (57%) than BCVA (28%).

One ocular adverse event was recorded: a patient on warfarin had a submacular hemorrhage after the first injection of ranibizumab.

DISCUSSION

Our study shows that mfERG significantly improves in patients with nAMD during the initiation phase of intravitreal ranibizumab treatment. P1 amplitude density of the central ring of

mfERG significantly increased after the first injection and remained stable for the course of three treatments.

We recorded mfERG using a 19-segment stimulus over the central 42° diameter field. This is a deviation from ISCEV guidelines, which recommend a stimulus containing 61 or 103 elements.²³ As already mentioned in the methods, we believe

TABLE 2. Frequency Distribution of Changes in BCVA, CFT, and mfERG between Baseline and Week 12

	Patients, n (%)
BCVA Change, letters	
No change (decrease/increase ≤ 5 letters)	9 (50)
Mild improvement (increase >5 and <15 letters)	4 (22)
Definitive improvement (increase ≥ 15 letters)	5 (28)
CFT Change, μm	
No change (decrease/increase $\leq 10 \mu\text{m}$)	3 (17)
Mild deterioration (increase >10 and $\leq 100 \mu\text{m}$)	3 (17)
Mild improvement (decrease >10 and $\leq 100 \mu\text{m}$)	4 (22)
Definitive improvement (decrease $>100 \mu\text{m}$)	8 (44)
mfERG* Change, Percentage of Baseline Value	
No change (decrease/increase $\leq 25\%$)	5 (28)
Mild deterioration (decrease >25 and $\leq 40\%$)	1 (5)
Definitive deterioration (decrease $>40\%$)	1 (5)
Mild improvement (increase >25 and $\leq 40\%$)	1 (5)
Definitive improvement (increase $>40\%$)	10 (57)

* P1 amplitude density at the central ring.

that this recording protocol ensures that a good-quality trace can be recorded quickly from elderly subjects. Our recording protocol has been validated and its findings support those of others.^{14,24}

The mechanism of visual loss in nAMD is unclear, and the dysfunction of many different retinal cells is probably involved. The standard mfERG is largely shaped by ON and OFF-bipolar cell activity, with smaller contributions from the photoreceptor and inner retinal (e.g., amacrine and ganglion) cells.⁹ The mean increase of mfERG signal we recorded in patients affected by nAMD after intravitreal injection of ranibizumab may suggest that this treatment induces a commensurate recovery in the function of one or more cell populations contributing to the genesis of this signal. However, the improvement in retinal function in our study, as shown in Table 2, was not consistent across all eyes. In five cases, the mfERG response did not change significantly from baseline; one of those patients had a submacular hemorrhage, and two had normal baseline responses limiting the likelihood of improvement. In two there was deterioration compared with baseline. Further studies are needed to find out whether groups of delayed responders and nonresponders can be identified by mfERG.

Our results suggest that, compared with BCVA, mfERG may be more sensitive to improvements in macular function. The proportion of patients with a definitive improvement after a course of three injections of ranibizumab was twice as high when considering the mfERG response compared with BCVA (Table 2).

At least two reasons can explain this discrepancy. First, mfERG measures the function of large retinal areas which in our study were approximately 5.3° (central) and 43.5° (peripheral) in diameter. Visual acuity in contrast only reflects the function of less than 1° of visual angle. The greater area of retina tested by the mfERG may allow the detection of changes also away from the foveal center. Second, the difference in mfERG and BCVA response may be due to the greater complexity of the pathway of the latter including its psychophysical nature.

Significant improvements in the mfERG occurred as early as week 4 and paralleled improvements in the OCT while significant improvements in BCVA only occurred by week 12 (Figs. 2, 3, and 4). These data may suggest once more that mfERG has higher sensitivity than BCVA. However, some caution is needed in interpreting this particular finding because of the reduced protocol VA testing we used at weeks 4 and 8. We observed a median change in refractive spherical equivalent of -0.56 D between baseline and month 3. It has been demonstrated that uncorrected refractive errors as small as 0.50 D may compromise the detection of visual change,²⁵ whereas they usually do not affect the mfERG.²³

We found only a small improvement in CS, which did not reach statistical significance. CS in this study was measured with Pelli-Robson charts, which are low-contrast letter charts testing low spatial frequencies. These charts provide high test-retest reliability,²⁶ but they may not be able to detect fine changes in CS in those patients with a large area of central retina compromised by the growth of the choroidal neovascularization.

Our results are in keeping with studies that have investigated mfERG in eyes receiving intravitreal bevacizumab. A recently reported similar-sized study of patients receiving a PRN bevacizumab treatment regimen showed improvements in mfERG at 1 week, persisting over 6 months of follow-up.¹⁷ Earliest improvement occurred in central rings with improvement extending to peripheral rings in later examinations during the follow-up period. Significant improvements at 2 weeks¹⁶ and 1 month^{15,18} have been reported by previous smaller studies after single doses of bevacizumab. One of

these¹⁵ noted a loss of effect at 3 months after the single injection.

Although the numbers were relatively small, our results suggest that there is no adverse effect on cellular function by ranibizumab as measured by mfERG, at least in the short term, with similar findings for bevacizumab.¹⁵⁻¹⁸ However, Pedersen et al.¹⁷ went on to investigate safety using a full-field ERG and did detect a reduction in response at month 3, going on to speculate that this may indicate some effect on choroidal function, possibly related to drug penetration of the retina. Further studies of anti-VEGF therapies are needed to investigate this finding.

In conclusion, our results suggest that in patients with nAMD, intravitreal ranibizumab therapy is associated with an improvement in the central mfERG. These improvements are paralleled by reductions in OCT thickness and an improvement in VA. mfERG appears to be a useful tool in evaluating the changes in macular function during anti-VEGF therapy. Longer term studies are warranted to determine whether the increase of mfERG response is maintained, the influence of a PRN treatment regimen, and the general prognostic value of mfERG in predicting changes in visual acuity.

References

- Rosenfeld PJ, Brown DM, Heier JS, et al. for the MARINA Study Group. Ranibizumab for neovascular age-related macular degeneration. *N Engl J Med*. 2006;355:1419-1431.
- Brown DM, Kaiser PK, Michels M, et al. ANCHOR Study Group. Ranibizumab versus verteporfin for neovascular age-related macular degeneration. *N Engl J Med*. 2006;355:1432-1444.
- Regillo CD, Brown DM, Abraham P, et al. Randomized, double-masked, sham-controlled trial of ranibizumab for neovascular age-related macular degeneration: PIER Study year 1. *Am J Ophthalmol*. 2008;145:239-248.
- Fung AE, Lalwani GA, Rosenfeld PJ, et al. An optical coherence tomography-guided, variable dosing regimen with intravitreal ranibizumab (Lucentis) for neovascular age-related macular degeneration. *Am J Ophthalmol*. 2007;143:566-583.
- Kumar A, Sahni JN, Stangos AN, Campa C, Harding SP. Effectiveness of ranibizumab for neovascular age-related macular degeneration using clinician-determined retreatment strategy. *Br J Ophthalmol*. 2011;95:530-533.
- Mitchell P, Korobelnik J-F, Lanzetta P, et al. Ranibizumab (Lucentis) in neovascular age-related macular degeneration: evidence from clinical trials. *Br J Ophthalmol*. 2010;94:2-13.
- Sutter EE, Tran D. The field topography of ERG components in man, I: the photopic luminance response. *Vision Res*. 1992;32:433-446.
- Hood DC. Assessing retinal function with the multifocal technique. *Prog Retin Eye Res*. 2000;19(5):607-646.
- Hood DC, Frishman IJ, Saszik S, Viswanathan S. Retinal origins of the primate multifocal ERG: implications for the human response. *Invest Ophthalmol Vis Sci*. 2002;43:1673-1685.
- Jurklics B, Weismann M, Husing J, et al. Monitoring retinal function in neovascular maculopathy using multifocal electroretinography: early and long-term correlation with clinical findings. *Graefes Arch Clin Exp Ophthalmol*. 2002;240:244-264.
- Heinemann-Vernaleken B, Palmowski A, Allgayer R, et al. Comparison of different high resolution multifocal electroretinogram recordings in patients with age-related maculopathy. *Graefes Arch Clin Exp Ophthalmol*. 2001;239:556-561.
- Huang S, Wu D, Jiang F, et al. The multifocal electroretinogram in age-related maculopathies. *Doc Ophthalmol*. 2001;101:115-124.
- Ruther K, Breidenbach K, Schwartz R, et al. Testing central retinal function with multifocal electroretinography before and after photodynamic therapy (in German). *Ophthalmologie*. 2003;100:459-464.
- Mackay AM, Brown MC, Hagan RP, Fisher AC, Grierson I, Harding SP. Deficits in the electroretinogram in neovascular age-related macular degeneration and changes during photodynamic therapy. *Doc Ophthalmol*. 2007;115:69-76.

15. Moschos M, Brouzas D, Apostolopoulos M, Koutsandrea C, Loukianou E, Moschos M. Intravitreal use of bevacizumab (Avastin) for choroidal neovascularization due to ARMD: a preliminary multifocal-ERG and OCT study: multifocal-ERG after use of bevacizumab in ARMD. *Doc Ophthalmol.* 2007;114:37-44.
16. Karanjia R, Eng KT, Gale J, Sharma S, ten Hove MW. Electrophysiological effects of intravitreal Avastin (bevacizumab) in the treatment of exudative age-related macular degeneration. *Br J Ophthalmol.* 2008;92:1248-1252.
17. Pedersen KB, Møller F, Sjølie AK, Andréasson S. Electrophysiological assessment of retinal function during 6 months of bevacizumab treatment in neovascular age-related macular degeneration. *Retina.* 2010;30:1025-1033.
18. Manzano RP, Peyman GA, Khan P, Kivilcim M. Testing intravitreal toxicity of bevacizumab (Avastin). *Retina.* 2006;26:257-261.
19. Feigl B, Greaves A, Brown B. Functional outcomes after multiple treatments with ranibizumab in neovascular age-related macular degeneration beyond visual acuity. *Clin Ophthalmol.* 2007;1:167-175.
20. Ardit A, Cagenello R. On the statistical reliability of letter-chart visual acuity measurements. *Invest Ophthalmol Vis Sci.* 1993;34:120-129.
21. Ho J, Sull AC, Vuong LN, et al. Assessment of artifacts and reproducibility across spectral- and time-domain optical coherence tomography devices. *Ophthalmology.* 2009;116:1960-1970.
22. Harrison WW, Bearse MA Jr, Ng JS, Barez S, Schneck ME, Adams AJ. Reproducibility of the mfERG between instruments. *Doc Ophthalmol.* 2009;119:67-78.
23. Hood DC, Bach M, Brigell M, et al. ISCEV guidelines for clinical multifocal electroretinography (2007 edition). *Doc Ophthalmol.* 2008;116:1-11.
24. Hagan RP, Fisher AC, Brown MC. Examination of short binary sequences for mfERG recording. *Doc Ophthalmol.* 2006;113:21-27.
25. Rosser DA, Murdoch IE, Cousens SN. The effect of optical defocus on the test-retest variability of visual acuity measurements. *Invest Ophthalmol Vis Sci.* 2004;45:1076-1079.
26. Elliott DB, Sanderson K, Conkey A. The reliability of the Pelli-Robson contrast sensitivity chart. *Ophthalmic Physiol Opt.* 1990;10:21-24.