

Reinnervation of Primate Ciliary Muscle Following Ciliary Ganglionectomy

Kristine A. Erickson-Lamy* and Paul L. Kaufman†

Ciliary ganglionectomy and/or postganglionic ciliary neurectomy in the cynomolgus monkey was followed by supersensitivity to intramuscular (i.m.) pilocarpine and lack of response to topical eserine and to electrical stimulation of the Edinger-Westphal nucleus. Normal responsiveness to pilocarpine and eserine returned in most instances after about 6 months. An accommodative response to stimulus of the Edinger-Westphal nucleus was also present and, as in control eyes, could be blocked by hexamethonium. Collectively, these findings demonstrate that (1) parasympathetic innervation to the ciliary muscle mediating accommodation traverses a typical peripheral autonomic synapse, almost certainly located predominantly in the ciliary ganglion; (2) by 6 months after denervation, the ciliary muscles have reinnervated; and (3) the parasympathetic pathway to the eye exhibits plasticity and capacity for regeneration. Invest Ophthalmol Vis Sci 28:927-933, 1987

Several studies have described agonist-induced subsensitivity of the primate accommodative mechanism to cholinergic drugs, presumably due to decreased responsiveness of the ciliary muscle.¹⁻⁶ However, there have been no reports on the development of denervation supersensitivity in the ciliary muscle. Such studies might be important for several reasons. First, they might clarify the role of the parasympathetic nervous system in normal ocular physiology and in the pathophysiology of abnormal conditions such as Adie's syndrome, which is characterized by mydriasis, deficient pupillary light reflexes, tonic iridal contraction during accommodation, and accommodative disturbances⁷⁻⁹ and is thought to be caused by postsynaptic denervation of the cholinergic pathway. Second, the ciliary and iris sphincter muscles are unique among parasympathetically-innervated smooth muscles because the peripheral ganglion (in this case the ciliary ganglion) is anatomically discrete and located at some distance from the muscle, and therefore can be relatively easily excised. Ciliary muscle denervation could thus provide a model for parasympathetic denervation of primate smooth

muscle systems in general. Finally, a parasympathetically denervated anterior segment would provide an excellent system for assessing the role (if any) of the parasympathetic nervous system in echothiophate-induced cataractogenesis¹⁰⁻¹³ and structural alterations in the trabecular meshwork and ciliary body.¹⁴⁻¹⁵

We report here the acute effects of ciliary ganglionectomy on accommodation induced by cholinomimetic drugs and by electrical stimulation of the Edinger-Westphal nucleus in the cynomolgus monkey eye. We also present pharmacologic and electrophysiologic evidence for reinnervation of the ciliary muscle via a conventional pathway.

Materials and Methods

Animals and Eyes

Twenty-seven young adult cynomolgus monkeys (*Macaca fascicularis*) of both sexes underwent unilateral ciliary ganglionectomy via a lateral orbitotomy approach as follows: the monkeys were anesthetized with i.m. methohexital sodium, 15 mg/kg, followed by i.m. pentobarbital sodium, 30-35 mg/kg, warmed by heating pads, and shaved about the head and face. Conditions were clean but not sterile. Unilateral orbitotomy and isolation of the ciliary ganglion was performed as previously described.¹⁶ The ganglion and its attached posterior ciliary nerve trunks were drawn anteriorly and the nerve trunks cut, so that the ganglion and the proximal 1 cm of the nerve trunks were removed *en bloc*. In some smaller orbits, where the exposure was suboptimal, only the nerve trunks and the distal portion of the ganglion were

From the *Howe Laboratory of Ophthalmology, Massachusetts Eye and Ear Infirmary, Harvard Medical School, Boston, Massachusetts, and the †Department of Ophthalmology, University of Wisconsin Medical School, Madison, Wisconsin.

Supported by grants EY-02698 and EY-04146 from the National Eye Institute, National Institutes of Health, Bethesda, Maryland; and the National Glaucoma Research Fund, a program of the American Health Assistance Foundation.

Submitted for publication: August 18, 1986.

Reprint requests: Kristine Erickson-Lamy, PhD, Howe Laboratory of Ophthalmology, Massachusetts Eye and Ear Infirmary, 243 Charles Street, Boston, MA 02114.

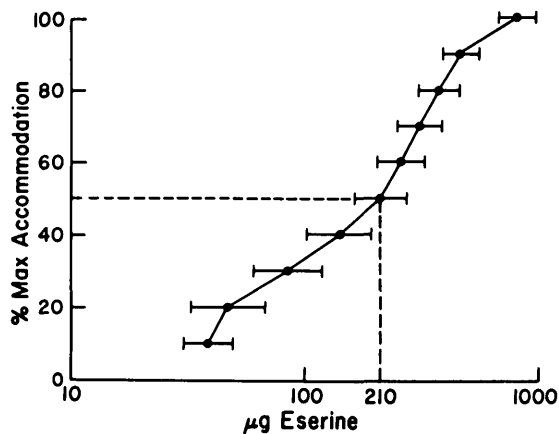


Fig. 1. Geometric mean topical eserine sulfate dose-accommodation response relationship in nine normal cynomolgi. Standard errors of the geometric mean doses required for 10–100% maximal responses are shown by horizontal bars. The dotted lines indicate the dose required for a half-maximal response.

excised, leaving the proximal portion of the ganglion attached to the oculomotor nerve.

In most cases, the opposite eye served as a surgically untouched paired control. In a few cases, the opposite side had undergone lateral orbitotomy with dissection but not removal of the ciliary ganglion or the short ciliary nerves at least 6 months previously. The lateral orbitotomy procedure has no apparent long-term effects on accommodative responses to cholinergic drugs¹⁷; these eyes, therefore, also serve as paired controls.

Fourteen of these 27 animals were followed for 6 or more months after ganglionectomy. The remaining 13 animals were sacrificed 1 week or 1 month after ganglionectomy and the ocular tissues were used in related studies.

Refraction and Accommodation to Cholinergic Drugs

Baseline refractions and accommodation measurements were made using a Hartinger coincidence refractometer (Zeiss-Jena, Jena, German Democratic Republic) coupled to a strip chart recorder.¹⁷

Topical eserine sulfate (ES) was administered to the central cornea as five 2 μ l drops of 50% solution (500 μ g) at 30-second intervals with blinking prevented between drops.¹⁷ This dose is near maximal in the normal cynomolgus monkey eye. (Fig. 1) Each eye was then refracted every 10–15 min for 60–90 min, the time required to reach a stable myopia in innervated eyes. Maximum myopia was taken as the mean of at least two successive readings on this plateau.

Deep i.m. injections of pilocarpine hydrochloride (PILO) solution were given in the thigh. Each eye was then refracted every 4–8 min until a stable myopia

was reached and began to fade. Maximum myopia was taken as the mean of at least two successive determinations on this plateau. Each animal received sequential PILO doses of 0.5 and 2.5 mg/kg during one experimental session. The second dose was not given until the effect of the previous dose began to fade (generally 30–40 min separated the doses). The previous dose was ignored when calculating the effects of the subsequent dose, ie, the second dose was considered to be 2.5 mg/kg rather than 3.0 mg/kg. These doses are approximately half maximal and maximal in normal cynomolgi.³

Hexamethonium bromide (HEX), 15 mg/kg was given as a bolus i.m. injection in the thigh in some experiments in which accommodation was induced by electrical stimulation of the Edinger-Westphal nucleus. This dose blocks electrically stimulated accommodation in normal cynomolgi (unpublished data, Kristine Erickson-Lamy, Ph.D.) and has little or no effect on accommodation induced by direct acting muscarinic agonists such as pilocarpine.³

Central Electrical Stimulation of Accommodation

A stainless steel or platinum bipolar electrode (3.5–4 cm; outer diameter 0.6 mm) was stereotaxically implanted into the Edinger-Westphal nucleus as described previously.¹⁸ Monophasic 0.5 msec duration pulses were delivered to the implanted electrode using an Anapulse stimulator (Model 302-T, WPI Instruments, New Haven, CT) with an Anapulse isolation transformer. Accommodative responses to 1 V increments from 0 to 20 V at fixed frequency (100 Hz) and to 10 Hz increments from 0 to 100 Hz at fixed voltage (usually 10 V) were measured with the refractometer until maximum accommodation was reached.

Anesthesia

Anesthesia for electrode implantations was induced by i.m. ketamine, after which the animal was intubated and maintained with a mixture of halothane (1–1.5%), nitrous oxide (30–40%) and oxygen (40%). All other procedures were conducted under methohexital sodium (15 mg/kg) followed by pentobarbital sodium (35 mg/kg).

These investigations conform to the ARVO Resolution on the Use of Animals in Research.

Results

Histological Verification of Ciliary Ganglionectomy

Light microscopy of the excised tissue from several monkeys invariably demonstrated the presence of the ciliary ganglion and the posterior ciliary nerves (Fig. 2).

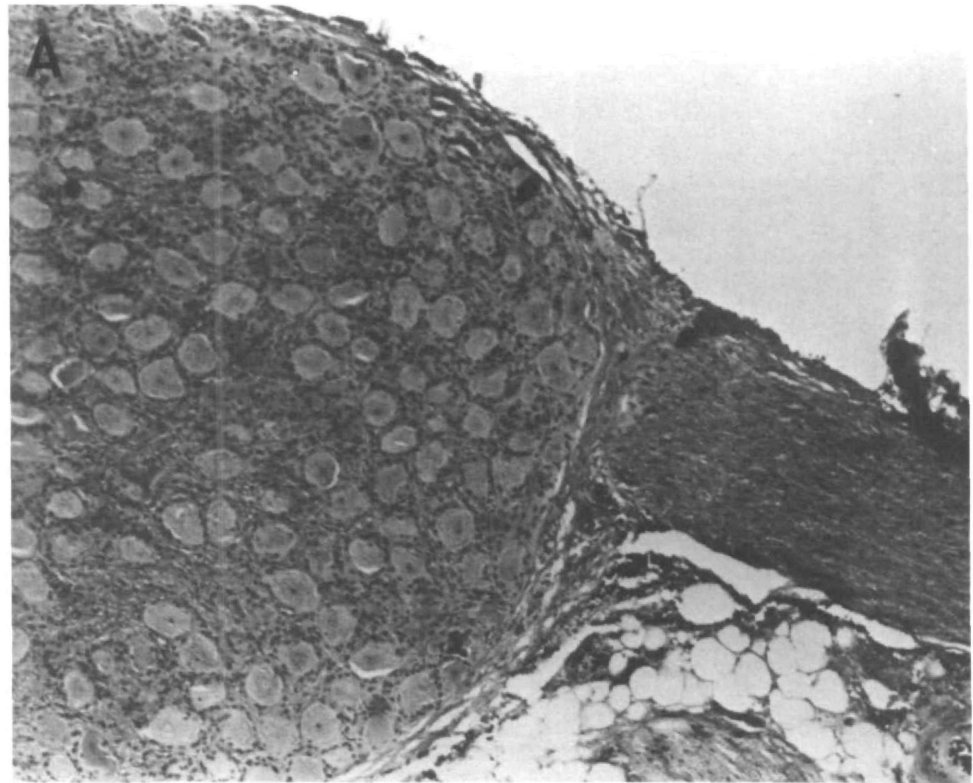


Fig. 2. Excised ciliary ganglionectomy specimen. **(A)** Ganglion with parasympathetic motor neuron cell bodies and posterior ciliary nerve trunk leaving ganglion at right. **(B)** Typical neurons within ganglion Hematoxylin and eosin (**A** $\times 77.6$, **B** $\times 388$).

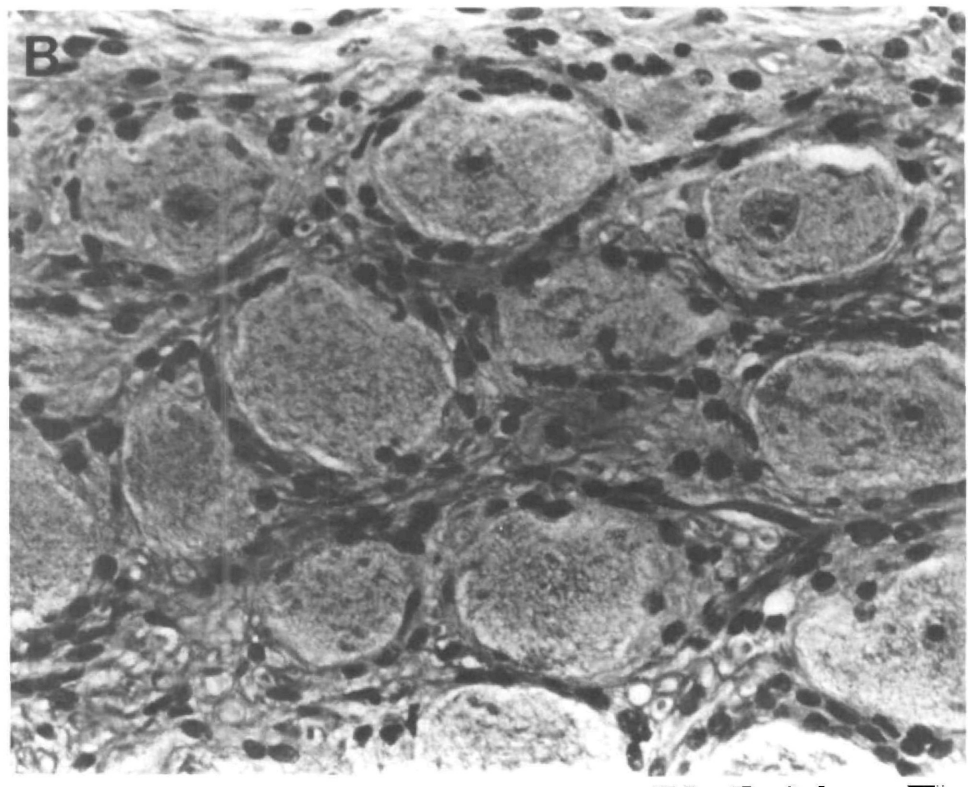


Table 1. Resting refractions of denervated and fellow control eyes of cynomolgus monkeys

Weeks after surgery	N	Denervated	Control	D-C
Presurgery	16	-2.63 ± 0.54	-2.23 ± 0.39	-0.40 ± 0.38
1	15	-3.80 ± 0.85	-2.39 ± 0.37	-1.41 ± 0.78*
4	11	-1.59 ± 0.89	-1.16 ± 0.78	-0.43 ± 0.68
12	7	-2.09 ± 0.96	-1.59 ± 0.28	-0.50 ± 0.96
24	10	-2.43 ± 0.47	-2.77 ± 0.57	+0.34 ± 0.47
52	6	-2.27 ± 0.80	-2.21 ± 0.52	-0.06 ± 0.84
104	5	-0.15 ± 0.44	-0.91 ± 0.60	+0.75 ± 0.52

Data are mean ± SEM diopters for N animals. D = denervated eye, C = control eye significantly different from 0 by the two-tailed pair t-test.
* $P < 0.10$.

Resting Refractions

There was no significant difference in the resting refractions of contralateral eyes and to-be-ganglionectomized eyes prior to surgery. After ganglionectomy, denervated eyes were very slightly more myopic than the control eyes, but this difference had disappeared by 1 month after surgery (Table 1).

Pharmacologically-induced Accommodation

Denervated eyes were supersensitive to i.m. PILO when first tested as early as 1 week after denervation. After 1 month denervated eyes continued to be su-

persensitive to PILO and were nonresponsive to topical ES. By 3 months, denervated eyes were indistinguishable from their fellow control eyes in their accommodative responses to both PILO and to ES (Fig. 3).

There were three animals (monkeys 50, 123, and 125, indicated in Figure 3) in this group who did not regain accommodative responsiveness to ES in the denervated eye. Their responsiveness to ES remained at less than 20% of the control eye 6 months or even more than 1 year (monkey 50) after denervation. Monkey 123 also remained supersensitive to i.m. and topical PILO, while monkey 125 was never supersensitive to either i.m. or topical PILO.¹⁹ Monkey 123 also received an electrode implant about one year after denervation; the contralateral control eye accommodated 11 diopters to stimulation, while there was no response at all in the denervated eye.

Electrically-Induced Accommodation

One month after ganglionectomy, several monkeys underwent placement of a permanent bipolar electrode into the Edinger-Westphal nucleus. Normal contralateral eyes exhibited a voltage-dependent accommodative response to 1 V increments at a fixed frequency (100 Hz) or 10 Hz increments at fixed volt-

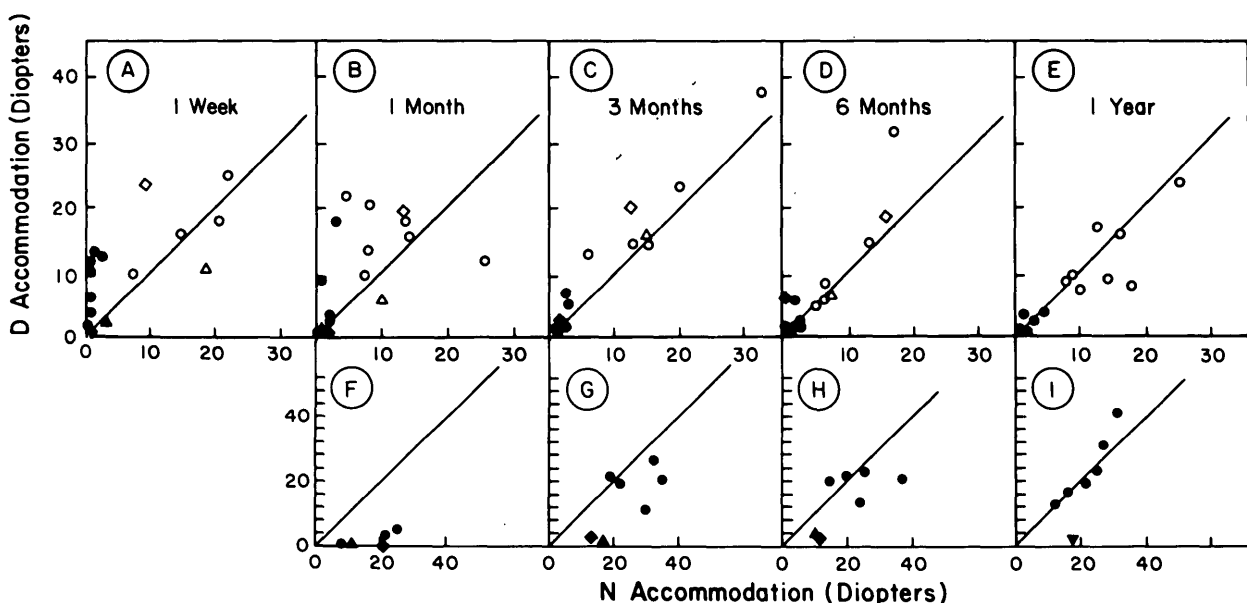


Fig. 3. Pharmacologically-induced accommodation at various times after unilateral ciliary ganglionectomy/posterior ciliary neurectomy. Accommodative responses to i.m. PILO and topical ES were measured bilaterally 1 week (●, ○ PILO only), 1 month (●, ○), 3 months (●, ○), 6 months (●, ○) and 1 year (●, ○) after surgery. Ordinate represents accommodation in denervated (D) eye, abscissa in contralateral normal (N) eye of same animal; 45° line = no difference. In ●-○ solid symbols = i.m. PILO 0.5 mg/kg, open symbols = i.m. PILO 2.5 mg/kg. In ●-○, solid symbols = topical ES 500 μg. ▼ = monkey 50 (ES only); ◆ = monkey 123 (PILO and ES); ▲ = monkey 125 (PILO and ES). As a group, denervated eyes were initially supersensitive to PILO (●, ○); (supersensitivity usually more apparent with the smaller PILO dose, since the larger dose was near-maximal even for normosensitive eyes) and nonresponsive to ES (●), after which they became more normally responsive to both PILO (○) and ES (○). Six months or more after denervation, responses to both PILO (○, ○) and ES (○, ○) were approximately the same in D and N eyes.

age (10–20 V; not shown). Substantial accommodation (10–20 diopters) to a maximum stimulus was obtained in the normal eyes, while the fellow denervated eyes showed no response to greater than maximal stimuli (Fig. 4).

At least 6 months after denervation, four animals underwent electrode implantation (Table 2). In three animals (#50 excepted) both normal and denervated eyes responded in a voltage-dependent way to graduated electrical stimulation. These animals accommodated significantly in the denervated eye to topical ES. Pretreatment with HEX blocked the responses to stimulation at all voltage levels in both the normal and the reinnervated eyes.

Monkey 50 was different from most long-term animals. More than 2 years after denervation, this animal showed no accommodative response to electrical stimulation and very little to topical ES (Table 2). Stimulation data from this animal are also shown in Figure 4 (D–L, N–L); accommodative responses were indistinguishable from functionally denervated short-term animals.

Discussion

A number of studies have investigated the effects of ciliary ganglionectomy on the miotic response of the cat iris sphincter to light and to cholinergic drugs.^{20–24} These studies have shown that supersensitivity to acetylcholine (ACh)²⁴ and to PILO²¹ developed as early as 24 hr after ganglionectomy and that maximum sensitivity occurred after 5–8 days.^{20,22} A 10- to 20-fold increase in sensitivity to topical PILO or carbachol was observed 5–7 weeks after denervation.²³ Supersensitivity to PILO started to decline as soon as 35 days after ganglionectomy and normal sensitivity was restored after 200 days.²¹ Denervated iris sphincters were unresponsive to topical ES²⁴ and topical diisopropylfluorophosphate²³ one month after denervation. Responsiveness to ES began to return at around 1–5 months after surgery, depending on the extent of the denervation.²³

We observed analogous phenomena in the denervated primate ciliary muscle. Supersensitivity to i.m. and topical^{19,25} PILO was evident 1 week and 1 month respectively after denervation, started to decrease by 3 months, and normal sensitivity was restored after 6 months to 1 year. The accommodative response to ES was absent at 1 month and had returned to nearly normal levels 6 months after denervation. The response to ES at a particular time point was predictive of the response to central stimulation. One month after denervation, when the ES responses in the denervated eyes were at most 20% of those in the contralateral control eyes, there was no response

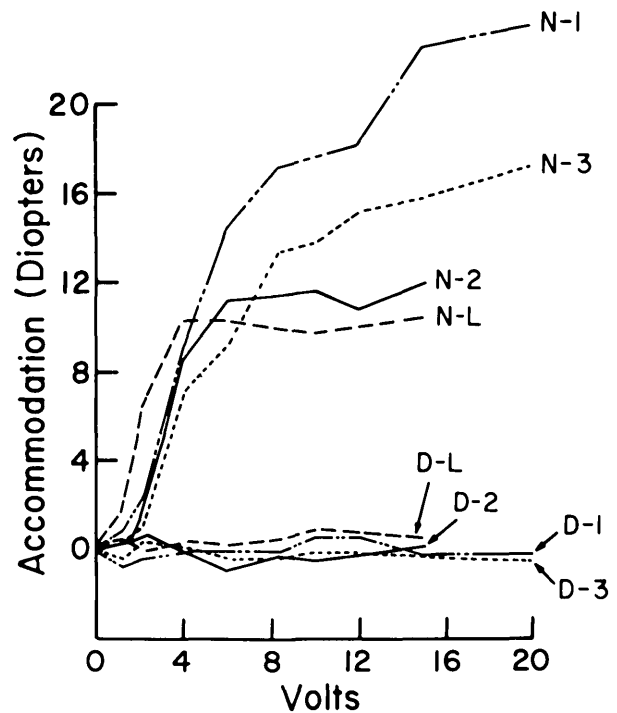


Fig. 4. Central stimulation of accommodation following unilateral ciliary ganglionectomy/postganglionic ciliary neurectomy. D1–3, N1–3 are denervated and control eyes respectively of three monkeys 1 month after unilateral denervation surgery. D–L, N–L are denervated and control eye of monkey #50, 2+ years after surgery. Data are accommodative responses to 1 V increments (100 Hz, 0.5 msec pulses) delivered to an electrode permanently placed in the Edinger-Westphal nucleus.

to electrical stimulation. After 6 months, when the denervated eyes' responses to ES were 80–100% that of the control eyes, the response to electrical stimulation had also returned and could be blocked by HEX.

Table 2. Central stimulation and topical eserine-induced accommodation approximately 6 months (21–32 weeks) or more after denervation

Monkey no.	Central stimulation				Eserine	
	(-HEX)		(+HEX)		D	N
50	0.5	10.2	—	—	3.2	16.8
67	8.1	9.1	0.8	0.1	12.5	12.4
104	9.8	12.8	0.3	0.3	31.3	41.6
128	6.3	13.8	0.5	0.03	18.7	21.0

Accommodative responses to stimulation were measured initially without hexamethonium Br (-HEX), according to Materials and Methods. Hexamethonium was then administered i.m. (15 mg/kg) and accommodation was again measured 30 min later (+HEX). Data are diopters of accommodation induced by a maximal (10–20 V, 100 Hz, 0.5 msec pulse) stimulus in each animal. On another occasion, the accommodative response to a near-maximal dose of topical eserine sulfate (500 µg) was measured. Baseline refractions of fellow eyes were comparable on both occasions.

Collectively, the findings indicate that denervation and subsequent reinnervation of the ciliary and iris sphincter muscles occur after ciliary ganglionectomy and/or postganglionic ciliary neurectomy and that the reinnervation involves re-establishment of a "ganglionic-type synapse."

There is still disagreement as to whether parasympathetic fibers subserving accommodation necessarily synapse at all between the brain and the ciliary muscle,^{26,27} and whether some accommodation-subserving parasympathetic fibers other than the ciliary ganglion synapse at locations within the orbit.²⁸ The present finding that centrally-induced accommodation in *control* eyes is blocked by HEX indicates that even if some parasympathetic fibers to the ciliary muscle normally pass uninterrupted through the ciliary ganglion, they are relatively insignificant in subserving accommodation. Furthermore, our finding that central stimulation-induced accommodation in reinnervated eyes was also blocked by HEX argues against a reinnervation of the ciliary muscle by pre-synaptic third nerve fibers. Our finding that the ciliary muscle reinnervates so readily and that centrally-induced accommodation in the *reinnervated* eyes can also be blocked by HEX supports the hypothesis that relevant neurons and/or cell bodies still remain in the orbit after removal of the ciliary ganglion and accessory ganglia in the posterior ciliary nerves. Since visualization and instrumentation proximal to the ganglion are not ideal in the narrow, crowded orbital apex of these small monkeys, it is quite possible that some cell bodies (and/or axons) proximal to the main mass of the ganglion were not excised. The ciliary muscle's and and/or degenerating axons' "call for nerves" could thus most readily be answered by collateral sprouting from any remaining postganglionic axons and/or cell body-mediated regeneration of axons.

A third possibility is that peripheral neurons not normally subserving accommodation could be "called in" to reinnervate the ciliary muscle, subsequently taking up the function of accommodation. The presence of accommodation during central stimulation in reinnervated eyes, however, suggests that any foreign reinnervation that did occur was probably accompanied by a functional central or peripheral reorganization, such that the putative foreign fibers were placed under the control of the Edinger-Westphal nucleus. It is not impossible that such reorganization could occur since cross-innervation is known to occur both peripherally^{29,30} and centrally,²⁹ resulting in some cases in functional end organ synapses.²⁹ Our surgical procedure unquestionably interrupted sensory fibers, and presumably interrupted sympathetic and perhaps other fibers in addition to para-

sympathetics. In the cat, however, reinnervation of the iris sphincter after ciliary ganglionectomy was not prevented by removal of the superior cervical ganglion, ruling out the possibility of outgrowth of fibers from the sympathetics as a source of reinnervation in that system.²⁴ Another possible candidate for mediating foreign reinnervation is the facial nerve, which carries parasympathetic vasodilatory fibers, putatively utilizing both ACh and vasoactive intestinal peptide (VIP) as transmitters to the anterior and posterior uveal blood vessels.³¹

Three of 14 animals followed for 3 or more months never evidenced reinnervation by pharmacologic or central stimulation criteria. Two (# 123, 125) were followed for over 1 year. The third monkey, #50, remained unresponsive to central stimulation and topical ES more than 2 years after denervation; at that time, its ciliary muscle contained essentially no choline acetyltransferase activity,²⁵ indicating virtual absence of cholinergic nerve terminals.

The reason for the lack of reinnervation in these particular animals is unknown. All three underwent ciliary ganglionectomy and extensive postganglionic ciliary neurectomy. Of the 11 long-term animals that did reinnervate, 7 underwent both ganglionectomy and neurectomy similar to the non-reinnervating animals; the remaining 4 received post-ganglionic neurectomy and distal subtotal ciliary ganglionectomy. Therefore, the clinically apparent extent of the surgical procedure alone did not seem to determine reinnervation.

All of the denervated eyes showed a maximum accommodative response to PILO comparable to their fellow control eyes at all time points. This does not necessarily indicate that the ciliary muscle itself was fully functional, since the accommodative apparatus could be a "spare contraction" system.¹ Armaly found partial degeneration of the muscle by light microscopy 1 or more years after ciliary ganglionectomy in this monkey species and in rhesus, but reported no physiological data.³² The morphology of our eyes is under study, but in any event, Armaly's morphological findings and our physiological ones are not incompatible.

Ciliary ganglionectomized monkey eyes may prove useful in studying the pathophysiology of parasympathetic denervation and reinnervation in both ocular and non-ocular smooth muscle, and in delineating mechanisms of cholinergic drug-induced ocular toxicity.

Key words: Accommodation, ciliary ganglionectomy, ciliary muscle, denervation, Edinger-Westphal nucleus, eserine, *Macaca fascicularis*, parasympathetic, parasympathetic reinnervation, pilocarpine, supersensitivity

Acknowledgments

The authors thank Drs. Elke Lütjen-Drecoll and Ingolf H. L. Wallow for histological examination of the excised neural tissue, Dr. Carl K. Buckner for valuable critique, the Wisconsin Regional Primate Research Center (supported by NIH grant RR-00167) for facilities and aid of staff, B'Ann True, Kathryn Crawford, and Patrick Goeckner for their excellent technical assistance, and Margery Brothers for her patient typing of the manuscript.

References

- Kaufman PL and Bárány EH: Subsensivity to pilocarpine in primate ciliary muscle following topical anticholinesterase treatment. *Invest Ophthalmol* 14:302, 1975.
- Bárány EH: Pilocarpine-induced subsensitivity to carbachol and pilocarpine of ciliary muscle in vervet and cynomolgus monkeys. *Acta Ophthalmol* 55:141, 1977.
- Kaufman PL: Anticholinesterase-induced cholinergic subsensitivity in primate accommodative mechanism. *Am J Ophthalmol* 85:622, 1978.
- Bárány E, Berrie CP, Birdsall NJM, Burgen ASV, and Hulme EC: The binding properties of the muscarinic receptors of the cynomolgus monkey ciliary body and the response to the induction of agonist subsensitivity. *Br J Pharmacol* 177:731, 1982.
- Bárány EH: Muscarinic subsensitivity without receptor change in monkey ciliary muscle. *Br J Pharmacol* 84:193, 1985.
- Erickson-Lamy KA, Polansky JR, Kaufman PL, and Zlock DL: Cholinergic drugs alter ciliary muscle response and receptor content. *Invest Ophthalmol Vis Sci* 28:375, 1987.
- Lowenfeld IE and Thompson HS: The tonic pupil: A re-evaluation. *Am J Ophthalmol* 63:46, 1967.
- Bourgon P, Pilley SF, and Thompson HS: Cholinergic supersensitivity of the iris sphincter in Adie's tonic pupil. *Am J Ophthalmol* 85:373, 1978.
- Bell RA and Thompson HS: Ciliary muscle dysfunction in Adie's syndrome. *Arch Ophthalmol* 96:638, 1978.
- Kaufman PL and Axelsson U: Induction of subcapsular cataracts in aniridic vervet monkeys by echothiophate. *Invest Ophthalmol* 14:863, 1975.
- Kaufman PL, Axelsson U, and Bárány EH: Induction of subcapsular cataracts in cynomolgus monkeys by echothiophate. *Arch Ophthalmol* 95:499, 1977.
- Kaufman PL, Axelsson U, and Bárány EH: Atropine inhibition of echothiophate cataractogenesis in monkeys. *Arch Ophthalmol* 95:1262, 1977.
- Kaufman P, Erickson KA, and Neider MW: Echothiophate iodide cataracts in monkeys: Occurrence despite loss of accommodation induced by retrodisplacement of ciliary muscle. *Arch Ophthalmol* 101:125, 1983.
- Lütjen-Drecoll E and Kaufman PL: Echothiophate-induced structural alterations in the anterior chamber angle of the cynomolgus monkey. *Invest Ophthalmol Vis Sci* 18:918, 1979.
- Lütjen-Drecoll E and Kaufman PL: Biomechanics of echothiophate-induced anatomic changes in monkey aqueous outflow system. *Graefes Arch Clin Exp Ophthalmol*. In press.
- Gonnering RS, Dortzbach RK, Erickson KA, and Kaufman PL: The cynomolgus monkey as a model for orbital research. II. Anatomic effects of lateral orbitotomy. *Curr Eye Res* 3:541, 1984.
- Erickson KA, Gonnering RS, Kaufman PL, and Dortzbach RK: The cynomolgus monkey as a model for orbital research. III. Effects on ocular physiology of lateral orbitotomy and isolation of the ciliary ganglion. *Curr Eye Res* 3:557, 1984.
- Neider MW, Crawford K, True B, and Kaufman PL: Functional studies of accommodation and presbyopia in rhesus monkeys. *ARVO Abstracts. Invest Ophthalmol Vis Sci* 27(Suppl):81, 1986.
- Erickson-Lamy KA, Polansky JR, Kaufman PL, and True B: Dissociation of ciliary muscle cholinergic sensitivity and muscarinic receptor content following ciliary ganglionectomy in cynomolgus monkeys. *ARVO Abstracts. Invest Ophthalmol Vis Sci* 26(Suppl):234, 1985.
- Shen SC and Cannon WB: Sensitization of the denervated pupillary sphincter to acetylcholine. *Chin J Physiol* 10:359, 1936.
- Neidle EA: Pilocarpine sensitization in the parasympathetically denervated pupil of the cat. *Am J Physiol* 160:467, 1950.
- Keil FC and Root WS: Parasympathetic sensitization in the cats' eye. *Am J Physiol* 132:437, 1941.
- Bito LS and Dawson MJ: The site and mechanism of the control of cholinergic sensitivity. *J Pharmacol Exp Ther* 175:673, 1970.
- Anderson HK: The paralysis of involuntary muscle. Part III. On the action of pilocarpine, physostigmine and atropine upon the paralyzed iris. *J Physiol* 33:414, 1905.
- Erickson-Lamy KA and Kaufman PL: Cholinergic reinnervation of the ciliary muscle following ciliary ganglionectomy in the cynomolgus monkey. *ARVO Abstracts. Invest Ophthalmol Vis Sci* 27(Suppl):288, 1986.
- Westheimer G and Blair SM: The parasympathetic pathways to the internal eye muscles. *Invest Ophthalmol* 12:193, 1973.
- Ruskell GL and Griffiths T: Peripheral nerve pathway to the ciliary muscle. *Exp Eye Res* 28:277, 1979.
- Bryson JM, Wolter JR, and O'Keefe NT: Ganglion cells in the human ciliary body. *Arch Ophthalmol* 85:51, 1966.
- Bjorklund A and Stenevi U: Regeneration of monoaminergic and cholinergic neurons in the mammalian central nervous system. *Pharm Rev* 59:62, 1979.
- Brown MC and Hopkins WG: Role of degenerating axon pathways in regeneration of mouse soleus motor axons. *J Physiol* 318:365, 1981.
- Nilsson SFE, Linder J, and Bill A: Characteristics of uveal vasodilation produced by facial nerve stimulation in monkeys, cats, and rabbits. *Exp Eye Res* 40:841, 1985.
- Armary MF: Degeneration of ciliary muscle and iris sphincter following resection of the ciliary ganglion. *Trans Am Ophthalmol Soc* 66:475, 1968.