

# Intraocular Vascular Endothelial Growth Factor Levels in Pachychoroid Neovascularopathy and Neovascular Age-Related Macular Degeneration

Masayuki Hata,<sup>1</sup> Kenji Yamashiro,<sup>1</sup> Sotaro Ooto,<sup>1</sup> Akio Oishi,<sup>1</sup> Hiroshi Tamura,<sup>1</sup> Manabu Miyata,<sup>1</sup> Naoko Ueda-Arakawa,<sup>1</sup> Ayako Takahashi,<sup>1</sup> Akitaka Tsujikawa,<sup>2</sup> and Nagahisa Yoshimura<sup>1</sup>

<sup>1</sup>Department of Ophthalmology and Visual Sciences, Kyoto University Graduate School of Medicine, Kyoto, Japan

<sup>2</sup>Department of Ophthalmology, Kagawa University Faculty of Medicine, Miki, Japan

Correspondence: Masayuki Hata, Department of Ophthalmology and Visual Sciences, Kyoto University Graduate School of Medicine, 54 Kawahara, Shogoin, Sakyo, Kyoto 606-8507, Japan; trj74h6@kuhp.kyoto-u.ac.jp.

Submitted: October 22, 2016

Accepted: December 16, 2016

Citation: Hata M, Yamashiro K, Ooto S, et al. Intraocular vascular endothelial growth factor levels in pachychoroid neovascularopathy and neovascular age-related macular degeneration. *Invest Ophthalmol Vis Sci.* 2017;58:292-298. DOI:10.1167/iovs.16-20967

**PURPOSE.** To investigate the difference in intraocular vascular endothelial growth factor (VEGF) concentration between pachychoroid neovascularopathy and neovascular age-related macular degeneration (nAMD) and its associations with responses to three monthly anti-VEGF injections as an initial treatment for the two conditions.

**METHODS.** This study included nine eyes with treatment-naïve pachychoroid neovascularopathy and 21 eyes with treatment-naïve nAMD. Before the initial intravitreal anti-VEGF injection, aqueous humor samples were collected and the concentration of VEGF was measured using enzyme-linked immunosorbent assay. The concentration was compared between the two conditions, and its associations with responses to anti-VEGF therapy were investigated.

**RESULTS.** The mean VEGF concentration in pachychoroid neovascularopathy was significantly lower than that in nAMD ( $63.4 \pm 17.8$  pg/ml and  $89.8 \pm 45.0$  pg/ml, respectively;  $P = 0.035$ ). The VEGF concentration was associated with the presence or absence of drusen ( $\beta = 0.503$ ,  $P = 0.004$ ). After anti-VEGF therapy, 6 (66.7%) of 9 eyes with pachychoroid neovascularopathy and 17 (81.0%) of 21 eyes with nAMD achieved dry macula ( $P = 0.640$ ). Dry macula at 3 months and 12 months was significantly associated with a low VEGF concentration in pachychoroid neovascularopathy ( $P = 0.013$  and  $P = 0.042$ , respectively), but not in nAMD ( $P = 0.108$  and  $P = 0.219$ ).

**CONCLUSIONS.** The mean VEGF concentration in pachychoroid neovascularopathy was lower than that in nAMD, suggesting that the way in which VEGF is involved in angiogenesis may differ between pachychoroid neovascularopathy and nAMD.

**Keywords:** pachychoroid neovascularopathy, neovascular age-related macular degeneration, vascular endothelial growth factor

Pachychoroid refers to the choroidal anatomical manifestations, including an increase in choroidal thickness or dilation of the outer choroidal vessels, so-called “pachyvessels” with attenuation of choriocapillaris, that sometimes accompany retinal pigment epithelium (RPE) abnormalities and/or choroidal vascular hyperpermeability (CVH).<sup>1</sup> The pachychoroid phenotype is often associated with the development of a spectrum of clinical diseases, including pigment epitheliopathy, central serous chorioretinopathy, and choroidal neovascularization.<sup>2-4</sup> Pachychoroid neovascularopathy is a newly recognized clinical entity of choroidal neovascularization (CNV) induced by pachychoroid phenotype-driven pathophysiological mechanisms.<sup>2,5</sup> Importantly, pachychoroid neovascularopathy can masquerade as other diseases presenting with CNV and may be misinterpreted as neovascular AMD.<sup>2,6</sup> However, it is currently controversial whether pachychoroid neovascularopathy should be distinguished from neovascular AMD because CNV in pachychoroid neovascularopathy has an appearance similar to that in neovascular AMD.

Vascular endothelial growth factor (VEGF), initially identified as a vascular permeability factor, plays a pivotal role in the pathogenesis of neovascular AMD.<sup>7,8</sup> Experimental rat models of CNV revealed a temporal relationship between the

expression of VEGF and development of CNV.<sup>9</sup> CNV membranes surgically excised from patients with AMD strongly expressed VEGF,<sup>10</sup> and the aqueous humor of patients with AMD showed a significant increase in VEGF levels when compared with control eyes without ocular disease.<sup>11</sup> Anti-VEGF therapy, such as ranibizumab and aflibercept, can suppress the activity of CNV and dramatically improves the visual outcome in patients with AMD.<sup>12,13</sup> However, it is unclear if VEGF expression levels are upregulated in pachychoroid neovascularopathy as they are in neovascular AMD, although anti-VEGF therapy is effective in both conditions.<sup>5</sup>

The purpose of this study was to investigate the difference between pachychoroid neovascularopathy and neovascular AMD with respect to VEGF dependency by determining intraocular VEGF concentrations and responses to injections of anti-VEGF as an initial treatment in the two conditions.

## METHODS

### Study Design and Setting

This was an interventional case-control study conducted in an institutional setting. The study design was approved by the



Institutional Review Board of Kyoto University Graduate School of Medicine, and the study protocol adhered to the tenets of the Declaration of Helsinki. All patients provided written informed consent for the treatments. All patients were fully informed of the purpose of and the procedures used for the measurement of VEGF concentration, and the sampling of aqueous humor was performed in each patient from whom written consent was obtained.

### Study Population

We included 30 eyes from 30 consecutive patients (1) who visited the macular service of Kyoto University Hospital (Kyoto, Japan) between June 2013 and January 2015, (2) who were diagnosed with either treatment-naïve pachychoroid neovascularopathy or treatment-naïve neovascular AMD, (3) who were older than 50 years, (4) who were treated with anti-VEGF therapy (ranibizumab or aflibercept; 3 monthly injections), and (5) whose aqueous humor VEGF levels were measured before the initial anti-VEGF injection. Patients with any of the following conditions were excluded: CNV secondary to high myopia (spherical equivalent,  $\leq -6.00$  D or axial length  $\geq 26$  mm), trauma, angioid streaks, uveitis, or any other neovascular maculopathy; choroidal thickness not available because of thick hemorrhage; and history of ocular surgery other than for cataract, providing that the cataract surgery had not been performed within the previous 3 months.

Patients were treated with 3 monthly loading intravitreal injections of 0.5 mg ranibizumab (Lucentis; Novartis International AG, Basel, Switzerland) from June 2013 through April 2014, followed by an as-needed regimen of ranibizumab, or with 3 monthly loading intravitreal injections of 2 mg aflibercept (Eylea; Bayer HealthCare Pharmaceuticals, Berlin, Germany) from April 2014 through January 2015, followed by bimonthly injections of aflibercept. The treatment and examination protocol used in this research have been reported previously.<sup>14,15</sup> Briefly, after 3 consecutive monthly loading injections of ranibizumab, patients were monitored monthly, and each patient was retreated if there was a decrease in vision relative to the previous visit or if new macular hemorrhage or fluid accumulation was detected on optical coherence tomography (OCT). For aflibercept, participants underwent 3 monthly injections and then bimonthly injections of aflibercept 2.0 mg during the first year. Before loading treatment, each patient underwent a comprehensive ophthalmic examination, including measurement of best corrected visual acuity and intraocular pressure, indirect ophthalmoscopy, slit-lamp biomicroscopy with a contact lens, color fundus photography (TRC-NW8F; Topcon Corp., Tokyo, Japan), spectral-domain OCT (Spectralis HRA+OCT; Heidelberg Engineering, Heidelberg, Germany), fundus autofluorescence, and fluorescein and indocyanine green angiography (HRA-2; Heidelberg Engineering).

The greatest linear dimension was determined based on indocyanine green angiography. Thirty-degree horizontal and vertical scans through the fovea were recorded using normal and enhanced depth-imaging (EDI) mode with averaging of 100 scans. A total of 13 raster scans covering a  $30^\circ \times 10^\circ$  field size were performed, averaging 50 scans for each scan. The central retinal thickness (CRT) and choroidal thickness (CT) were measured with a built-in caliper tool (Spectralis HRA+OCT). A grader (M.H.) masked to visual outcome performed these measurements. Inverted OCT images, which enable us to measure choroidal thickness, were routinely obtained in all patients using an EDI technique.<sup>16</sup> After 3 consecutive monthly loading injections and at the 12-month visit, the presence of fluid accumulation was determined by spectral-domain optical coherence tomography (SD-OCT). Dry macula was defined as complete resolution of intraretinal and/or subretinal fluid

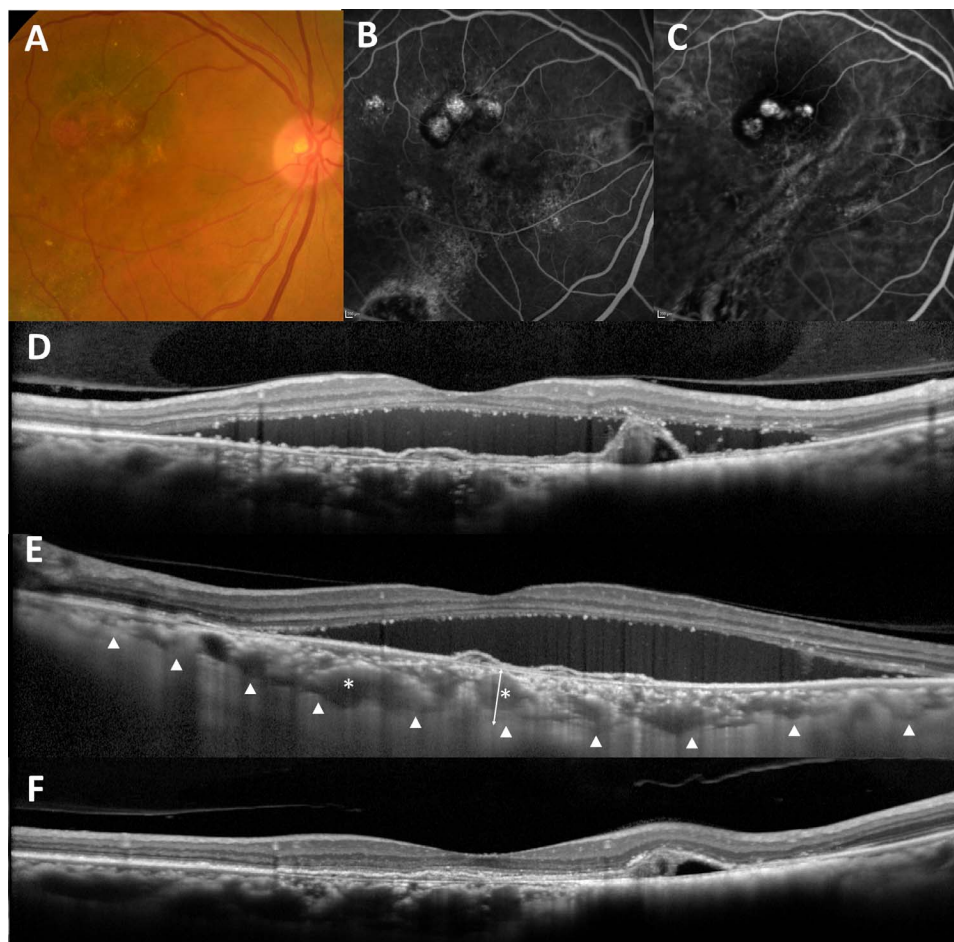
detected by SD-OCT raster scan at 1 month after the loading treatment and at the 12-month visit. Wet macula was defined as existence of any retinal fluid detected by OCT. The persistence of pigment epithelial detachment was not considered to be wet macula.

### Image Analysis

Soft drusen were graded based on fundus photographs according to the severity scale for AMD from the Age-Related Eye Disease Study.<sup>17</sup> Subfoveal choroidal thickness and choroidal vascular hyperpermeability were evaluated as previously described.<sup>18</sup> Briefly, subfoveal choroidal thickness was defined as the vertical distance between Bruch's membrane and the choriocleral interface at the fovea, which was manually measured in the EDI-OCT images by a retinal specialist blinded to the study parameters using the built-in caliper. Choroidal vascular hyperpermeability (CVH) was determined by detecting multifocal hyperfluorescent areas with blurred margins that expanded during the late phase of indocyanine green angiography (i.e., 10–15 minutes after injection of dye).<sup>5</sup> The presence of CVH was confirmed only when the independent judgments of two retinal specialists (M.H. and M.M.) were in agreement. The number of quadrants with dilated choroidal vessels was also evaluated for each eye based on wide-field indocyanine green angiography images using Spectralis HRA+OCT with a  $55^\circ$  wide-field lens taken 5 to 10 minutes after dye injection. RPE abnormality was defined by patchy areas of granular hypoautofluorescence with occasional discrete hyperautofluorescent specks scattered throughout the fundus autofluorescence image, according to the original report of pachychoroid pigment epitheliopathy and our previous report.<sup>4,5</sup> RPE abnormality is often seen in the CNV lesion; therefore, only RPE abnormalities occurring independent of CNV lesions were evaluated in this study. The presence of RPE abnormality was only confirmed when independent judgments of two retinal specialists (M.H. and M.M.) agreed. The presence of subretinal hemorrhage (SRH) larger than one disc diameter (DD) was judged in a 6-mm diameter macular area based on fundus photographs. The presence of hard exudate was also judged in a 6-mm diameter macular area based on fundus photographs. The presence of complete posterior vitreous detachment (PVD) was determined using the SD-OCT images. We defined eyes as having complete PVD if detached vitreous was seen in all 13 raster scans or if there was total absence of the posterior hyaloid on SD-OCT, and the presence of PVD was confirmed by the identification of a detached posterior vitreous cortex with a Weiss ring on funduscopic examination.

### Definition of Pachychoroid Neovascularopathy and Neovascular AMD

We employed the criteria for pachychoroid neovascularopathy in the previous report<sup>5</sup>; pachychoroid neovascularopathy was diagnosed if all of the following criteria were met: (1) CNV in either eye; (2) subfoveal choroidal thickness  $\geq 200$   $\mu\text{m}$  in both eyes; (3) no drusen or only nonextensive (total area,  $\leq 125$   $\mu\text{m}^2$ ) hard drusen ( $\leq 63$   $\mu\text{m}$ ) in both eyes (Age-Related Eye Disease Study level 1, no AMD)<sup>17</sup>; (4) central serous chorioretinopathy (CSC), or pachychoroid pigment epitheliopathy characteristics; namely, choroidal vascular hyperpermeability, RPE abnormality independent of a CNV lesion, the presence of dilated choroidal vessels or choroidal thickening below the type 1 CNV, or a history of CSC. Neovascular AMD was diagnosed if the following criteria were met: Patients with CNV and other findings corresponding to Age-Related Eye Disease Study levels 2, 3, and 4 (extensive hard



**FIGURE 1.** A 72-year-old woman was visually impaired in the right eye with pachychoroid neovascularopathy. Color fundus photography (A) reveals orange-red nodular lesion, serous retinal detachment, and hard exudates. Fluorescein angiography (B) reveals a window defect corresponding to RPE atrophy and occult choroidal neovascularization. Indocyanine green angiography (C) shows choroidal neovascularization and some polypoidal lesions. A vertical optical coherence tomography (OCT) scan through the fovea (D) shows subretinal fluid and protrusion of retinal pigment epithelium resulting from polypoidal lesions. A horizontal enhanced depth imaging OCT scan through the fovea (E) shows thickened subfoveal choroidal thickness (370  $\mu\text{m}$ ) and pachyvessels (asterisks). An OCT scan through the fovea (E) shows resolution of subretinal fluid after 3 monthly injections of aflibercept. The intraocular VEGF concentration before treatments was 49.2 pg/ml.

drusen, soft drusen [intermediate,  $\geq 63$  and  $< 125$   $\mu\text{m}$ ; large,  $\geq 125$   $\mu\text{m}$ ], pseudodrusen, focal hyperpigmentation, or geographic atrophy), subfoveal choroidal thickness  $< 200$   $\mu\text{m}$  in either eye, or no CSC/pachychoroid pigment epitheliopathy characteristics.<sup>5</sup>

### Concentration of VEGF

Before intravitreal injection of ranibizumab or aflibercept, a sample of undiluted aqueous humor (usually a volume of 0.2 ml) was manually aspirated into a disposable syringe, immediately transferred to a sterile tube, and stored at  $-80^{\circ}\text{C}$  until assay. The concentration of VEGF was measured by enzyme-linked immunosorbent assay using a kit (R&D Systems, Minneapolis, MN, USA) according to the manufacturer's instructions. This VEGF kit allows detection of two of the four VEGF isoforms (VEGF121 and VEGF165). The detection limit was 2.2 pg/ml.

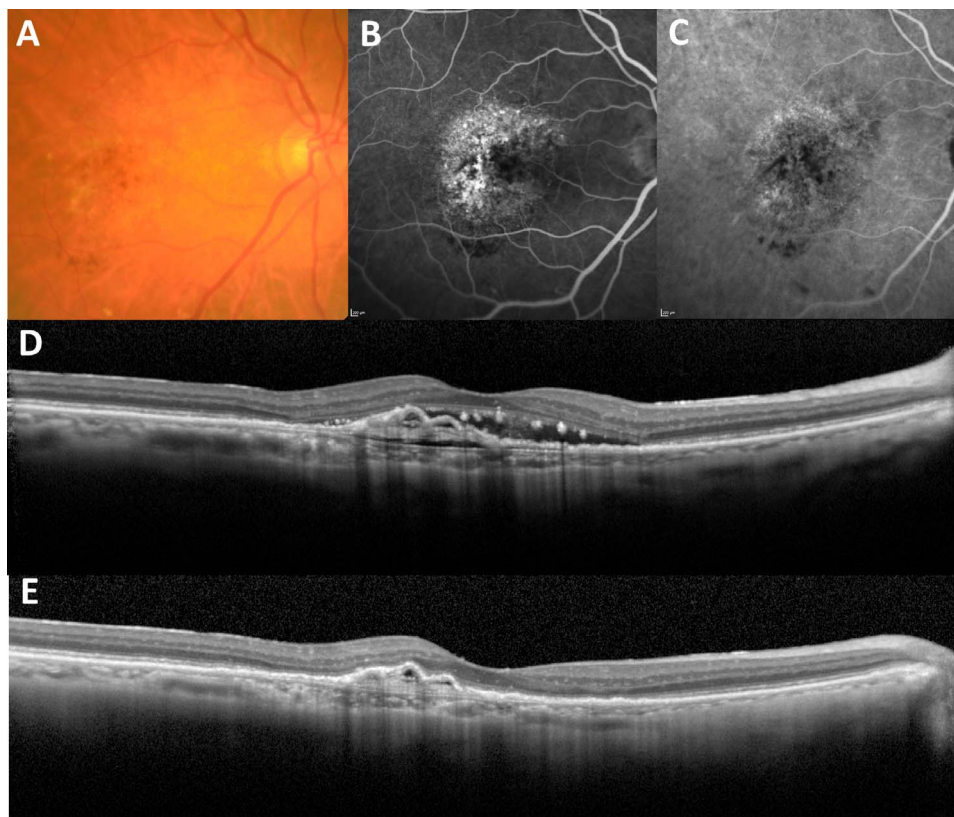
### Statistical Analysis

All values are presented as either the mean (standard deviation) or the number. Statistical analysis was performed using SPSS version 19 software (IBM Japan, Tokyo, Japan). Mann-Whitney

*U* tests were used to compare patient age, CRT at baseline, CT at baseline, and greatest linear dimension between eyes with pachychoroid neovascularopathy and eyes with neovascular AMD, and between eyes with dry macula and eyes with wet macula after the loading dose. Fisher exact tests were used to compare the sex ratio, lens status (phakic or pseudophakic), type of CNV type (type 1 or type 2) and rates of polypoidal lesions, CVH, soft drusen, SRH ( $> 1$  DD), hard drusen, PVD, and the treatment drug between eyes with pachychoroid neovascularopathy and eyes with neovascular AMD, and between eyes with dry macula and eyes with wet macula after the loading dose and at 12 months. A *P* value  $< 0.05$  was considered to be statistically significant. We evaluated the association of baseline characteristics with the VEGF concentration using univariate analysis. Baseline factors with *P*  $< 0.20$  in univariate analysis were included in multivariate linear regression analysis to assess the independent effect of VEGF concentration.

### RESULTS

A total of 30 patients met the criteria for the current study. Nine (30.0%) of the participants were diagnosed with pachychoroid neovascularopathy, and 21 (70.0%) patients were



**FIGURE 2.** A 86-year-old man was visually impaired in the right eye with typical age-related macular degeneration. Color fundus photography (A) reveals serous retinal detachment and pigmentation with soft drusen within the macula. Fluorescein angiography (B) suggests occult CNV. Indocyanine green angiography (C) shows choroidal neovascularization. A horizontal optical coherence tomography scan through the fovea (D) shows subretinal fluid, type 1 CNV and thin subfoveal choroidal thickness (137  $\mu\text{m}$ ). An optical coherence tomography scan (E) showed the resolution of subretinal fluid after 3 monthly injections of aflibercept. The intraocular VEGF concentration before treatments was 131.5 pg/ml.

diagnosed with neovascular AMD (Figs. 1, 2). The characteristics of each group are shown in Table 1. The mean age was 75.2 (6.5) years in pachychoroid neovasculopathy and 80.0 (9.4) years in neovascular AMD. The presence of choroidal vascular hyperpermeability is seen in 4 (44.4%) of 9 eyes with pachychoroid neovasculopathy and 5 (23.8%) of 21 eyes with neovascular AMD. Patients with pachychoroid neovasculopathy had greater subfoveal choroidal thickness ( $P = 0.002$ ) and fewer drusen ( $P = 6.1 \times 10^{-5}$ ). Central retinal thickness, the presence of CVH, a polypoidal lesion, hard exudate, complete PVD, and GLD were not different between the two groups. Although patients with pachychoroid neovasculopathy tended to be younger and had SRH more frequently, the differences were not statistically significant ( $P = 0.181$  and  $0.141$ , respectively).

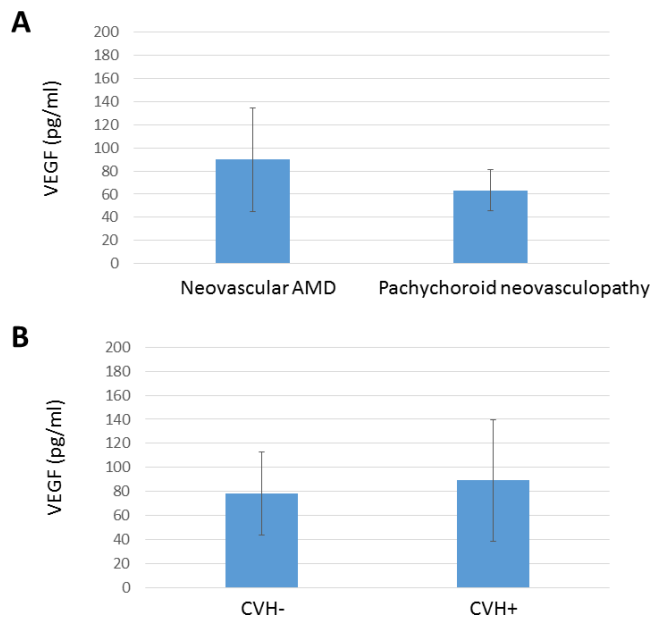
The mean concentration of VEGF was 63.4 (17.8) pg/ml in the eyes with pachychoroid neovasculopathy, which was significantly lower than 89.8 (45.0) pg/ml in the eyes with neovascular AMD ( $P = 0.035$ ; Fig. 3). In contrast, the mean concentration of VEGF did not differ between eyes with and without CVH (89.1 [50.5] pg/ml vs. 78.2 [34.3] pg/ml,  $P = 0.421$ ; Fig. 3). We investigated the baseline factors associated with the VEGF concentration (Table 2). Among baseline clinical factors, VEGF concentration was associated with the presence or absence of drusen ( $\beta = 0.503$ ,  $P = 0.004$ ).

We evaluated the factors associated with the response to anti-VEGF therapy in pachychoroid neovasculopathy and neovascular AMD. After the loading dose of anti-VEGF therapy, 6 of 9 eyes (66.7%) with pachychoroid neovasculopathy achieved dry macula, and 17 of 21 eyes (81.0%) with

**TABLE 1.** Demographics Characteristics of the Patients in This Study

Characteristic	Pachychoroid Neovasculopathy, <i>n</i> = 9	Neovascular AMD, <i>n</i> = 21	<i>P</i> Value
Age, y	75.2 (6.5)	80.0 (9.4)	0.181
Sex, male/female	7/2	14/7	0.681
Lens status, phakic/pseudophakic	6/3	15/6	1.000
CNV type, type I/type II	9/0	18/3	0.535
Polypoidal lesion	4 (44.4%)	7 (33.3%)	0.687
CRT at baseline, $\mu\text{m}$	251.2 (130.8)	285.5 (99.0)	0.437
CT at baseline, $\mu\text{m}$	312.2 (88.8)	177.5 (99.1)	0.002
Greatest linear dimension, $\mu\text{m}$	2815.9 (720.2)	2978.3 (1354.7)	0.738
CVH	4 (44.4%)	5 (23.8%)	0.389
Choroidal vascular dilation, number of quadrants	0.67 (0.67)	0.38 (0.65)	0.301
SRH (>1 DD)	0 (0)	6 (28.6)	0.141
Hard exudate	3 (33.3%)	5 (23.8%)	0.666
Complete PVD	4 (44.4%)	14 (66.7%)	0.418
Aflibercept/Ranibizumab	9/0	17/4	0.287

Patients were treated with ranibizumab June 2013 through April 2014 or aflibercept from April 2014 through January 2015.



**FIGURE 3.** Comparison of the aqueous humor VEGF concentration level between eyes with neovascular AMD and eyes with pachychoroid neovascularopathy (A) and between eyes with and without CVH (B).

neovascular AMD achieved dry macula ( $P = 0.640$ ). In eyes with pachychoroid neovascularopathy, dry macula at 3 months was significantly associated with low VEGF concentration ( $P = 0.013$ ; Table 3). In eyes with neovascular AMD, dry macula at 3 months was significantly associated with low CRT, but was not associated with low VEGF concentration ( $P = 0.036$ ,  $P = 0.108$ , respectively; Table 4). Of 21 eyes with neovascular AMD, 4 were treated with ranibizumab, and there was no significant difference in the responses to anti-VEGF therapy between ranibizumab treatment and aflibercept treatment after 3 monthly injections ( $P = 1.000$ ).

At the 12-month visit, dry macula was achieved in 5 of 9 eyes (55.6%) with pachychoroid neovascularopathy and in 16 of 19 eyes (84.2%) with neovascular AMD (dry macula rate: pachychoroid neovascularopathy vs. neovascular AMD,  $P = 0.165$ ). Two eyes with neovascular AMD were lost to follow-

**TABLE 2.** Analysis of Baseline Factors Associated With VEGF Concentration as the Dependent Variable

Parameter	<i>P</i> Value, Univariable	<i>P</i> Value, Multivariable
Age	0.135, $R = 0.279$	0.211
Lens status, phakic/pseudophakic	0.412, $R = 0.155$	-
CNV type, type I/type II	0.397, $R = -0.160$	-
Polypoidal lesion	0.848, $R = -0.037$	-
CRT at baseline, $\mu\text{m}$	0.037, $R = 0.383$	0.279
CT at baseline, $\mu\text{m}$	0.817, $R = -0.044$	-
Greatest linear dimension, $\mu\text{m}$	0.406, $R = 0.157$	-
CVH	0.421, $R = 0.155$	-
Drusen	0.022, $R = 0.417$	0.004, $\beta = 0.503$
SRH (>1DD)	0.571, $R = 0.108$	-
Hard exudate	0.595, $R = 0.101$	-
Pachychoroid/nonpachychoroid	0.112, $R = 0.296$	0.668
Aflibercept/Ranibizumab	0.282, $R = 0.203$	-

**TABLE 3.** Associated Factors With Dry Macula After Loading Dose Anti-VEGF in Pachychoroid Neovascularopathy

Parameter	Dry, $n = 6$	Wet, $n = 3$	<i>P</i> Value
Lens status, phakic/pseudophakic	4/2	2/1	1.000
VEGF level, pg/ml	53.6 (8.6)	83.0 (15.0)	0.013
CRT at baseline, $\mu\text{m}$	246.0 (130.9)	261.7 (105.8)	0.878
CT at baseline, $\mu\text{m}$	283.2 (87.8)	370.3 (24.1)	0.180
Greatest linear dimension, $\mu\text{m}$	2742.7 (662.5)	2962.3 (688.0)	0.695
CVH	2 (33.3%)	2 (66.7%)	0.524
Drusen	0	0	1.000
SRH (>1 DD)	0	0	1.000
Hard exudate	1 (16.7%)	2 (66.7%)	0.226

up at 12 months. In eyes with pachychoroid neovascularopathy, there was a significant association between dry macula at 12 months and low VEGF concentration (52.5 [9.0] pg/ml vs. 77.0 [16.0] pg/ml,  $P = 0.042$ ). In eyes with neovascular AMD, dry macula at 12 months was not associated with a low VEGF concentration (89.2 [45.2] pg/ml vs. 125.1 [20.8] pg/ml,  $P = 0.219$ ). The number of anti-VEGF treatments did not differ between eyes with dry macula and those with wet macula either in pachychoroid neovascularopathy or neovascular AMD (pachychoroid neovascularopathy, 6.8 [0.4] vs. 7.0 [0.0],  $P = 0.407$ ; neovascular AMD, 6.6 [1.0] vs. 6.3 [0.9],  $P = 0.662$ ).

## DISCUSSION

In the present study, we investigated the intraocular VEGF concentration in pachychoroid neovascularopathy and neovascular AMD, and the correlation with responses to 3 monthly injections of anti-VEGF therapy as an initial treatment in these two clinical conditions. We found that the mean VEGF concentration of pachychoroid neovascularopathy was more than 70% of that of neovascular AMD despite a significantly lower VEGF concentration when compared with neovascular AMD. Furthermore, despite the small sample size, we found a significant association between VEGF concentration and the response to treatment in pachychoroid neovascularopathy, but not in neovascular AMD. This result suggests that high VEGF concentrations at baseline can predict a poor response to anti-VEGF therapy in pachychoroid neovascularopathy.

In the current study, we measured the VEGF level in pachychoroid neovascularopathy as well as in neovascular AMD.

**TABLE 4.** Associated Factors With Dry Macula After Loading Dose Anti-VEGF in Neovascular AMD

Parameter	Dry, $n = 17$	Wet, $n = 4$	<i>P</i> Value
Lens status, phakic/pseudophakia	13/4	2/2	0.544
CNV type, type I/type II	14/3	4/0	1.000
VEGF level, pg/ml	81.9 (32.5)	123.3 (69.1)	0.108
CRT at baseline, $\mu\text{m}$	263.9 (83.0)	377.3 (96.5)	0.036
CT at baseline, $\mu\text{m}$	178.6 (97.1)	172.8 (94.6)	0.918
Greatest linear dimension, $\mu\text{m}$	2947.3 (1275.9)	3110.3 (1495.2)	0.835
CVH	3 (17.6%)	2 (50.0%)	0.228
Drusen	15 (88.2%)	3 (75.0%)	0.521
SRH (>1 DD)	4 (23.5%)	2 (50.0%)	0.544
Hard exudate	4 (23.5%)	1 (25.0%)	1.000
Aflibercept/Ranibizumab	14/3	3/1	1.000

Levels of VEGF in the aqueous humor of patients with neovascular AMD in the present study were consistent with those in patients with neovascular AMD in previous studies, which demonstrated a significantly increased concentration of intraocular VEGF in neovascular AMD when compared with control eyes.<sup>19,20</sup> We also found that the mean VEGF concentration in pachychoroid neovascularopathy was more than 70% of that of neovascular AMD, indicating that the concentration of VEGF is high in pachychoroid neovascularopathy when compared with controls in the previous reports.<sup>20-22</sup> In fact, the efficacy of anti-VEGF therapy in AMD and pachychoroid neovascularopathy strongly supports the importance of VEGF in progression of both two diseases.<sup>5</sup>

When compared with neovascular AMD, the mean VEGF level in pachychoroid neovascularopathy was significantly lower. There could be three possibilities for the lower VEGF expression level in pachychoroid neovascularopathy. The first possibility is that pathogenic processes other than the VEGF-mediated process may exist in pachychoroid neovascularopathy. For example, in addition to VEGF upregulation, the thick choroid and CVH in pachychoroid neovascularopathy may affect the activity of choroidal neovascularization.<sup>1</sup> However, our results indicate favorable treatment efficacy of anti-VEGF therapy even in pachychoroid neovascularopathy. The second possibility is that choroidal neovascularization in the pachychoroid phenotype is triggered by a lower VEGF concentration threshold than neovascular AMD. If such a lower threshold exists, inhibiting VEGF with anti-VEGF therapy may be even more important for suppressing CNV activity in eyes with pachychoroid neovascularopathy. The third possibility is a compartment effect whereby VEGF may be more confined to the choroid in pachychoroid neovascularopathy than in neovascular AMD, although there was no difference in the rate of type 1 CNV between the two conditions. Further investigation would be needed to determine appropriate therapy for each condition based on pathophysiology.

No association was found between the presence of CVH and VEGF concentrations. The presence of CVH is a characteristic finding in eyes with CSC and more than 90% of patients with CSC present with CVH.<sup>23,24</sup> However, CVH is often seen in eyes with neovascular AMD and pachychoroid neovascularopathy.<sup>25-27</sup> In fact, 44.4% of patients with pachychoroid neovascularopathy and 23.8% of those with neovascular AMD presented with CVH in the present study. Combined with previous reports showing that the VEGF level was not elevated in CSC when compared with control eyes,<sup>21,22</sup> our data indicate that CVH did not show a direct association with VEGF expression, suggesting that CVH may not cause VEGF upregulation contributing to progression of CNV, although CVH may cause RPE abnormalities independent of VEGF upregulation.

On the other hand, the presence of soft drusen was significantly associated with the VEGF level. Drusen are extracellular debris deposits, containing a variety of RPE waste products, lipids, polysaccharides, glycosaminoglycans, and proteins, which accumulate below the RPE during aging.<sup>28</sup> Drusen create a barrier to diffusion of metabolites in Bruch's membrane, hampering RPE nutrition from the choroid, and localized hypoxia overlying regions of drusen deposition may increase the risk of VEGF upregulation because hypoxia is a major inducer of VEGF gene transcription.<sup>29</sup> Furthermore, drusen proteins are involved in inflammation, which may activate microglia to stimulate RPE cells to express VEGF via releasing cytokines.<sup>30</sup> Our data for the associations between drusen and VEGF expression level support this hypothesis.

Although the current study has significant implications, it does have several limitations. In addition to including a relatively small number of cases, the criteria for diagnosing

pachychoroid neovascularopathy may not be ideal because no standard diagnostic criteria have been established so far. We did not follow the VEGF level after anti-VEGF therapy. Furthermore, we did not have a normal control group. There may be other factors influencing VEGF concentration, although the presence of PVD, which has been reported to affect VEGF concentration, did not differ between the two groups.

In conclusion, we found a significantly lower VEGF concentration in pachychoroid neovascularopathy when compared with neovascular AMD. This finding supports the speculation that the way in which VEGF is involved in angiogenesis may differ between pachychoroid neovascularopathy and neovascular AMD. Further studies are warranted to understand neovascularization in the pachychoroid phenotype.

### Acknowledgments

Supported in part by a grant-in-aid for scientific research (no. 24791847) from the Japan Society for the Promotion of Science, Tokyo, Japan, and the Innovative Techno-Hub for Integrated Medical Bio-Imaging of the Project for Developing Innovation Systems from the Ministry of Education, Culture, Sports, Science, and Technology, Tokyo, Japan. None of these organizations had any role in the design or conduct of this research.

Disclosure: **M. Hata**, None; **K. Yamashiro**, None; **S. Ooto**, Alcon Japan (F); **A. Oishi**, Alexander von Humboldt Foundation (F), Alcon Japan (F); **H. Tamura**, None; **M. Miyata**, None; **N. Ueda-Arakawa**, None; **A. Takahashi**, None; **A. Tsujikawa**, Pfizer (F); Topcon Corporation (F), Nidek (F, R), Canon (F); **N. Yoshimura**, None

### References

- Balaratnasingam C, Lee WK, Koizumi H, Dansingani K, Inoue M, Freund KB. Polypoidal choroidal vasculopathy: a distinct disease or manifestation of many? *Retina*. 2016;36:1-8.
- Pang CE, Freund KB. Pachychoroid neovascularopathy. *Retina*. 2015;35:1-9.
- Gallego-Pinazo R, Dolz-Marco R, Gomez-Ulla F, Mrejen S, Freund KB. Pachychoroid diseases of the macula. *Med Hypothesis Discov Innov Ophthalmol*. 2014;3:111-115.
- Warrow DJ, Hoang QV, Freund KB. Pachychoroid pigment epitheliopathy. *Retina*. 2013;33:1659-1672.
- Miyake M, Ooto S, Yamashiro K, et al. Pachychoroid neovascularopathy and age-related macular degeneration. *Sci Rep*. 2015;5:16204.
- Fung AT, Yannuzzi LA, Freund KB. Type 1 (sub-retinal pigment epithelial) neovascularization in central serous chorioretinopathy masquerading as neovascular age-related macular degeneration. *Retina*. 2012;32:1829-1837.
- Aiello LP, Avery RL, Arrigg PG, et al. Vascular endothelial growth factor in ocular fluid of patients with diabetic retinopathy and other retinal disorders. *N Engl J Med*. 1994; 331:1480-1487.
- Witmer AN, Vrensen GF, Van Noorden CJ, Schlingemann RO. Vascular endothelial growth factors and angiogenesis in eye disease. *Prog Retin Eye Res*. 2003;22:1-29.
- Wang F, Rendahl KG, Manning WC, Quiroz D, Coyne M, Miller SS. AAV-mediated expression of vascular endothelial growth factor induces choroidal neovascularization in rat. *Invest Ophthalmol Vis Sci*. 2003;44:781-790.
- Lopez PF, Sippy BD, Lambert HM, Thach AB, Hinton DR. Transdifferentiated retinal pigment epithelial cells are immunoreactive for vascular endothelial growth factor in surgically excised age-related macular degeneration-related choroidal

- neovascular membranes. *Invest Ophthalmol Vis Sci.* 1996;37:855-868.
11. Tong JP, Chan WM, Liu DT, et al. Aqueous humor levels of vascular endothelial growth factor and pigment epithelium-derived factor in polypoidal choroidal vasculopathy and choroidal neovascularization. *Am J Ophthalmol.* 2006;141:456-462.
  12. Brown DM, Kaiser PK, Michels M, et al. Ranibizumab versus verteporfin for neovascular age-related macular degeneration. *N Engl J Med.* 2006;355:1432-1444.
  13. Rosenfeld PJ, Brown DM, Heier JS, et al. Ranibizumab for neovascular age-related macular degeneration. *N Engl J Med.* 2006;355:1419-1431.
  14. Kuroda Y, Yamashiro K, Tsujikawa A, et al. Retinal pigment epithelial atrophy in neovascular age-related macular degeneration after ranibizumab treatment. *Am J Ophthalmol.* 2016;161:94-103.e1.
  15. Oishi A, Tsujikawa A, Yamashiro K, et al. One-year result of aflibercept treatment on age-related macular degeneration and predictive factors for visual outcome. *Am J Ophthalmol.* 2015;159:853-860.e1.
  16. Spaide RF, Koizumi H, Pozzoni MC. Enhanced depth imaging spectral-domain optical coherence tomography. *Am J Ophthalmol.* 2008;146:496-500.
  17. Age-Related Eye Disease Study Research Group. The Age-Related Eye Disease Study system for classifying age-related macular degeneration from stereoscopic color fundus photographs: the Age-Related Eye Disease Study Report Number 6. *Am J Ophthalmol.* 2001;132:668-681.
  18. Hata M, Oishi A, Tsujikawa A, et al. Efficacy of intravitreal injection of aflibercept in neovascular age-related macular degeneration with or without choroidal vascular hyperpermeability. *Invest Ophthalmol Vis Sci.* 2014;55:7874-7880.
  19. Nomura Y, Takahashi H, Tan X, Fujino Y, Kawashima H, Yanagi Y. Effect of posterior vitreous detachment on aqueous humor level of vascular endothelial growth factor in exudative age-related macular degeneration patients. *Graefes Arch Clin Exp Ophthalmol.* 2016;254:53-57.
  20. Funk M, Karl D, Georgopoulos M, et al. Neovascular age-related macular degeneration: intraocular cytokines and growth factors and the influence of therapy with ranibizumab. *Ophthalmology.* 2009;116:2393-2399.
  21. Jung SH, Kim KA, Sohn SW, Yang SJ. Cytokine levels of the aqueous humor in central serous chorioretinopathy. *Clin Exp Optom.* 2014;97:264-269.
  22. Shin MC, Lim JW. Concentration of cytokines in the aqueous humor of patients with central serous chorioretinopathy. *Retina.* 2011;31:1937-1943.
  23. Lafaut BA, Salati C, Priem H, De Laey JJ. Indocyanine green angiography is of value for the diagnosis of chronic central serous chorioretinopathy in elderly patients. *Graefes Arch Clin Exp Ophthalmol.* 1998;236:513-521.
  24. Spaide RF, Hall L, Haas A, et al. Indocyanine green videoangiography of older patients with central serous chorioretinopathy. *Retina.* 1996;16:203-213.
  25. Koizumi H, Yamagishi T, Yamazaki T, Kinoshita S. Relationship between clinical characteristics of polypoidal choroidal vasculopathy and choroidal vascular hyperpermeability. *Am J Ophthalmol.* 2013;155:305-313.e1.
  26. Sasahara M, Tsujikawa A, Musashi K, et al. Polypoidal choroidal vasculopathy with choroidal vascular hyperpermeability. *Am J Ophthalmol.* 2006;142:601-607.
  27. Jirattanasopa P, Ooto S, Nakata I, et al. Choroidal thickness, vascular hyperpermeability, and complement factor H in age-related macular degeneration and polypoidal choroidal vasculopathy. *Invest Ophthalmol Vis Sci.* 2012;53:3663-3672.
  28. Crabb JW. The proteomics of drusen. *Cold Spring Harb Perspect Med.* 2014;4:a017194.
  29. Ma W, Lee SE, Guo J, et al. RAGE ligand upregulation of VEGF secretion in ARPE-19 cells. *Invest Ophthalmol Vis Sci.* 2007;48:1355-1361.
  30. Bhutto I, Luty G. Understanding age-related macular degeneration (AMD): relationships between the photoreceptor/retinal pigment epithelium/Bruch's membrane/choriocapillary complex. *Mol Aspects Med.* 2012;33:295.