

Analysis of Retinal Segmentation Changes at High Altitude With and Without Acetazolamide

Alexander Kenneth Clarke,¹ Mariano Cozzi,² Christopher Henry Ernest Imray,² Alex Wright,³ and Sergio Pagliarini²; for the Birmingham Medical Research Expeditionary Society

¹Institute of Neuroscience, Newcastle University, Newcastle upon Tyne, United Kingdom

²University Hospitals Coventry and Warwickshire NHS Trust, Coventry, United Kingdom

³College of Medical and Dental Sciences, University of Birmingham, Birmingham, United Kingdom

Correspondence: Alexander Kenneth Clarke, Institute of Neuroscience, Newcastle University, Newcastle-upon-Tyne NE1 7RU, UK; alexkclarke@gmail.com.

Submitted: June 6, 2018

Accepted: November 21, 2018

Citation: Clarke AK, Cozzi M, Imray CHE, Wright A, Pagliarini S; for the Birmingham Medical Research Expeditionary Society. Analysis of retinal segmentation changes at high altitude with and without acetazolamide. *Invest Ophthalmol Vis Sci.* 2019;60:36–40. <https://doi.org/10.1167/iovs.18-24966>

PURPOSE. Our aim was to assess retinal venous diameter and segmented retinal layer thickness variation in acute systemic hypoxia with and without acetazolamide and to relate these changes to high altitude headache (HAH), as a proxy for intracerebral pathophysiology.

METHODS. A total of 20 subjects participated in a 4-day ascent to the Margherita Hut (4,559 m) on Monte Rosa in the Italian Alps. Each participant was randomized to either oral acetazolamide 250 mg twice daily or placebo. A combination of digital imaging and optical coherence tomography was used to measure retinal vessel diameter and retinal layer thickness. Clinically-assessed HAH was recorded.

RESULTS. A total of 18 participants had usable digital and OCT images, with 12 developing HAH. Significant thickening was seen only in the two inner layers of the retina, the retinal nerve fiber layer (RNFL) and ganglion cell layer (GCL) at $P = 0.012$ and $P = 0.010$, respectively, independent of acetazolamide. There was a significant positive correlation between HAH and both retinal venous diameter ($T = 4.953$, $P = 0.001$) and retinal artery diameter ($T = 2.865$, $P = 0.015$), with both unaffected by acetazolamide ($F = 0.439$, $P = 0.518$).

CONCLUSIONS. Retinal venous diameter correlates positively with HAH, adding further evidence for the proposed venous outflow limitation mechanism. The inner layers of the retina swelled disproportionately when compared to the outer layers under conditions of systemic hypoxia. Acetazolamide does not appear to influence altitudinal changes of retinal layers and vasculature.

Keywords: high altitude headache, acute mountain sickness, capillary plexuses

High altitude headache (HAH) is the most common symptom in patients exposed to environmental hypoxia, and the core feature of acute mountain sickness (AMS) and the more serious high altitude cerebral edema. An ideal candidate for studying the pathophysiology of HAH is the retina, which is highly amenable to imaging and closely related to the intracranial anatomy. Recent investigations have focused on structures involved in the neurovascular supply of the retina (i.e., the optic disc, optic nerve sheath, and corresponding vasculature¹).

Wilson et al.^{2,3} proposed that HAH is caused by venous outflow limitation in the face of a compensatory rise in arterial flow, potentially worsened by venocompression due to cytotoxic parenchymal swelling.⁴ Of particular interest to an outflow deficit hypothesis is the diameter of the retinal veins, which share venous outflow with the brain. The presence of a correlation between HAH and the average retinal venous diameter (RVD) is disputed in the literature.^{5–7} There is, however, significant heterogeneity between these studies, both in the ascent profile and the clinical parameters measured.

Multilayer automatic segmentation of spectral domain optical coherence tomography (SD-OCT) images has been shown to quantify the thickness of the individual layers of the retina to a high degree of accuracy and test/retest reliability.^{8–10}

The retinal nerve fiber layer (RNFL) is of particular interest as both the origin of the optic nerve and a prominent headwater for retinal venous outflow. Correlation has been shown between RNFL thickness and RVD for patients with normal tension glaucoma.¹¹ Tian et al.¹² recently used OCT at high altitude to show thickening of the RNFL and adjacent ganglion cell layer (GCL). Of further interest are the histologic similarities between the innermost layers of the retina and the brain, including a population of astrocytes thought to migrate from the optic nerve.¹³ This allows a potential for direct observation of the effects of hypoxia on glial tissue common to the brain, the most likely candidate for cerebral parenchymal swelling.

We hypothesized that exposure to high altitude would cause thickening in the retinal layers primarily focused on the more vascular RNFL and GCL. The collection of retinal imagery during such exposure would also allow further examination of the disputed link between HAH and RVD changes. Here we describe a study looking at the effect of altitude on climbers ascending Monte Rosa (4559 m) in the Italian Alps. This study took place in the context of a research expedition looking at the effects of acetazolamide on exercise performance. Acetazolamide, a carbonic anhydrase inhibitor, is commonly used at high altitudes for both prevention and treatment of HAH.



METHODS

Participants

We included 20 participants (4 female, 16 male; mean age: 36.3, SD: 19.7) in this double-blind parallel study. Participants were paired by age and sex before being randomized by number generator to 250 mg twice daily of either acetazolamide or placebo capsules, with assessors also blinded to allocations. No participants suffered from any chronic ophthalmic conditions or were taking any medications with ophthalmic effects. Participants spent 1 night at 1600 m (Gressoney-La-Trinité) and then ascended at a rate of approximately 1000 m a day to 4559 m (Capanna Margherita). Participants ascended in 2 teams of 10 participants 1 day apart. Chichester University Research Ethics Committee approved the protocol as meeting the ethical principles of the Declaration of Helsinki, and each participant gave informed and signed consent.

Measurements and Analysis

At 1600 and 4559 m, all participants underwent nonmydriatic fundus digital photography and SD-OCT, using a nonmydriatic camera (Visucam; Carl-Zeiss, Oberkochen, Germany) and an OCT device (Spectralis; Heidelberg Engineering, Heidelberg, Germany), respectively, with the same machine used at both locations. The OCT device (Heidelberg Engineering) was also used to acquire near-infrared reflectance scanning laser ophthalmoscope (SLO) images. To evaluate exactly the same area of the OCT/SLO images at the two sites, the baseline reference from 1600 m was used at 4559 m, and a scanning laser eye tracking system (TRUEtrack; Trividia Health, Fort Lauderdale, FL, USA) was used at all times. The same machines were used for all measurements and imaging was done exclusively in the evening both to minimize diurnal variation and to capture images soon after arrival at the new altitude. The OCT was conducted centered to the undilated pupil, so as to keep the B-scans flat. This was to reduce the issue of visualizing the Henle's fiber layer and incorrectly attributing it to the outer plexiform layer (OPL) or outer nuclear layer (ONL) of the retina, confounding depth measurements.¹⁴

The OCT protocol included a peripapillary RNFL circular scan centered on the disc and macular scans centered on the fovea consisting of 25 fast volume $20^\circ \times 20^\circ$ lines raster with ART (automatic real time) image averaging set at 20. Heidelberg Engineering HEYEX version 6.3.2 was used to calculate the overall retinal thickness centered on the macula, as well as the thickness of eight retinal layers by fully automatic segmentation. Using the same software, the RNFL thickness was further analyzed topographically by division of the peripapillary region into superior, inferior, nasal, and temporal quadrants and of the macula into the Early Treatment Diabetic Retinopathy Study (ETDRS) grid.¹⁵ To reduce the chance of incorrect attribution of Henle's fiber layer affecting final statistical conclusions, the OPL and ONL thicknesses were combined for subanalysis alongside individual layer results.

Mean retinal vein and artery diameters were measured using semiautomated analysis software (Vesselmap1; Imedos, Jena, Germany). During the measurement procedure a peripapillary annulus was centered on the optic disc. The inner and outer concentric rings making up the annulus were respectively twice and three times the diameter of the optic disc. Only vessels that crossed an entire segment of the annulus were measured. The average diameter of at least four retinal veins were measured in each Visucam image, and only vessels that were measurable at both locations were selected. The same procedure was used for measurement of retinal arteries. To

further validate vessel diameter results, the same procedure was then applied to the SLO images. As there was a potential for the hypobaric conditions of high altitude to change the optical properties of the eye, the optic disc diameter was also measured as a control. All diameter and depth results were taken from the right eye only.

All participants also completed a Lake Louise Score (LLS) questionnaire, a measure of AMS, at each location in the morning and evening. Participants were categorized as having clinically significant AMS if they had both HAH and a LLS of three or more. The subject was defined as having HAH and/or AMS based on the questionnaire completed closest in time to the retinal imaging.

Statistical Analysis

All statistics were computed using the statistical software (SPSS statistics package; IBM Corp., Armonk, NY, USA). Analysis of covariance (ANCOVA) was used to analyze the effect of acetazolamide on different measures, while a repeat measures *t*-test was used to compare baseline measurements to those at altitude. Pearson χ^2 was used to assess the effect of intervention group on AMS and HAH. Independent samples *t*-tests were used for comparisons between participants who developed HAH and/or AMS and those who did not. Finally, Pearson correlation was used to compare vessel diameters measured from digital fundus photography versus those measured using SLO. To control the false discovery rate for the multiple segmentation comparisons the Benjamini-Hochberg procedure was used at a false discovery rate of 0.05, giving a critical threshold of 0.017 for significance.

RESULTS

Demographics and Effect of Acetazolamide

All 20 participants completed the expedition in its entirety, but of these 2 were omitted from analysis due to unusable retinal photography. The 18 included participants had an age range of 22 to 69 (average: 35). A total of eight participants were randomized to acetazolamide and 10 were taking placebo. AMS scores at the summit ranged from Lake Louise scores of 0 to 8, with an average of 2.2. Of the 18 participants 12 had HAH at the time of imaging, of which 4 met the criteria for AMS. There was no significant difference between the intervention and control groups in development of either AMS ($\chi^2 = 0.064$, $P = 0.800$) or HAH ($\chi^2 = 1.800$, $P = 0.180$).

Vessel Diameter

The RVD measured from the digital fundus images increased significantly by $8.9 \mu\text{m}$ (SD 4.3, $T = 8.865$, $P < 0.001$) at altitude, but there was no significant difference between intervention groups ($F = 1.644$, $P = 0.219$). Retinal artery diameter was also significantly raised with altitude, by $7.0 \mu\text{m}$ (SD = 3.4, $T = 7.050$, $P < 0.001$), and was similarly unaffected by acetazolamide ($F = 0.439$, $P = 0.518$). There was a significant positive correlation between the presence of HAH and both RVD ($T = 4.953$, $P = 0.001$) and retinal artery diameter ($T = 2.865$, $P = 0.015$). However, this did not extend to AMS, where there was no significant correlation between AMS scores and either retinal vein ($T = 0.275$, $P = 0.788$) or retinal artery ($T = 0.536$, $P = 0.610$) changes. Diameters measured using SLO images were highly correlated with those from the digital fundus camera for both retinal veins ($r = 0.772$, $P < 0.001$) and retinal arteries ($r = 0.813$, $P < 0.001$), with identical statistical conclusions regarding altitude, HAH and AMS. To reduce the chance that these changes were due to an

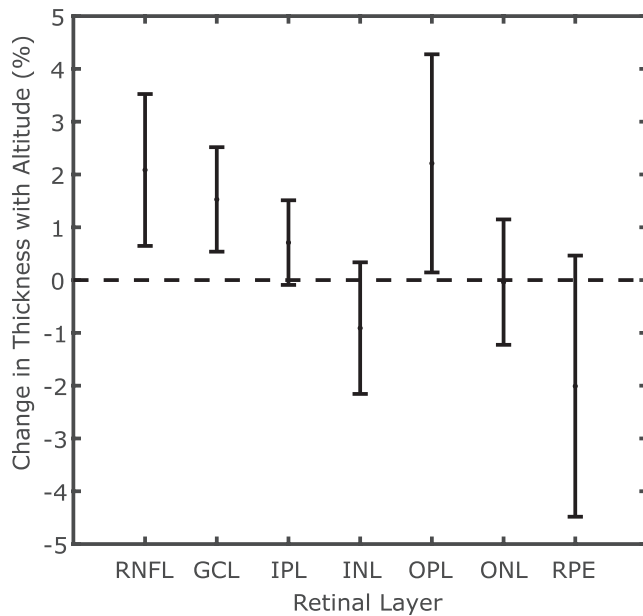


FIGURE 1. Percentage change in thickness with altitude by retinal layer. Error bars represent 95% confidence interval.

optical effect due to altitude-related pressure changes a third structure, the optic disc diameter, was also compared. This showed an extremely small and nonsignificant decrease ($T = 0.583$, $P = 0.568$) in the mean disc diameter, from 1514.6 to 1513.7 μm .

Retinal Layer Thickness

There was no significant change in the overall thickness of the retina with altitude ($T = 1.665$, $P = 0.114$); however, there were some significant changes in the individual retinal layers (Fig. 1). There was no significant difference between intervention and control groups either overall or any of the individual retinal layer thickness changes. In the macular scans, thickening of the two inner layers of the retina, the RNFL ($T = 2.828$, $P = 0.012$) and GCL ($T = 2.909$, $P = 0.010$) was significant (Table 1). An increase in the outer plexiform layer was not significant after post hoc correction ($T = 2.125$, $P = 0.049$). The combined ONL and OPL thickness showed no change with altitude ($T = 1.959$, $P = 0.067$).

Topographical Analysis of the RNFL Thickness

On division topographically, there was some variation between sectors (Fig. 2). The average peripapillary RNFL increased

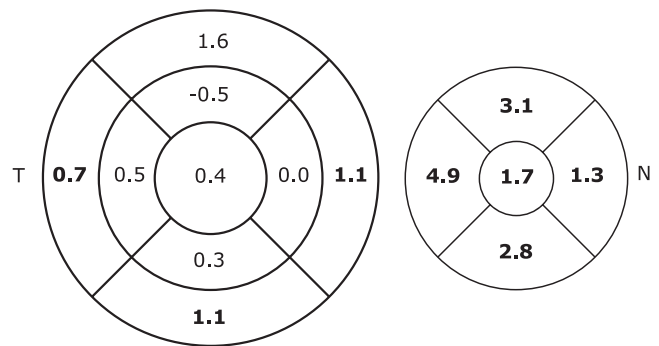


FIGURE 2. Change in RNFL thickness (μm) by macular and peripapillary sectors. Significant values are highlighted in bold.

significantly by 1.7 μm ($T = 7.241$, $P < 0.001$), with similar highly significant increases for all individual quadrants (Table 2). However, there was some variation in the macular EDTRS values, with only external sectors increasing significantly with altitude.

DISCUSSION

HAH is common in the mountain environment, and yet its pathophysiology is poorly understood. At the time of imaging, 12 out of 18 participants included in our analysis were suffering from HAH. In agreement with the literature, the diameters of both the retinal veins and arteries were significantly raised on ascent to high altitude.⁵⁻⁷ Furthermore, a correlation was found between RVD and HAH, evidence that increased pressure in the intracranial venous outflow may be linked to the development of headache at altitude. In capturing images soon after arrival at Margherita a lag was avoided between attaining a new altitude and taking measurements that Willmann et al.⁷ felt to be a shortcoming of previous studies. Finally, we found no significant effect of acetazolamide on either the retinal vasculature or layers. However, as there was no correlation between acetazolamide and either HAH or AMS it seems likely that the drug was not having a significant impact clinically.

OCT retinal segmentation has been used to study the effect of systemic hypoxia on the different layers of the retina. In agreement with Tian et al.¹² a significant increase was found in the thickness of the innermost layers, the RNFL and GCL. The largest retinal vessels run through the RNFL and the GCL as part of the superficial vascular plexus, with the RNFL additionally supplied by the radial peripapillary capillary plexus.¹⁶ This gives these layers the greatest vascular density of the retina¹⁷ and vascular expansion would therefore be

TABLE 1. Change of Thickness in Whole and Segmented Macula With Altitude (T Statistic From Repeat Measures t -test) and Between Intervention Groups (F Statistic From ANCOVA Included). The T Statistic From the Repeat Measures RNFL, GCL, IPL, INL, OPL, ONL, RPE

Layer	Mean Change, μm (%)	Altitude		Drug	
		T	P	F	P
Retina	1.0 (0.3)	1.665	0.114	0.003	0.960
RNFL	0.6 (2.1)	2.828	0.012	0.174	0.683
GCL	0.7 (1.5)	2.909	0.010	0.082	0.778
IPL	0.3 (0.7)	1.712	0.105	1.785	0.201
INL	-0.3 (-0.9)	-1.391	0.182	0.300	0.592
OPL	0.6 (2.2)	2.125	0.049	1.405	0.254
ONL	-0.0 (0.0)	-0.034	0.973	1.081	0.315
RPE	-0.3 (-2.0)	-1.617	0.124	0.599	0.451

TABLE 2. Topographic Distribution of Changes in RNFL Thickness in the Macular and Peripapillary Sectors

Sector	Mean Change, μm (%)	<i>T</i>	<i>P</i>
Internal macula sectors			
Central	0.4 (3.7)	1.279	0.218
Superior	-0.5 (-2.1)	-0.890	0.386
Nasal	0.0 (0.0)	0.000	0.998
Inferior	0.3 (2.2)	0.551	0.589
Temporal	0.5 (3.2)	1.932	0.070
External macula sectors			
Superior	1.6 (4.2)	2.479	0.024
Nasal	1.1 (2.4)	3.162	0.006
Inferior	1.1 (2.8)	3.688	0.002
Temporal	0.7 (3.9)	2.749	0.014
Peripapillary sectors			
Global	1.7 (2.3)	7.241	<0.001
Superior	3.1 (2.4)	4.499	<0.001
Nasal	1.3 (1.7)	4.346	<0.001
Inferior	2.8 (2.7)	4.600	<0.001
Temporal	4.9 (3.8)	7.770	<0.001

T statistic from repeat measures *t*-test.

expected to increase the thickness of these layers in particular. This is supported by the fact that when divided by EDTRS grid the greatest increases in the RNFL thickness were found in those sectors closest to the paths of large vessels (i.e., peripapillary and external superior and inferior).

The retina also contains two other capillary plexuses, the intermediate and deep, found in the adjacent border territories of the inner plexiform layer/inner nuclear layer (IPL/INL) and INL/OPL, respectively.¹⁶ However, these layers did not see any significant change with altitude, with a trend to expansion seen in the OPL found to be nonsignificant after post hoc correction and no significant changes found in the INL or IPL. The reason for this may be the low vascular density of these layers relative to the RNFL and GCL.^{16,17} Hirano et al.¹⁷ showed that the INL in particular has an extremely low vascular density relative to the innermost layers, explaining the absence of vascular expansion. The use of OCT angiography in future studies may help to understand selective microvascular compartment expansion at altitude.

Another difference is the glial populations, with the inner layers densely packed with astrocytes and the outer layers much more dependent on Müller cells.^{13,18} In development, astrocytes are thought to migrate into the retina alongside the retinal blood supply, meaning the vasculature and glial populations are highly correlated¹². Müller cells are less susceptible than astrocytes to hypoxia due to a reliance on glycolysis for ATP production.^{19,20} In vivo studies, using pattern electroretinography, have also shown the inner layers of the retina to be more susceptible to systemic hypoxia.²¹ For this reason, the glia of the RNFL and GCL may undergo a degree of cytotoxic swelling not experienced in the outer layers. This is of particular interest in HAH and AMS as cerebral diffusion weighted imaging studies in hypoxic subjects have shown a correlation between symptoms and reduced water movement, a change likely to represent cytotoxic edema.^{22,23} Astrocytic swelling, thought to occur through metabolic failure of the Na⁺/K⁺ ATPase, is a common feature of cerebral edema.^{24,25} Consequently, an increase in thickness isolated to the astrocyte dense inner retinal layers lends further weight to cerebral parenchymal swelling playing a role in high altitude pathology, potentially through a mechanism of venocompression.⁴

A weakness of this study was the low number of participants with HAH that went on to develop clinically significant AMS, most likely due to a gentle ascent profile. Using HAH alone is problematic, as headaches can be generated through a number of alternative mechanisms when climbing, most importantly dehydration. The current dearth of any truly objective ability to diagnose high altitude cerebral pathology (with the possible exception of high altitude cerebral edema) is a major disadvantage commonly noted in the literature.¹ Although our results contribute to our understanding of HAH, AMS remains a syndrome that cannot be measured objectively.

In conclusion, this study provides further confirmation of the link between RVD and HAH. Furthermore, we demonstrate the first fully segmented analysis of the retina at altitude, showing an expansion isolated to the inner layers likely to represent vascular and glial changes.

Acknowledgments

The authors thank the participants of the Birmingham Medical Research Expeditionary Society expedition to Monte Rosa for their assistance, in particular Charles Hand, Jo Bradwell, and Steve Myers.

Supported by the Jabbs Foundation, a registered UK charity.

Disclosure: **A.K. Clarke**, None; **M. Cozzi**, None; **C.H.E. Imray**, None; **A. Wright**, None; **S. Pagliarini**, None

References

- Willmann G, Gekeler F, Schommer K, Bärtsch P. Update on high altitude cerebral edema including recent work on the eye. *High Alt Med Biol.* 2014;15:112-122.
- Wilson MH, Newman S, Imray CH. The cerebral effects of ascent to high altitudes. *Lancet Neurol.* 2009;8:175-191.
- Wilson MH, Imray CH, Hargens AR. The headache of high altitude and microgravity-similarities with clinical syndromes of cerebral venous hypertension. *High Alt Med Biol.* 2011;12:379-386.
- Sagoo RS, Hutchinson CE, Wright A, et al; Birmingham Medical Research and Expedition Society. Magnetic resonance investigation into the mechanisms involved in the development of high-altitude cerebral edema. *J Cereb Blood Flow Metab.* 2017;37:319-331.
- Bosch MM, Merz TM, Barthelmes D, et al. New insights into ocular blood flow at very high altitudes. *J Appl Physiol.* 1985. 2009;106:454-460.
- Wilson MH, Davagnanam I, Holland G, et al. Cerebral venous system and anatomical predisposition to high-altitude headache. *Ann Neurol.* 2013;73:381-389.
- Willmann G, Fischer MD, Schommer K, Bärtsch P, Gekeler F, Schatz A. Missing correlation of retinal vessel diameter with high-altitude headache. *Ann Clin Transl Neurol.* 2014;1:59-63.
- Chan A, Duker JS, Ishikawa H, Ko TH, Schuman JS, Fujimoto JG. Quantification of photoreceptor layer thickness in normal eyes using optical coherence tomography. *Retina.* 2006;26:655-660.
- Invernizzi A, Pellegrini M, Acquistapace A, et al. Normative data for retinal-layer thickness maps generated by spectral-domain oct in a white population. *Ophthalmol Retina.* 2018; 2:808-815.
- Ctori I, Huntjens B. Repeatability of foveal measurements using Spectralis optical coherence tomography segmentation software. *PLoS One.* 2015;10:e0129005.
- Schallenberg M, Kremmer S, Anastassiou G, Steuhl K, Selbach J. Correlation of retinal vessel analysis and nerve fiber layer

- thickness in normal tension glaucoma. *J Clin Exp Ophthalmol*. 2015;6:2.
12. Tian X, Zhang B, Jia Y, Wang C, Li Q. Retinal changes following rapid ascent to a high-altitude environment. *Eye (Lond)*. 2018;32:370-374.
 13. Vecino E, Rodríguez FD, Ruzafa N, Pereiro X, Sharma SC. Glia-neuron interactions in the mammalian retina. *Prog Retin Eye Res*. 2016;51:1-40.
 14. Lujan BJ, Roorda A, Knighton RW, Carroll J. Revealing Henle's fiber layer using spectral domain optical coherence tomography. *Invest Ophthalmol Vis Sci*. 2011;52:1486-1492.
 15. Early Treatment Diabetic Retinopathy Study Research Group. Grading diabetic retinopathy from stereoscopic color fundus photographs—an extension of the modified Airlie house classification: ETDRS report number 10. *Ophthalmology*. 1991;98(suppl 5):786-806.
 16. Campbell JP, Zhang M, Hwang TS, et al. Detailed vascular anatomy of the human retina by projection-resolved optical coherence tomography angiography. *Sci Rep*. 2017;7:42201.
 17. Hirano T, Chanwimol K, Weichsel J, Tepelus T, Sadda S. Distinct retinal capillary plexuses in normal eyes as observed in optical coherence tomography angiography axial profile analysis. *Sci Rep*. 2018;8:9380.
 18. Ramírez JM, Triviño A, Ramírez AI, Salazar JJ, García-Sánchez J. Structural specializations of human retinal glial cells. *Vision Res*. 1996;36:2029-2036.
 19. Ly A, Yee P, Vessey KA, Phipps JA, Jobling AI, Fletcher EL. Early inner retinal astrocyte dysfunction during diabetes and development of hypoxia, retinal stress, and neuronal functional loss. *Invest Ophthalmol Vis Sci*. 2011;52:9316-9326.
 20. Winkler BS, Arnold MJ, Brassell MA, Puro DG. Energy metabolism in human retinal Müller cells. *Invest Ophthalmol Vis Sci*. 2000;41:3183-3190.
 21. Kergoat H, Hérard ME, Lemay M. RGC sensitivity to mild systemic hypoxia. *Invest Ophthalmol Vis Sci*. 2006;47:5423-5427.
 22. Schoonman GG, Sándor PS, Nirkko AC, et al. Hypoxia-induced acute mountain sickness is associated with intracellular cerebral edema: a 3 T magnetic resonance imaging study. *J Cereb Blood Flow Metab*. 2008;28:198-206.
 23. Hunt JS, Theilmann RJ, Smith ZM, Scadeng M, Dubowitz DJ. Cerebral diffusion and T2: MRI predictors of acute mountain sickness during sustained high-altitude hypoxia. *J Cereb Blood Flow Metab*. 2013;33:372-380.
 24. Rosenblum WI. Cytotoxic edema: monitoring its magnitude and contribution to brain swelling. *J Neuropathol Exp Neurol*. 2007;66:771-778.
 25. Bailey DM, Bärtsch P, Knauth M, Baumgartner RW. Emerging concepts in acute mountain sickness and high-altitude cerebral edema: from the molecular to the morphological. *Cell Mol Life Sci*. 2009;66:3583-3594.