

Trichostatin A Ameliorates Conjunctival Fibrosis in a Rat Trabeculectomy Model

Mi Sun Sung,¹ Gwang Hyeon Eom,² Soo Jin Kim,¹ So Young Kim,¹ Hwan Heo,¹ and Sang Woo Park^{1,3}

¹Department of Ophthalmology and Research Institute of Medical Sciences, Chonnam National University Medical School and Hospital, Gwangju, South Korea

²Department of Pharmacology, Chonnam National University Medical School, Hwasungun, South Korea

³Center for Creative Biomedical Scientists, Chonnam National University, Gwangju, South Korea

Correspondence: Sang Woo Park, Department of Ophthalmology and Research Institute of Medical Sciences, Chonnam National University Medical School and Hospital, 42 Jebong-ro, Dong-gu, Gwangju 61469, South Korea; exo70@naver.com.

Submitted: January 8, 2018

Accepted: May 23, 2018

Citation: Sung MS, Eom GH, Kim SJ, Kim SY, Heo H, Park SW. Trichostatin A ameliorates conjunctival fibrosis in a rat trabeculectomy model. *Invest Ophthalmol Vis Sci.* 2018;59:3115-3123. <https://doi.org/10.1167/iovs.18-23826>

PURPOSE. To investigate whether histone deacetylase (HDAC) activity is associated with postoperative scarring and to evaluate the effect of HDAC inhibition by topical trichostatin A (TSA) on conjunctival fibrosis after trabeculectomy in a rat model.

METHODS. Trabeculectomy was performed on the left eye of Sprague-Dawley rats. In the first experiment, adenoviruses HDAC 1, HDAC 2, and green fluorescent protein were added to the subconjunctival space during trabeculectomy. Expression of α -smooth muscle actin (α -SMA) was evaluated. In the second experiment, rats undergoing trabeculectomy were randomized into control, vehicle control, steroid, 500 nmol/L TSA, and 1 μ mol/L TSA groups. On postoperative day 14, bleb vascularity, toxic effect of topical TSA on corneal epithelium, expression of α -SMA, transforming growth factor (TGF)- β 1, and phosphorylated-Smad2/3 and the infiltration of CD45⁺ cells were determined. Masson's trichrome staining and immunofluorescence staining for α -SMA and CD45 were also performed.

RESULTS. Overexpression of HDAC1 contributed to accelerated conjunctival fibrosis after trabeculectomy. HDAC inhibition by topical administration of 1 μ mol/L TSA significantly decreased bleb vascularity, leukocyte infiltration, and expression of α -SMA and TGF- β 1 in the conjunctiva. Its effectiveness on conjunctival fibrosis was comparable to that of topical steroid. Masson's trichrome staining showed decreased collagen deposition in the bleb tissues of steroid and 1 μ mol/L TSA treatment groups. Topical TSA did not have any toxic effect on the corneal epithelium.

CONCLUSIONS. HDAC activity is involved in postoperative conjunctival fibrosis. HDAC inhibition by topical administration of TSA eye drops is a safe and effective therapeutic modality to modulate wound healing after trabeculectomy.

Keywords: histone deacetylase inhibitor, trichostatin A, fibrosis, trabeculectomy

Glaucoma is a leading cause of blindness.¹ Reducing the intraocular pressure (IOP) is the only effective therapy for preventing visual impairment in patients with glaucoma.^{2,3} Although medical therapies for IOP reduction have improved tremendously over the past 10 to 15 years and have become the first-line treatment for glaucoma, many patients eventually need another therapeutic option for IOP reduction, such as glaucoma filtration surgery. Among the glaucoma filtration surgeries, trabeculectomy is the most preferred option for patients who do not respond adequately or are intolerant to topical IOP-lowering eye drops.

The aim of performing trabeculectomy is to create a permanent drainage outflow channel for the aqueous humor, connecting the anterior chamber to the sub-Tenon's space. However, the IOP may not reduce because of scarring at the site of the new drainage channel. Postoperative fibrosis remains the major impediment to higher success rates of trabeculectomy.⁴⁻⁷ To improve surgical outcome, postoperative topical steroids and intraoperative wound healing modulators, such as mitomycin C (MMC) or 5-fluorouracil (5-FU) are frequently used in clinical practice. However, the effects of these

compounds are insufficient. In addition, they could potentially lead to complications, such as steroid-induced IOP elevation, bleb infection and leakage, hypotony, or endophthalmitis.⁸⁻¹¹ These complications might occur because these agents are relatively nonspecific. They not only inhibit postoperative fibrosis, but also affect the normal conjunctiva or sclera tissue, leading to widespread cell death and apoptosis. Therefore, the development of a new therapeutic modality for the wound healing process after trabeculectomy is essential.

Histone deacetylases (HDACs) are a family of enzymes that remove acetyl groups from ϵ -N-acetyl lysine amino acids on a histone, thereby modulating gene expression.¹² Recent studies have shown that HDACs are critically involved in tissue fibrosis in multiple organs, including the kidney, heart, and lung.¹³⁻¹⁶ A growing body of evidence supports the use of HDAC inhibitors for treating various fibrotic disorders. However, until recently, little was known about the role of HDACs in regulating conjunctival fibrosis. In this study, we examined whether HDAC activity is associated with postoperative conjunctival fibrosis after trabeculectomy in a rat model. Furthermore, we



also evaluated the effect of HDAC inhibition by trichostatin A (TSA) on conjunctival scarring after trabeculectomy.

MATERIALS AND METHODS

Animal Use

All experiments were conducted in accordance with the ARVO Statement for the Use of Animals in Ophthalmic and Vision Research. The protocol was approved by the Institutional Animal Care and Use Committee of Chonnam National University Hospital. Sprague-Dawley rats, each weighing 245 to 255 g, were individually housed under controlled lighting conditions (12-hour light/12-hour dark) and were given tap water and food ad libitum throughout the duration of the study.

Rat Model of Trabeculectomy

Trabeculectomy surgery was performed as described previously.^{17,18} All surgeries were performed on the left eye only. Rat anesthesia was administered by intramuscular injection of a mixture of tiletamine/zolazepam (20 mg/kg; Zoletil 50; Virbac, Nice, France) combined with xylazine hydrochloride (5 mg/kg; Rompun; Bayer Korea, Seoul, Korea). Additional topical anesthesia was provided in the form of 0.5% proparacaine hydrochloride drops (Alcaine; Alcon, Fort Worth, TX, USA). A sterile lid speculum was placed in the eye and the globe was rotated inferiorly by an assistant. A superior fornix-based conjunctival flap was created from the 10 o'clock to the 2 o'clock position. The underlying Tenon's capsule was opened, and dissection was continued to 3 to 4 mm behind the limbus using blunt scissors. No antimetabolites were applied. After paracentesis, viscoelastic (Hyalu injection 1.5%; Hanmi Pharmaceutical, Seoul, Korea) was then injected through a 30-gauge needle to maintain the anterior chamber. A full-thickness scleral tunnel was created using a 27-gauge needle, which was inserted into the anterior chamber. The conjunctiva and Tenon's capsule were closed using a nonabsorbable 10-0 nylon suture at each end of the peritomy in a water-tight fashion. After the surgical procedure, a single drop of antibiotic ointment containing ofloxacin (Ocuflox Eye Ointment; Samil Pharmaceutical, Seoul, Korea) was instilled in all eyes. Topical antibiotic eye drops (Ocuflox Eye Drop; Samil Pharmaceutical) and antibiotic ointment were applied four times a day for 14 days postoperatively.

Adenoviral Green Fluorescent Protein (GFP), HDAC1, and HDAC2

Before investigating the therapeutic effect of TSA eye drops, we performed another set of experiments to evaluate whether HDAC activity was associated with conjunctival fibrosis after trabeculectomy in a rat model. HDAC1 and HDAC2 adenoviruses, purchased from Applied Biological Materials (Richmond, BC, Canada), were used for overexpressing HDAC1 and HDAC2, respectively. Adenoviral GFP was used as a control vector. Adenoviral GFP was also used to confirm the efficacy of gene transfer. Three microliters of viral solution (1×10^{10} pfu) were dropped into the subconjunctival space after conjunctival dissection during the trabeculectomy. Adenoviral titer was determined using the Adeno-X Rapid Titer kit (Clontech Laboratories, Mountain View, CA, USA). In this experiment, the rats were divided into five groups: (1) normal group, (2) control group that underwent trabeculectomy without viral solution, (3) adenoviral GFP group, (4) adenoviral HDAC1 group, and (5) adenoviral HDAC2 group. Control, adenoviral GFP, adenoviral HDAC1, and adenoviral HDAC2 groups

received topical antibiotic eye drops four times a day until the end of the experiment. All rats were euthanized on postoperative day 14.

Treatment Regimen and Preparation of TSA Eye Drops

Twenty-five rats who underwent trabeculectomy were randomized into five experimental groups as follows: (1) control group that received only topical antibiotic eye drops, (2) vehicle control group that received topical vehicle solution and antibiotic eye drops, (3) steroid group that received 0.1% topical fluorometholone (Ocumetholone; Samil Pharmaceutical) and antibiotic eye drops, (4) 500 nmol/L TSA group that received topical 500 nmol/L TSA and antibiotic eye drops, and (5) 1 μ mol/L TSA group that received topical 1 μ mol/L TSA and antibiotic eye drops. Rats in the normal group that were not operated on received no eye drops. A 10 mmol/L stock solution of TSA (Sigma-Aldrich Corp., St. Louis, MO, USA) was prepared by dissolving TSA in dimethyl sulfoxide (DMSO) and then further diluting it to 500 nmol/L or 1 μ mol/L with balanced salt solution (BSS; Alcon). These dosages were determined by a previous study and our pilot experiments.¹⁹ For the vehicle control, 0.01% DMSO diluted with BSS was used. All eye drops were administered topically to the operated eyes of unanesthetized rats four times a day until the end of the experimental period. All rats were euthanized on postoperative day 14. The experiments were performed on three independent sets of rats.

Clinical Evaluation

Clinical evaluation was performed to evaluate the toxic effect of topical TSA on corneal epithelium and bleb vascularity using slit-lamp biomicroscopy (BQ-900; Haag-Streit, Bern, Switzerland) with concomitant photographic documentation. All these clinical measurements were recorded on postoperative day 1 and 14. Corneal fluorescein staining analyses were performed as previously described.²⁰ Briefly, 1 μ L 1% sodium fluorescein was dropped into the inferior conjunctival sac using a micropipette, and then punctate staining on the corneal surface was evaluated in a blinded fashion. Each cornea was divided into four quadrants that were scored individually. The corneal fluorescein staining score was calculated using a four-point scale: 0 = absent; 1 = slight punctate staining <30 spots; 2 = punctate staining >30 spots, but not diffuse; 3 = severe diffuse staining but no positive plaque; and 4 = positive fluorescein plaque. The four scores were added to generate a final grade. Bleb vascularity was graded as 0 = avascular, 1 = normal vascularity, 2 = hyperemic, and 3 = very hyperemic.²¹

Quantitative Real-Time Polymerase Chain Reaction (RT-PCR)

The mRNA expression of genes encoding α -smooth muscle actin (α -SMA) and transforming growth factor (TGF)- β 1, was evaluated by RT-PCR. Quantitative PCR was performed on the bleb tissues excised from the surgical site at postoperative day 14. Total RNA from the tissues was extracted using TRIzol reagent (Invitrogen, Grand Island, NY, USA). cDNA was synthesized using an iScript cDNA Synthesis Kit (Bio-Rad Laboratories, Hercules, CA, USA) and analyzed by RT-PCR with QuantiTect SYBR Green RT-PCR Master Mix (Qiagen, Valencia, CA, USA) using the Rotor-Gene Q (Qiagen, Hilden, Germany). The primer sequences used for PCR were as follows: α -SMA, 5'-ACTGGGACGACATGGAAAAG-3' (forward), 5'-CATCTCCAGAGTCCAGCACA-3' (reverse); TGF- β 1, 5'-ATGACATGAACCGACCCTTC-3' (forward), 5'-ACTTCCAACCCAGGTCTTC-3'

(reverse). All data were normalized to the expression of 18S rRNA.

Western Blot Analysis

The bleb tissues were homogenized in a glass-teflon Potter homogenizer in lysis buffer (PRO-PREP; iNtRoN Biotechnology, Seoul, Korea). Each sample (10 μ g) was separated on a 10% polyacrylamide minigel. After protein transfer, the membranes were blocked for 1 hour at room temperature in Tris-buffered saline with Tween-20 solution (TBS-T; 10 mmol/L Tris-HCl [pH 7.6], 150 mmol/L NaCl, and 0.1% Tween-20) containing 5% nonfat dry milk. After blocking, the membranes were incubated overnight at 4°C with a primary antibody against Smad2/3 (1:1000), phosphorylated-Smad2/3 (p-Smad2/3; 1:1000), or β -actin, all of which were obtained from Cell Signaling Technology (Danvers, MA, USA). After three washes with TBS-T, the membranes were incubated for 1 hour at room temperature with a peroxidase-conjugated goat anti-rabbit secondary antibody (1:3000; Cell Signaling Technology). Signals were visualized by enhanced chemiluminescence and quantified using an LAS-3000 image analyzer (Fujifilm, Tokyo, Japan).

Histologic Examination

On postoperative day 14, rats were humanely euthanized under general anesthesia. The eye was enucleated together with the conjunctiva to preserve the bleb. The upper lid was left intact, attached to the globe to preserve the architecture of the superior fornix and conjunctival tissues around the drainage site. Samples were embedded in optimum cutting temperature compound and frozen at -80°C prior to cryosectioning. The 12 o'clock position of the limbus was identified with a marking pen prior to administration of anesthesia, and all the histological examinations were performed on the marking site, which is the center of the bleb tissue. The tissues were cut into 7- μ m thick sections and Masson's trichrome staining was performed to observe the fibrous tissue and collagen fibers, according to the manufacturer's protocol. Sections from each group were examined and photographed under a microscope (Olympus, Tokyo, Japan) equipped with a digital camera. Immunofluorescence staining for α -SMA was performed with anti α -SMA antibody (ab5694; Abcam, Cambridge, MA, USA). Inflammation was analyzed by immunohistochemical staining for CD45 using anti-mouse CD45 antibody (1/150; ab10558; Abcam). Sections were incubated with a primary antibody, followed by incubation with Alexa Fluor 488-conjugated goat anti-mouse IgG secondary antibody (Thermo Fisher Scientific, Waltham, MA, USA) for 1 hour. Next, the slides were mounted with a medium containing 4',6-diamidino-2-phenylindole dihydrochloride (DAPI). Fluorescent images of the sectioned tissues were acquired by confocal microscopy using a laser scanning microscope (LSM 510; Carl Zeiss Microscopy, Peabody, MA, USA).

The percentages of collagen- and α -SMA-positive areas over the total bleb area were measured using ImageJ software (National Institutes of Health, Bethesda, MD, USA). The total bleb area was defined based on the appearance of the conjunctiva after hematoxylin/eosin staining of the adjacent slide sections, and the space between the conjunctival epithelium and sclera was measured.²² The proportion of positive pixel area over total bleb area was calculated. Quantification of leukocyte infiltration was performed by calculating the number of CD45⁺ cells in the total bleb area. All quantification data were averaged for three to four representative samples per eye.

Statistical Analysis

Data were expressed as mean \pm standard error of the mean. Analyses were carried out using the SPSS software version 19.0 for Windows (SPSS, Inc., Chicago, IL, USA). One-way analysis of variance (ANOVA) with the appropriate least significant difference (LSD) post hoc test was used to compare experimental groups. Wilcoxon's signed-rank test was used to compare the corneal fluorescein staining score on postoperative day 1 and 14. A probability value of $P < 0.05$ was considered statistically significant.

RESULTS

Overexpression of HDAC1 Exacerbates Postoperative Conjunctival Fibrosis

To determine whether HDAC activity affects conjunctival fibrosis after trabeculectomy, we overexpressed HDAC1 and HDAC2 by adenoviral transduction and evaluated the mRNA levels of α -SMA. The degree of collagen deposition in the bleb tissue was assessed by Masson's trichrome staining on postoperative day 14. α -SMA is a marker for myofibroblasts. Myofibroblasts rarely exist in the normal conjunctiva, and mainly originate from the transdifferentiation of resident fibroblasts in the Tenon's tissue in response to fibrogenic stimuli, such as surgery. The myofibroblastic phenotype is marked by α -SMA expression, as well as secretion of collagen and other proteins. Therefore, α -SMA is commonly discussed as a marker of fibrosis. As reported previously, upon observation, almost all cells were effectively infected with adenovirus.²³ We found that trabeculectomy significantly increased the expression of α -SMA mRNA, and overexpression of HDAC1 significantly exacerbated the surgically induced elevation of α -SMA mRNA. The expression of α -SMA mRNA was higher in the eyes applied with adenoviral HDAC1 compared to that in control eyes and eyes applied with adenoviral HDAC2 and GFP (Fig. 1A). Masson's trichrome staining showed that the control surgical site comprised thick strands of collagen material in the subconjunctival space overlying the sclera. Eyes applied with adenoviral HDAC1 showed more dense and tightly packed connective tissue in the bleb area (Figs. 1B, 1C).

HDAC Inhibitor Treatment Attenuates Conjunctival Fibrosis in a Rat Trabeculectomy Model

Effect of TSA on postoperative wound healing was evaluated on day 14. In the control and vehicle control groups, densely packed collagen fibers were observed, whereas collagen deposition was notably decreased in the steroid- and 1 μ mol/L TSA-treated eyes. Eyes treated with topical 500 nmol/L TSA did not show a significant decrease in collagen deposition compared to those treated with topical antibiotic eye drops (control group) (Figs. 2A, 2B).

RT-PCR results showed that the expression of α -SMA mRNA was significantly increased after trabeculectomy, and this increase was inhibited by steroid and 1 μ mol/L TSA treatment. However, treatment with a lower concentration of TSA (500 nmol/L) exerted no significant effect on trabeculectomy-induced increase in α -SMA expression. There was no significant difference in the expression of α -SMA mRNA between the steroid and 1 μ mol/L TSA groups ($P = 0.65$; Fig. 3A). Immunofluorescence staining of α -SMA revealed a similar pattern of α -SMA mRNA expression as that obtained by RT-PCR analysis (Figs. 3B, 3C).

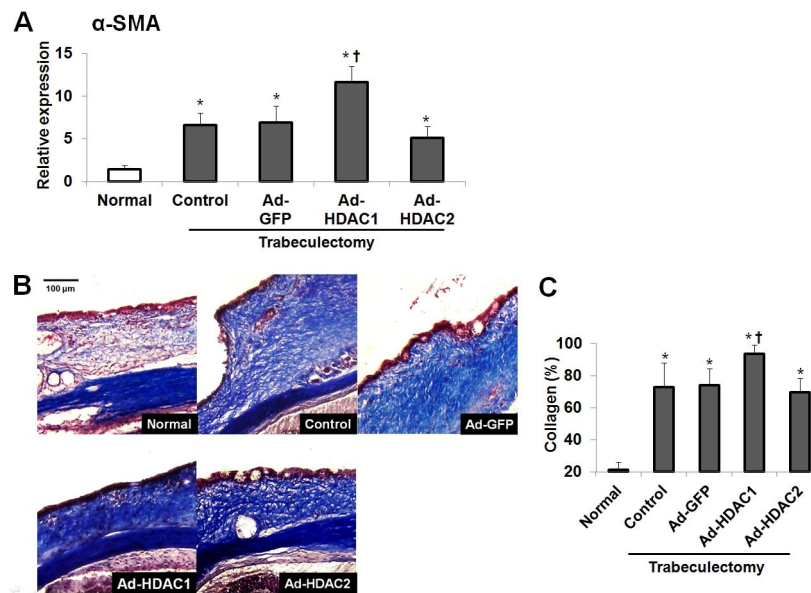


FIGURE 1. Effects of HDAC1 and HDAC2 overexpression on the expression of α -SMA mRNA and collagen density. HDAC1 or HDAC2 adenoviruses were added into the subconjunctival space after conjunctival dissection during trabeculectomy to induce overexpression of HDAC1 or HDAC2, respectively. (A) The bleb tissues were evaluated by RT-PCR. A significant elevation of α -SMA mRNA was observed in all groups that underwent trabeculectomy ($P < 0.05$). Eyes applied with Ad-HDAC1 showed increased expression of α -SMA compared to that observed in control eyes ($P < 0.05$). (B, C) Masson's trichrome staining showed that overexpression of HDAC1 significantly increased collagen density in the bleb tissue in comparison to the control group. * $P < 0.05$ compared to the normal group. † $P < 0.05$ compared to the control group. Ad, adenoviral.

Evaluation of Bleb Vascularity

Increased bleb hyperemia and vascularity are associated with surgical failure. Therefore, we additionally evaluated bleb vascularity. Slit-lamp examination of the conjunctiva blebs on postoperative day 14 showed increased vascularity in the control group. The vehicle control and 500 nmol/L TSA-treated groups also exhibited hypervascular blebs. Steroid and 1 μ mol/L TSA treatment significantly ($P < 0.05$) attenuated bleb vascularity after trabeculectomy. No significant difference in bleb vascularity was found between the steroid and 1 μ mol/L TSA groups ($P = 0.32$; Figs. 4A, 4B).

Anti-inflammatory Effect of HDAC Inhibition

Immunohistochemistry of the bleb sections showed that CD45⁺ cell infiltration was suppressed in both steroid and TSA groups as compared to that in control and vehicle control groups. CD45, present on the surface of nucleated cells, including B cells, T cells, neutrophils, and macrophages, is commonly used as a marker to assess inflammation. The anti-inflammatory effect was more pronounced in the steroid and 1 μ mol/L TSA groups than in the 500 nmol/L TSA group (Figs. 5A, 5B).

HDAC Inhibition Inhibits TGF- β 1-mediated Smad2/3 Signaling

As shown in Figure 6A, trabeculectomy resulted in increased expression of TGF- β 1 mRNA in the bleb tissue. Steroid and 1 μ mol/L TSA eye drop treatment significantly inhibited the surgically induced increase in TGF- β 1 expression. We further performed western blot analysis to analyze the protein levels of Smad2/3 and p-Smad2/3, which are key members of the TGF- β 1/Smad pathway. There was no difference in Smad2/3 expression between the six experimental groups (Figs. 6B, 6C). However, trabeculectomy induced a strong increase in

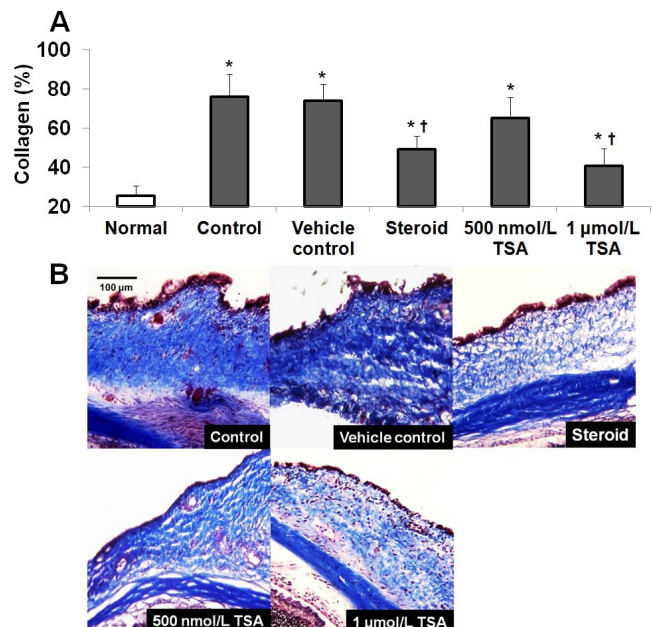


FIGURE 2. Masson's trichrome staining of the bleb tissues. The bleb tissues were collected at day 14 after trabeculectomy. Prominent collagen deposition was observed in the control group, whereas decreased collagen deposition with loosely arranged fibers was observed in the topical steroid- and 1 μ mol/L TSA-treated eyes. Eyes treated with vehicle solution and topical 500 nmol/L TSA did not show a prominent decrease in collagen deposition compared to the control group. (A) Percentage of collagen-positive area over the total bleb was calculated. (B) Representative images of collagen distribution in the bleb tissue. * $P < 0.05$ compared to the normal group. † $P < 0.05$ compared to the control group.

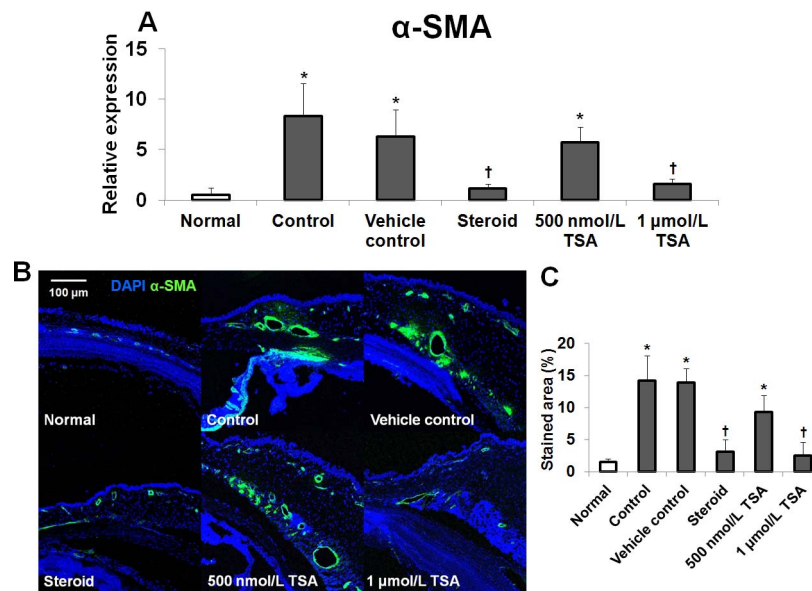


FIGURE 3. Expression of α -SMA mRNA and representative photomicrographs of immunofluorescence staining using anti- α -SMA antibody in the bleb tissue. (A) Expression of α -SMA mRNA was significantly higher in the control group compared to that in the normal group. Steroid or 1 μ mol/L TSA treatment significantly suppressed the elevation of α -SMA mRNA expression after trabeculectomy. The vehicle control and 500 nmol/L TSA groups did not show significant changes in α -SMA expression compared to that in control group. (B, C) Sagittal sections from the conjunctival blebs stained for α -SMA (green) and counterstained with DAPI (blue) showed a significant decrease in α -SMA expression in the steroid- and 1 μ mol/L TSA-treated groups compared to that in control group. * $P < 0.05$ compared to the normal group. † $P < 0.05$ compared to the control group.

Smad2/3 phosphorylation in the bleb tissue. The increase in p-Smad2/3 levels induced by TGF- β 1 was decreased in the steroid and 1 μ mol/L TSA groups (Figs. 6B, 6D).

Corneal Epithelial Toxicity of TSA Eye Drops

To investigate the safety of TSA eye drop treatment, the corneal fluorescein staining scores were evaluated on postoperative day 14. Corneal fluorescein staining is a diagnostic tool to assess the integrity of superficial epithelial cell layers of the cornea and is commonly used as a marker of drug toxicity in ophthalmology.²⁴ However, surgical procedures, such as trabeculectomy itself can cause corneal epithelial damage. Surgery-induced epithelial damage is more severe in the early days after surgery than in the late postoperative period. Therefore, we additionally evaluated the corneal epithelium on postoperative day 1. In this study, significantly severe corneal damage was observed in all operated eyes compared to that in normal eyes on both postoperative days 1 and 14. The fluorescein staining score 1 day after surgery was significantly higher than that of 14 days after surgery. However, there were no statistically significant differences in the mean corneal fluorescein staining scores between the five operated groups on postoperative day 1 and 14 (Fig. 7).

DISCUSSION

In this study, we first showed that HDAC1 overexpression exacerbated conjunctival fibrosis after trabeculectomy in a rat model. We also demonstrated that inhibiting HDAC by topical administration of TSA decreased the transdifferentiation of myofibroblasts, thereby inhibiting postoperative conjunctival fibrosis. Our finding suggests that TSA eye drops can be used as a potential agent for postoperative wound healing modulation to increase the success of glaucoma surgery.

Fibrogenesis is recognized as a major cause of surgical failure after glaucoma filtration surgery. However, the availabil-

ity of treatments to prevent scar formation is limited. Among the several tools available, steroid eye drops are most commonly and widely used after glaucoma filtration surgery, but they are effective only at the early inflammatory stage of fibrosis and are associated with an increased risk of bleb

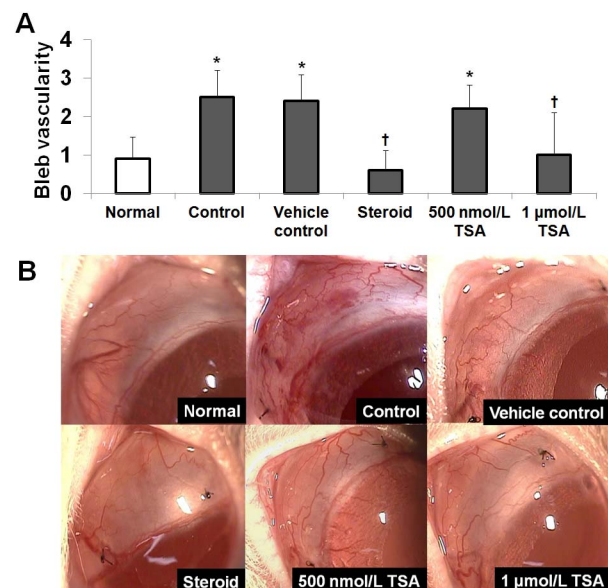


FIGURE 4. Comparison of bleb vascularity and representative slit-lamp anterior segment photographs captured at postoperative day 14. (A) Bleb vascularity grading showed that the control, vehicle control, and 500 nmol/L TSA-treated groups similarly exhibited hypervascular blebs. Steroid and 1 μ mol/L TSA treatment significantly ($P < 0.05$) attenuated bleb vascularity after trabeculectomy. There was no difference in bleb vascularity between the steroid and 1 μ mol/L TSA groups. (B) A significant decrease in bleb vascularity was observed in steroid- and 1 μ mol/L TSA-treated eyes after trabeculectomy. * $P < 0.05$ compared to the normal group. † $P < 0.05$ compared to the control group.

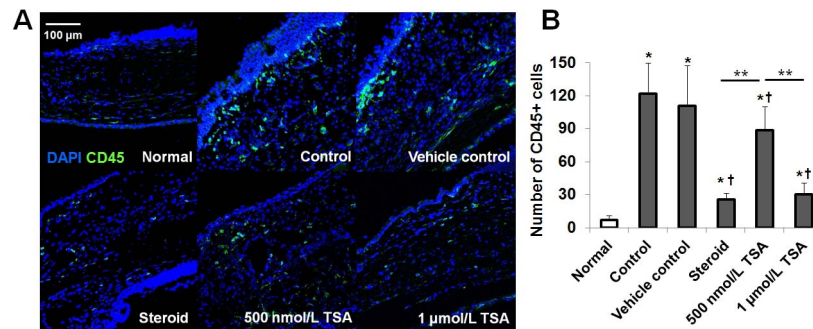


FIGURE 5. CD45⁺ cell infiltration in the bleb tissue at postoperative day 14. **(A, B)** Sagittal sections from the conjunctival blebs stained for CD45 (green) and counterstained with DAPI (blue) showed a significant decrease in CD45⁺ cell infiltration in the steroid-, and 500 nmol/L TSA-, and 1 μmol/L TSA-treated groups compared to that in the control group. The anti-inflammatory effect was more pronounced in the steroid- and 1 μmol/L TSA-treated groups than in the 500 nmol/L TSA-treated group. **P* < 0.05 compared to the normal group. †*P* < 0.05 compared to the control group. ***P* < 0.05 compared to the 500 nmol/L TSA group.

infection. Adjunctive agents, such as MMC or 5-FU, with an anti-proliferative effect, are other tools to prevent scar formation, but since these agents do not specifically target fibrogenesis, they also impose a risk of severe sight-threatening side effects. These problems have stimulated the search for alternative modalities that can modulate wound healing, and numerous agents have been tested.^{21,25-34} Recently, Clinik et al.³⁴ demonstrated the antifibrotic efficacy of everolimus, the immunosuppressive and antiproliferative macrolide, in a rabbit model of trabeculectomy. However, because of their toxicity, almost all such agents must be administered through the subconjunctival route during surgery. Several studies have investigated the antifibrotic effect of topical eye drops.^{30,32,33} Topical administration of agents using eye drops is not only safe, but potentially eliminates the need for subconjunctival injection and can be used long-term, thereby modulating the late stage of fibrosis. Therefore, in this study, we attempted to develop a new antifibrotic eye drop formula.

HDACs are a family of enzymes consisting of 18 members classified into four classes, including class I (HDACs 1-3 and 8), class II (HDACs 4-7 and 9-10), class III (SIRT1-7), and class IV (HDAC11), based on their function and sequence homology.³⁵

Among the various HDACs, class I HDACs are widely expressed and well-known to be associated with tissue fibrosis.³⁶⁻³⁹ Particularly, HDAC1 and HDAC2 are reported to be the major HDACs involved in the fibrosis process. Recently, HDAC1 and HDAC2 have been shown to play significant roles in cardiac hypertrophy and function.^{36,37} Other studies have reported that HDAC1 and HDAC2 have profibrotic roles in renal injury disease models.^{38,39} In the present study, we observed a significant increase in the level of α-SMA and collagen deposition in rats with HDAC1 overexpression. Our finding suggests that HDAC1 plays a role in postoperative conjunctival fibrosis. Notably, we found that HDAC2 overexpression had no effect on α-SMA mRNA expression and collagen density after surgery. Considering that HDAC1 and HDAC2 share 83% amino acid homology and there is a high degree of functional redundancy between these two proteins, this result represents a very interesting finding, indicating the distinct function of the two enzymes in the conjunctival tissue.

Given the important role of HDACs in fibrosis, there has been an increasing interest in HDAC inhibitor-based therapeutic approaches. However, despite a great amount of research investigating the antifibrotic effect of HDAC inhibitors in

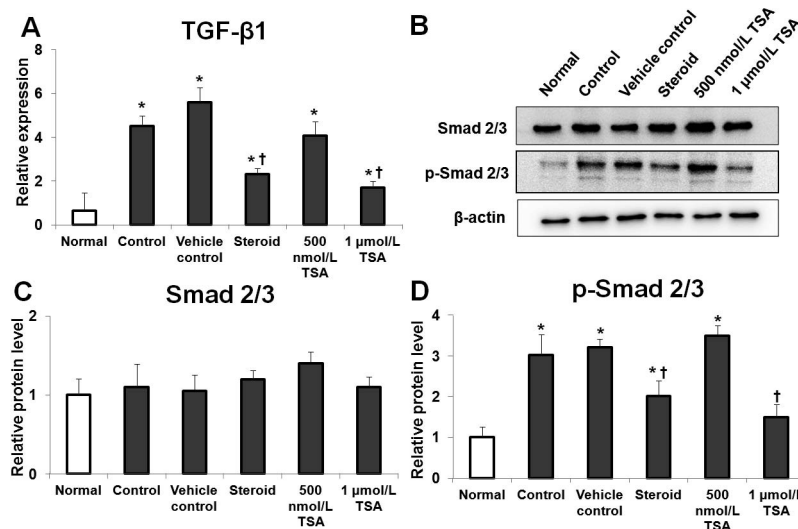


FIGURE 6. Expression of TGF-β1 mRNA and Smad2/3 and p-Smad2/3 proteins in the bleb tissue at postoperative day 14. **(A)** The expression of TGF-β1 mRNA was significantly increased after trabeculectomy compared to that in the normal group. The expression of TGF-β1 mRNA was decreased in the steroid and 1 μmol/L TSA groups compared to that in the control group. **(B-D)** Expression of Smad2/3 and p-Smad2/3 proteins was assessed by western blotting. Western blot analysis revealed decreased expression of p-Smad2/3 protein by 1 μmol/L TSA treatment. **P* < 0.05 compared to the normal group. †*P* < 0.05 compared to the control group.

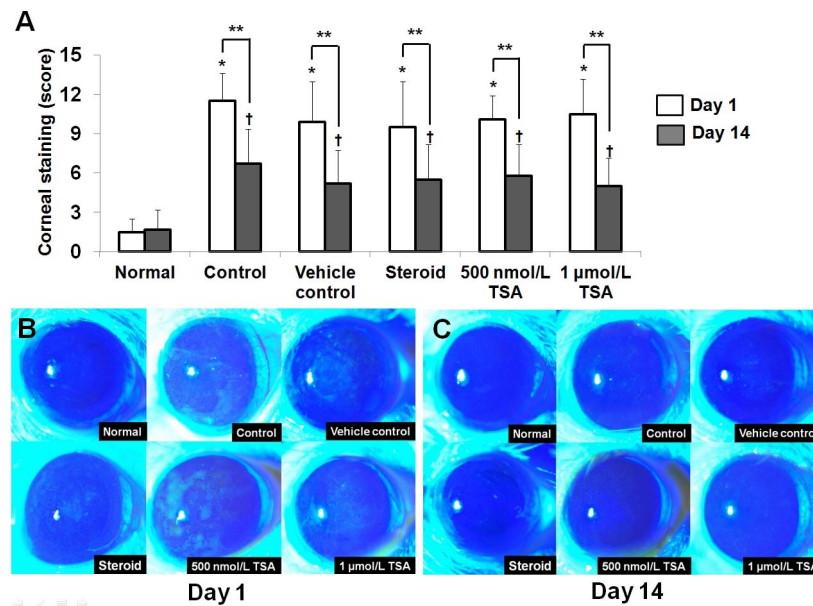


FIGURE 7. Comparison of corneal fluorescein staining scores on postoperative day 1 (A, B) and 14 (A, C). All operated eyes demonstrated significantly more severe corneal epithelial staining compared to that in normal eyes. No significant differences were found between the five operated groups. * $P < 0.05$ compared to the normal group at postoperative day 1. † $P < 0.05$ compared to the normal group at postoperative day 14. ** $P < 0.05$ compared to day 1.

various fibrotic diseases, little is known about the role of HDAC inhibitors in conjunctival fibrosis. Previously, Kitano et al.¹⁹ investigated the antifibrotic effect of TSA on cultured subconjunctival fibroblasts in vitro. Recently, Sharma et al.²⁶ tested another HDAC inhibitor, suberoylanilide hydroxamic acid (SAHA), in an in vivo study by subconjunctival injection, and reported that SAHA effectively reduced collagen deposition at the sclerotomy site. In this study, we used a potent HDAC inhibitor, TSA, for modulating postoperative fibrosis, and found that the antifibrotic efficacy of 1 μmol/L TSA eye drops was high and comparable to that of steroid eye drops, which are a well-known and effective modality for modulating postoperative wound healing. To the best of our knowledge, this is the first study to compare the therapeutic efficacy of new antifibrotic agents and steroid eye drops.

TSA is a potent nonselective HDAC inhibitor with a Ki value of 3.4 nmol/L, which inhibits class I and class II HDACs and induces histone acetylation. It was derived from *Streptomyces hygroscopicus* as an antifungal antibiotic and was found to be the first natural hydroxamic acid to inhibit HDACs. It inhibits HDAC reversibly by chelating zinc at the active site of HDAC with its hydroxamic acid group. Although TSA has not yet been clinically approved as a therapeutic drug for the treatment of fibrotic diseases, it has been extensively studied and found to have important applications in different forms of fibrotic diseases. For example, in animal models of bleomycin-induced pulmonary fibrosis, TSA treatment prevented and inhibited pulmonary fibrosis.⁴⁰ Pang et al.⁴¹ demonstrated that administration of TSA attenuates renal fibrosis in mice with obstructive nephropathy. It has also been reported that TSA effectively inhibits the epithelial-mesenchymal transition of hepatic stellate cells and abrogates TGF-β1-induced fibrosis-related gene expression in skin fibroblasts.^{42,43}

In line with previous studies,⁴⁰⁻⁴³ Masson's trichrome staining results showed that extensive collagen deposition after trabeculectomy was reduced in the 1 μmol/L TSA-treated group. Treatment with 1 μmol/L TSA eye drops also suppressed the expression of α-SMA mRNA. In contrast, eye drops containing a lower concentration of TSA (500 nmol/L) did

not significantly reduce postoperative fibrosis. This finding is inconsistent with that of a previous in vitro study by Kitano et al.¹⁹ that demonstrated a high antifibrotic efficacy of 500 nmol/L TSA in ocular fibroblasts. This difference in efficacy between the two concentrations of TSA eye drops might be explained by the bioavailability of topical formulations.⁴⁴ First, precorneal factors, including solution drainage, blinking, tear film, tear turnover, and induced lacrimation negatively affect topical drug bioavailability. In addition, conjunctival blood capillaries and lymphatics might cause significant drug loss into the systemic circulation.

HDAC inhibitors have also been shown to reduce angiogenesis. Although the molecular mechanisms underlying the antiangiogenic effect of HDAC inhibitors are not fully elucidated, it might be attributed to the downregulation of hypoxia-inducible factor-1α and vascular endothelial growth factor expression.⁴⁵ Our results also demonstrated a beneficial effect of TSA on bleb angiogenesis. Aside from fibrosis, angiogenesis is another potential target to augment success after filtration surgery. The most recent attempts to develop new wound healing modulators have focused on fibroblast activities. However, modulating the neovascular drive during the wound healing process might also be important, since increased bleb vascularity is associated with an influx of inflammatory cytokines that can increase fibrovascular proliferation. Therefore, an agent targeting both fibrosis and angiogenesis would result in a more successful clinical outcome.

The exact mechanism through which TSA affects postoperative fibrosis has not yet been elucidated. The influx of inflammatory cells to the surgical site is an important wound healing response associated with fibrosis, and it has been reported that HDAC inhibitors have anti-inflammatory effects. Our study demonstrated that TSA eye drops significantly reduced leukocyte inflammation in the bleb tissue. In addition, TSA is thought to regulate the expression TGF-β, which is known to be the most important growth factor that induces α-SMA-positive myofibroblast phenotype and activates the synthesis and deposition of extracellular matrix components

and collagen. Among the TGF- β isoforms, TGF- β 1 is the principal isoform involved in the development of fibrosis.⁴⁶ In this study, TSA treatment decreased TGF- β 1 expression. Our findings suggest that the antifibrotic effect of TSA is mediated via a TGF- β 1-dependent pathway.

TGF- β 1 binds to its cognate receptor on the cell membrane and subsequently recruits Smad2 and Smad3. Smad complexes translocate from the cytoplasm to the nucleus, where they act as transcription factors and regulate target gene expression.⁴⁷ In this study, we found that Smad2/3 protein levels did not change significantly after trabeculectomy. However, the level of Smad2/3 phosphorylation was upregulated after surgery. Treatment with 1 μ mol/L TSA significantly suppressed this increase in Smad2/3 phosphorylation, suggesting that the antifibrotic effect of TSA is associated with the inhibition of TGF- β 1/Smad signaling pathways.

When developing eye drop treatments, it is crucial to investigate corneal toxicity. Although HDAC inhibitors have been suggested as potential therapeutics in trabeculectomy models, their side effects remain to be determined. Therefore, we further investigated the safety of TSA eye drops using corneal fluorescein staining. We found that all the five operated groups showed increased corneal fluorescein scores compared to unoperated normal eyes. Considering that the corneal fluorescein staining was more severe on postoperative day 1 and it largely improved on day 14, the increase in these scores might be mainly attributable to corneal damage induced by the operation itself. However, no significant difference in corneal epithelial damage was found between the five operated groups, indicating that there was no additional corneal toxicity resulting from TSA. These results indicate that TSA can be used safely as an eye drop.

In another aspect, previous studies have shown that HDAC inhibitors also provide neuroprotection in various models of retinal ganglion cell (RGC) injury.^{48,49} RGCs are also the target cells for glaucomatous damage. Fan et al.⁴⁹ previously demonstrated that suppressing HDAC activity by TSA can protect the retina from ischemic injury after acute IOP elevation. Therefore, we believe that the neuroprotective effect of TSA may potentiate its therapeutic effect in glaucoma.

This study has some limitations, which have been pointed out. First, a more detailed safety evaluation needs to be carried out in future researches prior to clinical application. Although HDAC enzymes are promising drug targets for fibrosis, currently available HDAC inhibitors, including TSA, are mostly nonselective. TSA blocks both class I and II HDACs, and there are no differences in affinity between the different types of HDAC isoforms. Considering the wide range of effects of HDACs on cell cycle regulation, proliferation, differentiation, metabolism, and DNA repair, the lack of specificity to a target enzyme could contribute to cytotoxicity and result in unexpected complications. A number of phase I/II trials have shown that systemic administration of unselective HDAC inhibitors leads to a variety of side effects. The use of HDAC1 isoform-specific inhibitor may provide a means of developing more specific and effective therapies for conjunctival fibrosis. However, among 11 zinc-dependent HDAC isoforms, it is particularly challenging to achieve selective isoform inhibition between HDAC1 and HDAC2, since they share a very high sequence similarity (97.8%) and have the same conserved residues around the catalytic pocket. As a result, it has been very difficult to develop selective inhibitors for HDAC1 and HDAC2. HDAC inhibitors that selectively target only one HDAC isoform will have greater clinical benefit combined with a better toxicity profile. Nevertheless, in the present study, we applied TSA as a topical eye drop so that concerns regarding the risk of systemic complications could be minimized. Second, 14 days might be too short to evaluate the degree of

fibrogenesis and to assess the treatment effect on fibrosis. Nonetheless, we observed obvious bleb fibrosis on day 14 and found a significant antifibrotic effect of TSA. Future studies with long-term follow-up and survival outcome evaluation might be required.

In conclusion, HDAC1 plays an important role in postoperative fibrosis after trabeculectomy in a rat model. The potent antifibrotic activity of TSA, an HDAC inhibitor, observed in this study, has shown that TSA may serve as a new eye drop-based treatment for modulating wound healing. The current findings will help develop molecular therapeutic targets and new treatment strategies for conjunctival fibrosis after trabeculectomy.

Acknowledgments

Supported by a grant (CRI17006-1) from Chonnam National University Hospital Biomedical Research Institute, by the 2016 Cheil-Nammyung Foundation Research Fund, the Bio and Medical Technology Development Program of the National Research Foundation (NRF) of Korea funded by the MSIT (NRF-2017M3A9E8023019), and by the Basic Science Research Program through the NRF of Korea funded by the Ministry of Education (NRF-2015R1D1A1A01059630). The funding organizations had no role in the design or conduct of this research.

Disclosure: **M.S. Sung**, None; **G.H. Eom**, None; **S.J. Kim**, None; **S.Y. Kim**, None; **H. Heo**, None; **S.W. Park**, None

References

1. Taylor HR, Keeffe JE. World blindness: a 21st century perspective. *Br J Ophthalmol*. 2001;85:261-266.
2. Heijl A, Leske MC, Bengtsson B, et al. Reduction of intraocular pressure and glaucoma progression: results from the Early Manifest Glaucoma Trial. *Arch Ophthalmol*. 2002;120:1268-1279.
3. Collaborative Normal-Tension Glaucoma Study Group. The effectiveness of intraocular pressure reduction in the treatment of normal-tension glaucoma. *Am J Ophthalmol*. 1998;126:498-505.
4. Addicks EM, Quigley HA, Green WR, Robin AL. Histologic characteristics of filtering blebs in glaucomatous eyes. *Arch Ophthalmol*. 1983;101:795-798.
5. Seibold LK, Sherwood MB, Kahook MY. Wound modulation after filtration surgery. *Surv Ophthalmol*. 2012;57:530-550.
6. Georgoulas S, Dahlmann-Noor A, Brocchini S, Khaw PT. Modulation of wound healing during and after glaucoma surgery. *Prog Brain Res*. 2008;173:237-254.
7. Khaw PT, Chang L, Wong TT, et al. Modulation of wound healing after glaucoma surgery. *Curr Opin Ophthalmol*. 2001;12:143-148.
8. Liu L, Siritwardena D, Khaw PT. Australia and New Zealand survey of antimetabolite and steroid use in trabeculectomy surgery. *J Glaucoma*. 2008;17:423-430.
9. Cohen JS, Greff LJ, Novack GD, Wind BE. A placebo-controlled, double-masked evaluation of mitomycin C in combined glaucoma and cataract procedures. *Ophthalmology*. 1996;103:1934-1942.
10. DeBry PW, Perkins TW, Heatley G, et al. Incidence of late-onset bleb-related complications following trabeculectomy with mitomycin. *Arch Ophthalmol*. 2002;120:297-300.
11. Palanca-Capistrano AM, Hall J, Cantor LB, et al. Long-term outcomes of intraoperative 5-fluorouracil versus intraoperative mitomycin C in primary trabeculectomy surgery. *Ophthalmology*. 2009;116:185-190.
12. Thiagalingam S, Cheng KH, Lee HJ, et al. Histone deacetylases: unique players in shaping the epigenetic histone code. *Ann N Y Acad Sci*. 2003;983:84-100.

13. Guo W, Shan B, Klingsberg RC, et al. Abrogation of TGF-beta1-induced fibroblast-myofibroblast differentiation by histone deacetylase inhibition. *Am J Physiol Lung Cell Mol Physiol*. 2009;297:L864-L870.
14. Huber LC, Distler JH, Moritz F, et al. Trichostatin A prevents the accumulation of extracellular matrix in a mouse model of bleomycin-induced skin fibrosis. *Arthritis Rheum*. 2007;56:2755-2764.
15. Kee HJ, Sohn IS, Nam KI, et al. Inhibition of histone deacetylation blocks cardiac hypertrophy induced by angiotensin II infusion and aortic banding. *Circulation*. 2006;113:51-59.
16. Pang M, Kothapally J, Mao H, et al. Inhibition of histone deacetylase activity attenuates renal fibroblast activation and interstitial fibrosis in obstructive nephropathy. *Am J Physiol Renal Physiol*. 2009;297:F996-F1005.
17. Sherwood MB, Esson DW, Neelakantan A, Samuelson DA. A new model of glaucoma filtration surgery in the rat. *J Glaucoma*. 2004;13:407-412.
18. Chong RS, Lee YS, Chu SWL, et al. Inhibition of monocyte chemoattractant protein 1 prevents conjunctival fibrosis in an experimental model of glaucoma filtration surgery. *Invest Ophthalmol Vis Sci*. 2017;58:3432-3439.
19. Kitano A, Okada Y, Yamanka O, et al. Therapeutic potential of trichostatin A to control inflammatory and fibrogenic disorders of the ocular surface. *Mol Vis*. 2010;16:2964-2973.
20. Pauly A, Brignole-Baudouin F, Labbé A, et al. New tools for the evaluation of toxic ocular surface changes in the rat. *Invest Ophthalmol Vis Sci*. 2007;48:5473-5483.
21. Sharma A, Anumanthan G, Reyes M, et al. Epigenetic modification prevents excessive wound healing and scar formation after glaucoma filtration surgery. *Invest Ophthalmol Vis Sci*. 2016;57:3381-3389.
22. Van Bergen T, Zahn G, Caldirola P, et al. Integrin $\alpha 5 \beta 1$ inhibition by CLT-28643 reduces postoperative wound healing in a mouse model of glaucoma filtration surgery. *Invest Ophthalmol Vis Sci*. 2016;57:6428-6439.
23. Yamanaka O, Ikeda K, Saika S, et al. Gene transfer of Smad7 modulates injury-induced conjunctival wound healing in mice. *Mol Vis*. 2006;12:841-851.
24. Wilson SL, Ahearne M, Hopkinson A. An overview of current techniques for ocular toxicity testing. *Toxicology*. 2015;327:32-46.
25. Lei D, Dong C, Wu WK, et al. Lentiviral delivery of small Hairpin RNA targeting connective tissue growth factor blocks profibrotic signaling in Tenon's capsule fibroblasts. *Invest Ophthalmol Vis Sci*. 2016;57:5171-5180.
26. Sharma A, Anumanthan G, Reyes M, et al. Epigenetic modification prevents excessive wound healing and scar formation after glaucoma filtration surgery. *Invest Ophthalmol Vis Sci*. 2016;57:3381-3389.
27. Chen YH, Liang CM, Chen CL, et al. Silibinin inhibits myofibroblast transdifferentiation in human tenon fibroblasts and reduces fibrosis in a rabbit trabeculectomy model. *Acta Ophthalmol*. 2013;91:e506-e515.
28. Shi H, Wang H, Fu S, et al. Losartan attenuates scar formation in filtering bleb after trabeculectomy. *Invest Ophthalmol Vis Sci*. 2017;58:1478-1486.
29. Nikita E, Moulin A, Vergados I, et al. A pilot study on ocular safety and efficacy of infliximab as an antifibrotic agent after experimental glaucoma filtration surgery. *Ophthalmol Ther*. 2017;6:323-334.
30. Mohamed-Ahmed AHA, Lockwood A, Li H, et al. An Ilomastat-CD eye drop formulation to treat ocular scarring. *Invest Ophthalmol Vis Sci*. 2017;58:3425-3431.
31. Yamanaka O, Saika S, Ohnishi Y, et al. Inhibition of p38MAP kinase suppresses fibrogenic reaction in conjunctiva in mice. *Mol Vis*. 2007;13:1730-1739.
32. Ekinçi M, Cagatay HH, Ceylan E, et al. Reduction of conjunctival fibrosis after trabeculectomy using topical α -lipoic acid in rabbit eyes. *J Glaucoma*. 2014;23:372-379.
33. Jung KI, Park CK. Pirfenidone inhibits fibrosis in foreign body reaction after glaucoma drainage device implantation. *Drug Des Devel Ther*. 2016;10:1477-1488.
34. Cinik R, Yüksel N, Pirhan D, Aslan MŞ, Subaşı C, Karaöz E. The effect of everolimus on scar formation in glaucoma filtering surgery in a rabbit model. *Curr Eye Res*. 2016;41:1438-1446.
35. Gregoretti I, Lee YM, Goodson HV. Molecular evolution of the histone deacetylase family: functional implications of phylogenetic analysis. *J Mol Biol*. 2004;338:17-31.
36. Xie M, Hill JA. HDAC-dependent ventricular remodeling. *Trends Cardiovasc Med*. 2013;23:229-235.
37. Montgomery RL, Davis CA, Potthoff MJ, et al. Histone deacetylases 1 and 2 redundantly regulate cardiac morphogenesis, growth, and contractility. *Genes Dev*. 2007;21:1790-1802.
38. Marumo T, Hishikawa K, Yoshikawa M, Hirahashi J, Kawachi S, Fujita T. Histone deacetylase modulates the proinflammatory and fibrotic changes in tubulointerstitial injury. *Am J Physiol Renal Physiol*. 2010;298:F133-F141.
39. Noh H, Oh EY, Seo JY, et al. Histone deacetylase-2 is a key regulator of diabetes- and transforming growth factor-beta1-induced renal injury. *Am J Physiol Renal Physiol*. 2009;297:F729-F739.
40. Ye Q, Li Y, Jiang H, et al. Prevention of pulmonary fibrosis via trichostatin A (TSA) in bleomycin induced rats. *Sarcoidosis Vasc Diffuse Lung Dis*. 2014;31:219-226.
41. Pang M, Kothapally J, Mao H, et al. Inhibition of histone deacetylase activity attenuates renal fibroblast activation and interstitial fibrosis in obstructive nephropathy. *Am J Physiol Renal Physiol*. 2009;297:F996-F1005.
42. Kaimori A, Potter JJ, Choti M, Ding Z, Mezey E, Koteish AA. Histone deacetylase inhibition suppresses the transforming growth factor beta1-induced epithelial-to-mesenchymal transition in hepatocytes. *Hepatology*. 2010;52:1033-1045.
43. Rombouts K, Niki T, Greenwel P, et al. Trichostatin A, a histone deacetylase inhibitor, suppresses collagen synthesis and prevents TGF-beta(1)-induced fibrogenesis in skin fibroblasts. *Exp Cell Res*. 2002;278:184-197.
44. Gaudana R, Ananthula HK, Parenky A, Mitra AK. Ocular drug delivery. *AAPS J*. 2010;12:348-360.
45. Kim MS, Kwon HJ, Lee YM, et al. Histone deacetylases induce angiogenesis by negative regulation of tumor suppressor genes. *Nat Med*. 2001;7:437-443.
46. Inagaki Y, Okazaki I. Emerging insights into Transforming growth factor beta Smad signal in hepatic fibrogenesis. *Gut*. 2007;56:284-292.
47. Shi Y, Massague J. Mechanisms of TGF-beta signaling from cell membrane to the nucleus. *Cell*. 2003;113:685-700.
48. Zhang H, Dai X, Qi Y, He Y, Du W, Pang JJ. Histone deacetylase inhibitors in the treatment of retinal degenerative diseases: Overview and perspectives. *J Ophthalmol*. 2015;2015:250812.
49. Fan J, Alsarraf O, Dahrouj M, et al. Inhibition of HDAC2 protects the retina from ischemic injury. *Invest Ophthalmol Vis Sci*. 2013;54:4072-4080.