

# Clinical and Prodromal Ocular Symptoms in Coronavirus Disease: A Systematic Review and Meta-Analysis

Takenori Inomata,<sup>1-4</sup> Koji Kitazawa,<sup>5,6</sup> Toshiki Kuno,<sup>7</sup> Jaemyoung Sung,<sup>1</sup> Masahiro Nakamura,<sup>4,8</sup> Masao Iwagami,<sup>9</sup> Hisato Takagi,<sup>10</sup> Akie Midorikawa-Inomata,<sup>3</sup> Jun Zhu,<sup>1,11</sup> Keiichi Fujimoto,<sup>1</sup> Yuichi Okumura,<sup>2,4,12</sup> Maria Miura,<sup>4,12</sup> Kenta Fujio,<sup>4,12</sup> Kunihiko Hirosawa,<sup>4,12</sup> Yasutsugu Akasaki,<sup>4,12</sup> Mizu Kuwahara,<sup>4,12</sup> Reza Dana,<sup>13</sup> and Akira Murakami<sup>1,4</sup>

<sup>1</sup>Department of Ophthalmology, Juntendo University Faculty of Medicine, Tokyo, Japan

<sup>2</sup>Department of Strategic Operating Room Management and Improvement, Juntendo University Graduate School of Medicine, Tokyo, Japan

<sup>3</sup>Department of Hospital Administration, Juntendo University Graduate School of Medicine, Tokyo, Japan

<sup>4</sup>Department of Digital Medicine, Juntendo University Graduate School of Medicine, Tokyo, Japan

<sup>5</sup>Department of Ophthalmology, Kyoto Prefectural University of Medicine, Kyoto, Japan

<sup>6</sup>Buck Institute for Research on Aging, Novato, California, United States

<sup>7</sup>Department of Medicine, Icahn School of Medicine at Mount Sinai, Mount Sinai Beth Israel, New York, New York, United States

<sup>8</sup>Precision Health, Department of Bioengineering, Graduate School of Engineering, The University of Tokyo, Tokyo, Japan

<sup>9</sup>Department of Health Services Research, Faculty of Medicine, University of Tsukuba, Ibaraki, Japan

<sup>10</sup>Department of Cardiovascular Surgery, Shizuoka Medical Center, Shizuoka, Japan

<sup>11</sup>Department of Ophthalmology, Subei People's Hospital Affiliated to Yangzhou University, Yangzhou, Jiangsu Province, China

<sup>12</sup>Department of Ophthalmology, Juntendo University Graduate School of Medicine, Tokyo, Japan

<sup>13</sup>Massachusetts Eye and Ear Infirmary, Department of Ophthalmology, Harvard Medical School, Boston, Massachusetts, United States

Correspondence: Takenori Inomata, Department of Ophthalmology, Juntendo University Faculty of Medicine, 3-1-3 Hongo, Bunkyo-ku, Tokyo 113-0033, Japan; [tinoma@juntendo.ac.jp](mailto:tinoma@juntendo.ac.jp).

**Received:** June 11, 2020

**Accepted:** July 29, 2020

**Published:** August 14, 2020

Citation: Inomata T, Kitazawa K, Kuno T, et al. Clinical and prodromal ocular symptoms in coronavirus disease: A systematic review and meta-analysis. *Invest Ophthalmol Vis Sci.* 2020;61(10):29. <https://doi.org/10.1167/iovs.61.10.29>

**PURPOSE.** This systematic review aimed to determine currently reported clinical and prodromal ocular symptoms in patients with coronavirus disease 2019 (COVID-19).

**METHODS.** An online article search was performed in PubMed and EMBASE. Altogether 15 studies (retrospective, prospective, or case studies) involving 1533 patients with COVID-19, reporting on ocular symptoms, and with outcome data available were identified. The Preferred Reporting Items for Systematic Reviews and Meta-Analyses reporting guidelines were followed. Study-specific estimates (incidence rates of ocular symptoms in patients with COVID-19) of cases were combined using one-group meta-analysis in a random-effects model.

**RESULTS.** Of all included studies, 11.2% (95% confidence interval, 5.5–16.9; 78/1526 cases) reported ocular symptoms. The most common ocular finding was conjunctivitis. Prodromal ocular symptoms occurred in 12.5% (13/104 cases) of patients with COVID-19. Positive real-time polymerase chain reaction results were obtained for 16.7% (10/60 cases) of conjunctival samples and 0% (0/17 cases) of tear samples. Twelve ocular conjunctival swab samples tested positive for SARS-CoV-2. Ten cases were from subjects showing ocular symptoms (16.7%, 10/60 cases), and the remaining two cases were from subjects without ocular manifestation (1.8%, 2/113 cases). Limitations included the short study period, small sample size, findings were limited to the Asian population, only seven articles included ophthalmologic examination details, and there is currently no consensus on COVID-19 management.

**CONCLUSIONS.** Ocular symptoms may occur in the presymptomatic phase as a prodromal symptom (12.5%, 13/104 cases), suggesting the possibility of viral transmission from the conjunctiva.

**Keywords:** coronavirus disease, coronavirus disease 2019, COVID-19, ocular symptoms, presymptomatic phase, prodromal symptoms, SARS-CoV-2, conjunctivitis



Severe acute respiratory syndrome coronavirus 2 (SARS-CoV-2) is a novel, enveloped, positive-sense, single-stranded RNA virus that causes respiratory, enteric, hepatic, and neurologic diseases.<sup>1</sup> The World Health Organization declared SARS-CoV-2 as the causative agent of coronavirus disease 2019 (COVID-19) in February 2020.<sup>2</sup> As of May 2020, COVID-19 has infected more than 4.13 million individuals and has spread globally.<sup>3</sup> Consequently, early detection of COVID-19 has been emphasized as a crucial infection control strategy.<sup>4,5</sup> According to currently available evidence, SARS-CoV-2 is transmitted to humans via respiratory droplets and aerosols.<sup>6,7</sup> The clinical features of COVID-19 include fever, cough, shortness of breath, nasal congestion, and ocular symptoms such as conjunctivitis.<sup>8,9</sup> Angiotensin I-converting enzyme 2 (ACE2) has been shown to encode a viral entry-associated gene for SARS-CoV-2 that is expressed in corneal epithelial cells and conjunctival tissue, as well as in the bronchial and pharyngeal mucosa.<sup>10</sup>

COVID-19 is diagnosed by a positive result on high-throughput sequencing or real-time reverse transcriptase-polymerase chain reaction (RT-PCR) assay of nasal and pharyngeal swab specimens.<sup>8</sup> The median incubation period for COVID-19 is approximately four to five days after exposure.<sup>9,11</sup> Recent reports have indicated that SARS-CoV-2 is excreted during the presymptomatic (asymptomatic) period of COVID-19, suggesting that the detection of presymptomatic individuals can be pivotal in controlling SARS-CoV-2 transmission.<sup>9,12,13</sup> Recent reports have described clinical ocular symptoms, such as conjunctivitis in COVID-19 as a prodromal symptom.<sup>14,15</sup> Furthermore, positive SARS-CoV-2 results using conjunctival swabs from the affected eye have suggested the possibility of ocular transmission.<sup>14,15</sup> This may result in potential transmission to healthcare workers, especially ophthalmologists and optometrists, who perform examinations in close proximity to patients with COVID-19 and may come into contact with tears and conjunctival secretions. Therefore elucidating the characteristics and prodromal ocular symptoms of COVID-19 may aid in preventing COVID-19 transmission.

This systematic review was performed to determine the clinical and prodromal ocular symptoms in patients with COVID-19.

## METHODS

### Outcomes

The primary aim of this study was the systematic evaluation and characterization of currently reported ophthalmic cases of COVID-19. In particular, the primary analysis focused on age, sex, ocular findings including prodromal ocular symptoms, clinical ocular symptoms, ocular therapeutic management, and presence of SARS-CoV-2 in ocular tissue using RT-PCR in patients with ocular symptoms associated with COVID-19. The diagnosis of COVID-19 was based on RT-PCR testing of nasopharyngeal specimen.

### Search Strategy

An extensive search strategy was designed to retrieve all articles published from April 2, 2020, to May 7, 2020, by combining the genetic terms [(coronavirus 2019) OR COVID-19 OR COVID OR SARS-CoV-2 OR (sars cov 2) OR (2019 novel coro-

navirus) OR 2019-nCoV) AND (Conjunctivitis OR (Ocular Surface) OR Eye OR Ophthalmology)] in key electronic bibliographic databases (PubMed and EMBASE) and following the Preferred Reporting Items for Systematic Reviews and Meta-Analyses reporting guidelines.<sup>16</sup> Study inclusion and exclusion criteria are shown in Figure 1. Search results were compiled using EndNote X9.3.2 software (Clarivate Analytics, Philadelphia, PA, USA). In keeping with the quality standards for reporting systematic reviews and meta-analyses of observational studies,<sup>17</sup> two independent researchers (T.I. and K.K.) screened the retrieved articles. The same investigators independently assessed the full texts of records deemed eligible in consensus.

### Data Extraction

Two independent reviewers (T.I. and K.K.) extracted data from each eligible study using a standardized data extraction sheet and subsequently cross-checked the results. Disagreements between the reviewers regarding the extracted data were resolved through discussion with a third reviewer (T.K.).<sup>18</sup> The following data were extracted: first author name, date of publication, type of study (retrospective study, case report, case series, or prospective study), country, cohort size, and characteristics of ocular symptoms in patients with COVID-19 including age, sex, and ocular findings. Ocular findings were assessed based on prodromal ocular symptoms, clinical ocular symptoms, ocular therapeutic management, and ocular RT-PCR results using conjunctival and tear samples.

### Statistical Analyses

Study-specific estimates (incidence rates of ocular symptoms) were combined using one-group meta-analysis in a random-effects model using OpenMetaAnalyst version 12.11.14 (available from <http://www.cebm.brown.edu/openmeta/>).<sup>19</sup> Subgroup analyses including only studies that had reported on a given outcome was undertaken.

## RESULTS

The database search identified 264 articles. One article was added through another source.<sup>8</sup> After removing 76 duplicates, 189 articles were reviewed based on the title and abstract. Of these articles, 170 were excluded based on article type (clinical guidelines, consensus documents, reviews, systematic reviews, and conference proceedings), other serotypes of SARS-CoV and Middle East respiratory syndrome, animal-based studies, mental health status during COVID-19, conference abstracts, other unrelated topics, and articles without ocular symptoms of COVID-19. Nineteen articles met the inclusion criteria and were assessed for the systematic review (Fig. 2). Four articles were excluded for reasons such as duplication,<sup>20</sup> or the articles covered neurologic<sup>21,22</sup> or molecular aspects.<sup>23</sup>

### Study Characteristics and Demographic Features

The articles included in this systematic review were published between March 24, 2020, and April 30, 2020. Eight articles were from China,<sup>8,14,24-29</sup> two were from Italy, and one each were from Singapore,<sup>30</sup> Canada,<sup>15</sup> Argentina,<sup>31</sup> the Netherlands,<sup>32</sup> and Iran.<sup>33</sup> Altogether,

**Inclusion Criteria**

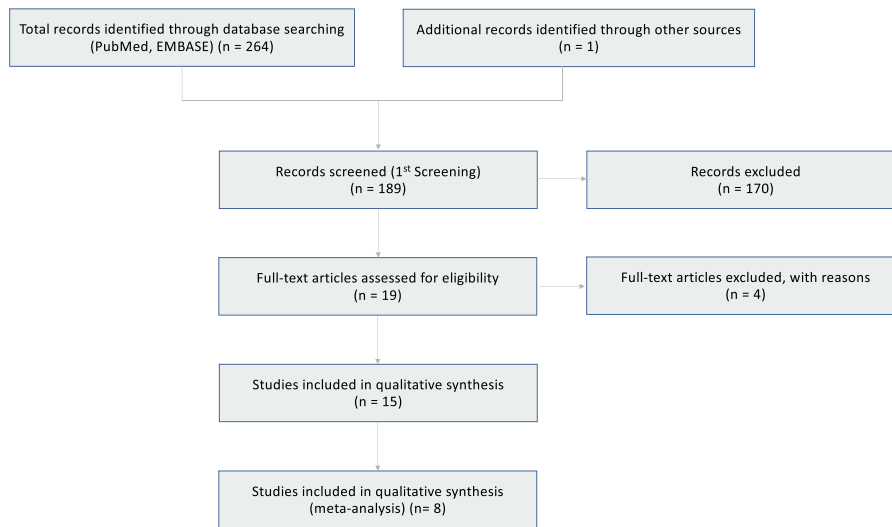
1. Population: patients with COVID-19 demonstrating ocular symptoms.
2. Study design: retrospective studies (cross-sectional studies, case-control studies, case series, and case reports) and prospective studies.
3. Outcome: evaluation of ocular findings with COVID-19; number, age, sex, prodromal ocular symptoms in presymptomatic COVID-19, clinical ocular symptoms, therapeutuics, and RT-PCR results using ocular tissues. therapeutuics.

**Exclusion Criteria**

1. Clinical guidelines, consensus documents, reviews, systematic reviews, and conference proceedings.
2. Studies about other serotypes of severe acute respiratory syndrome coronavirus and Middle East respiratory syndrome coronavirus infection.
3. Animal-based studies.
4. Mental health status during COVID-19.
5. Preprinted articles.
6. Conference abstracts.

Abbreviations: COVID-19, coronavirus disease 2019; RT-PCR, real-time reverse-transcriptase-polymerase-chain-reaction.

**FIGURE 1.** Study inclusion and exclusion criteria.



**FIGURE 2.** Flow diagram of study selection.

1533 individuals with confirmed COVID-19 were identified from the 15 studies (Table). Twelve articles reported the age (median [interquartile range]: 52 years [40–65 years], *n* =

37) at the onset of COVID-19,<sup>14,15,24,25,27–31,33–35</sup> and 12 articles mentioned the sex of the patients, with 36 men and 12 women in total.<sup>14,15,24,25,27–31,33–35</sup>

TABLE. Results of Systematic Review Articles

Source	Publication Date	Study Type	Country	Patients with COVID-19	Patients With Ocular Symptoms			Ocular Findings				
					No.	Age	Sex	Prodromal Ocular Symptoms* (Yes/No)	Ocular Symptoms	Therapy	Ocular RT-PCR	Findings
Seah et al. <sup>30</sup>	March 24, 2020	PS	Singapore	17	1/17 (5.9%)	Median, 37 years (range 20–75 years)	11 M	NA	Blurring of vision, color desaturation, conjunctivitis (on day 17), 2 weeks	NA	0/17 tear: negative	All tear samples tested negative, even when nasopharyngeal swab samples continued to show positive results
Wu et al. <sup>14</sup>	March 31, 2020	RS	China	38	12/38 (31.6%)	Median, 65 years [IQR: 52.5–77.5 years]	7 M/ 5 F	Yes (1/12)	12, conjunctivitis	NA	2/12 conjunctiva: positive	Although the prevalence of SARS-CoV-2 in the conjunctiva is low, transmission via the eyes is possible
Cheema et al. <sup>15</sup>	April 2, 2020	CR	Canada	1	1	29 years	F	Yes, 5 days before	Unilateral keratoconjunctivitis, photophobia, a sore and swollen eyelid, tender preauricular node, and cervical lymphadenopathy	Oral valacyclovir (500 mg) and moxifloxacin (1 drop)	Conjunctiva: positive	A case of COVID-19 who initially presented to ophthalmologists with keratoconjunctivitis and mild respiratory symptoms, without fever
Chen et al. <sup>24</sup>	April 7, 2020	CR	China	1	1	30 years	M	No	Bilateral conjunctivitis and tender palpable preauricular lymph nodes (on day 13), 7 days	Ribavirin eye drops	Conjunctiva: positive	SARS-CoV-2 is capable of causing ocular complications during the middle phase of the illness

TABLE. Continued

Source	Publication Date	Study Type	Country	Patients with COVID-19	Patients With Ocular Symptoms				Ocular Findings			
					No.	Age	Sex	Prodromal Ocular Symptoms* (Yes/No)	Ocular Symptoms	Therapy	Ocular RT-PCR	Findings
Zhang et al. <sup>25</sup>	April 11, 2020	RS	China	72/102	2/72 (2.8%); only one case has been reported)	29 years	F	Yes, 1 day before	Bilateral conjunctivitis without tenderness or enlargement of preauricular lymph nodes, 4 days	Ganciclovir eye drops	1 (1/2) conjunctiva: positive	SARS-CoV-2 has exhibited the capacity to use the eye as a portal of entry and cause ocular disease
Daruich et al. <sup>31</sup>	April 17, 2020	CR	Argentina	1	1	27 years	M	Yes, 3 hours before	Unilateral conjunctivitis and eyelid edema, 11 days	Topical application of antibiotic and corticosteroids	NA	This case illustrates the interest of telemedicine in ophthalmology during the COVID-19 pandemic, as moderate conjunctivitis can be the first sign of COVID-19
Zhou et al. <sup>26</sup>	April 21, 2020	RS	China	121	8/121 (6.6%)	NA	NA	NA	8, conjunctivitis	NA	1 (1/8) conjunctiva: positive, 1 for ocular symptoms (+), 2 for ocular symptoms (-)	The proportion of RT-PCR-positive results between conjunctival and nasopharyngeal samples from patients with COVID-19 was incorporated
Salducci et al. <sup>34</sup>	April 22, 2020	CR	Italy	1	1	72 years	M	Yes	Bilateral conjunctivitis, preauricular lymph nodes, and enlarged submaxillary nodes, 7 days	Artificial tears, antiviral gel (ganciclovir)	NA	Asymptomatic COVID-19 with conjunctivitis

TABLE. Continued

Source	Publication Date	Study Type	Country	Patients with COVID-19	Patients With Ocular Symptoms				Ocular Findings			
					No.	Age	Sex	Prodromal Ocular Symptoms* (Yes/No)	Ocular Symptoms	Therapy	Ocular RT-PCR	Findings
Wu et al. <sup>27</sup>	April 24, 2020	CR	China	1	2 years and 10 months	M	No	Conjunctivitis and eyelid dermatitis (on day 7), 5 days	NA	NA	NA	A child with conjunctivitis and eyelid dermatitis on day 7 of COVID-19
Tostmann et al. <sup>32</sup>	April 25, 2020	RS	The Netherlands	90/803	31/90 (34.4%)	NA	NA	31, ocular pain	NA	NA	NA	A targeted symptom-based screening strategy may be of value in settings with limited availability of testing materials
Hong et al. <sup>28</sup>	April 26, 2020	RS	China	56	Median, 51 years IQR: 46–57 years	11 M/4 F	Yes, 6/15	9, conjunctivitis; 5, dry eye; 2, foreign body sensation; and 1, floaters	NA	1/2 conjunctiva: positive	Among patients with COVID-19, 6 out of 56 subjects exhibited prodromal ocular symptoms and 15 out of 56 subjects showed deterioration in ocular symptoms	The SARS-CoV-2 RNA was detected from the normal ocular surface of patients with COVID-19
Xie et al. <sup>29</sup>	April 26, 2020	RS	China	33	90 years and 48 years <sup>†</sup>	M/F <sup>†</sup>	No/no	No ocular symptoms	NA	2/33 conjunctiva: positive <sup>†</sup>	2/33 conjunctiva: The SARS-CoV-2 RNA was detected from the normal ocular surface of patients with COVID-19	

TABLE. Continued

Source	Publication Date	Study Type	Country	Patients with COVID-19			Patients With Ocular Symptoms				Ocular Findings			
				COVD-19	No.	Age	Sex	Prodromal Ocular Symptoms* (Yes/No)	Ocular Symptoms	Therapy	Ocular RT-PCR	Findings		
Khavandi et al. <sup>33</sup>	April 27, 2020	CR	Iran	1	1	65 years	M	Yes, 2 days before	Conjunctivitis	Oral administration of oseltamivir capsule (75 mg) and hydroxy-chloroquine tablet (200 mg)	Conjunctiva: positive	Prodromal conjunctivitis and late development of classic COVID-19 symptoms		
Casalino et al. <sup>35</sup>	April 28, 2020	CR	Italy	1	1	48 years	M	Yes, 2 days before	Unilateral conjunctivitis	Oral paracetamol (1 g) as well as topical tobramycin and dexamethasone, 8 days	NA	Conjunctivitis may represent one of the prodromal symptoms of COVID-19		
Guan et al. <sup>8</sup>	April 30, 2020	RS	China	1,099/7,736	9/1,099 (0.8%)	NA	NA	NA	NA	NA	NA	Low prevalence of ocular symptoms in patients with COVID-19		

CR, case report; IQR, interquartile range; NA, not applicable; PS, prospective study; RS, retrospective study.

\* Prodromal ocular symptoms (yes, no); prodromal ocular symptoms or first visit to an ophthalmologist.

† No ocular symptoms with COVID-19.



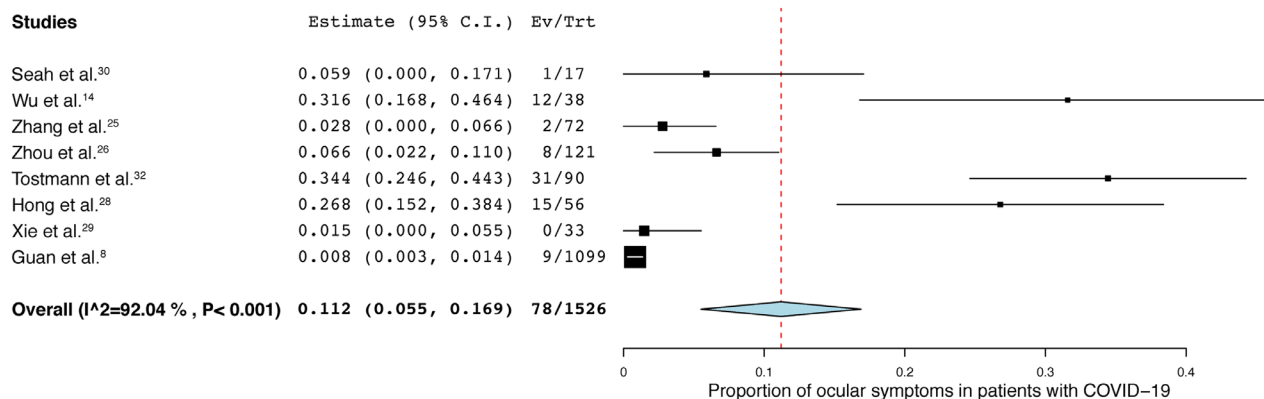


FIGURE 3. Proportion of ocular symptoms in patients with coronavirus disease (COVID-19).

### Prodromal Ocular Symptoms, Clinical Ocular Symptoms, and Therapeutic Management

Using one-group meta-analysis in a random-effects model, eight prospective, retrospective, and case-control studies involving 1526 individuals with COVID-19 were further analyzed for the incidence rates of ocular symptoms in these patients (Fig. 3).<sup>8,14,25,26,28–30,32</sup>

Among these individuals, 11.2% of patients with COVID-19 (95% confidence interval [CI], 5.5–16.9; 78/1526 cases) exhibited ocular symptoms. Unilateral or bilateral conjunctivitis was the leading symptom (86.4%, 38/44 cases),<sup>14,15,24–27,30,31,34</sup> followed by ocular pain (34.4%, 31/90 cases),<sup>32</sup> dry eye (33.3%, 5/15 cases),<sup>28</sup> and floaters (6.7%, 1/15 cases).<sup>28</sup>

Two case reports have described unique findings, with one reporting eyelid dermatitis<sup>27</sup> and the other reporting keratoconjunctivitis.<sup>15</sup> Three patients presented with conjunctivitis accompanied by tender preauricular lymph nodes.<sup>15,24,34</sup> A history of prodromal ocular symptoms in patients with COVID-19 was described in 11 articles (12.5%, 13/104 cases).<sup>14,15,24,25,27–29,31,33–35</sup> Seven articles reported therapeutic management for ocular symptoms in patients with COVID-19—namely, a combination of oral valacyclovir and moxifloxacin<sup>15</sup>; ribavirin eye drops<sup>24</sup>; ganciclovir eye drops<sup>25</sup>; topical application of antibiotic and corticosteroids<sup>31</sup>; artificial tears and ganciclovir gel<sup>34</sup>; oral administration of oseltamivir and hydroxychloroquine<sup>33</sup>; and oral paracetamol and a tapering course of topically administered tobramycin and dexamethasone.<sup>35</sup>

### Ocular Viral Loads

Eight articles reported conjunctival swabs for RT-PCR in patients with COVID-19; the positive rate was 16.7% (10/60 cases).<sup>14,15,24–29,31,33,34</sup> Conjunctival specimen from two patients (1.8%, 2/113 cases) were positive for SARS-CoV-2 in the absence of ocular symptoms.<sup>29</sup> One article described tear sampling for RT-PCR and the results were all negative (0/17 cases).<sup>30</sup>

### DISCUSSION

Our review identified 11.2% of patients (95% CI, 5.5–16.9; 78/1526 cases) with ocular symptoms among patients with COVID-19, mostly presenting with conjunctivitis. Prodromal

ocular symptoms occurred in 12.5% (13/104 cases) of patients with COVID-19. SARS-CoV-2 positive RT-PCR results were obtained in 16.7% (10/60 cases) of conjunctival samples; however, none of the tear samples (0/17 cases) were positive. Patients with COVID-19 may develop prodromal conjunctivitis and may present with symptoms of the disease during their visit to an ophthalmologist, which suggests that the conjunctiva may present another possible transmission route for SARS-CoV-2. Although unlikely, we propose that the two positive conjunctival swab results from patients without ocular symptoms<sup>26</sup> point to absence of ocular symptoms being unreliable as an indicator of SARS-CoV-2 conjunctival transmission.

The overall prevalence of ocular symptoms in patients with COVID-19 was 11.2%, which is not a common finding. Nevertheless, this reported prevalence might be an underestimation because patients with COVID-19 present with life-threatening clinical scenarios, which may preclude a detailed ocular examination or relevant history, and large retrospective studies did not include detailed ophthalmic examinations.<sup>8</sup> The most common ocular symptom was conjunctivitis (86.3%, 38/44 cases), accompanied by hyperemia, foreign body sensation, chemosis, and epiphora, followed by ocular pain, dry eye, floaters, and eyelid dermatitis. One patient initially presented with herpes-like pseudodendritic infiltration on the cornea, leading to a decline in vision due to severe keratoconjunctivitis.<sup>15</sup> Unlike coronavirus infection, epidemic keratoconjunctivitis, which is the most frequent manifestation of ocular adenoviral infection, occurred in approximately 75% cases, with accompanying pseudomembrane formation.<sup>36</sup> This is because species D adenoviruses, notably Ad8, Ad19, and Ad37, are capable of efficient binding to corneal and conjunctival epithelial cells<sup>37</sup> and demonstrate high degrees of resistance to defensin-like chemokines.<sup>38</sup> This results in the activation of nuclear factor- $\kappa$ B and induction of various cytokines.<sup>39</sup> In contrast, the coronavirus does not appear to attract significant reactions from the immune system and is thus rarely associated with inflammatory responses of the ocular surface.<sup>40</sup> In fact, no case with persistent subepithelial corneal infiltrates was reported in the reviewed studies. However, the analysis of ACE2 expression across different tissues revealed that ACE2, which has been known to encode a viral entry-associated gene for SARS-CoV-2, was predominantly present in corneal and conjunctival cells.<sup>41</sup> This may elucidate the prolonged conjunctivitis in patients with COVID-19, even



though concurrent clinical keratitis was not present at that time.

In three cases of conjunctivitis, tender palpable preauricular lymph nodes were observed, which is considered a valuable aid in the diagnosis of early cases, although this is not a specific finding. Considering that 12.5% of cases (13/104 cases) had a history of prodromal ocular symptoms at three hours to five days before the onset of COVID-19, ocular examination should be initially considered. Although no unremarkable findings in the retina were observed, a recent study has reported more prominent hyperreflective lesions at the level of ganglion cells and inner plexiform layers at the papillomacular bundle in both eyes.<sup>42</sup> Therefore the detection of ACE2 in human retinal cells<sup>43</sup> suggests the need for performing full eye examinations so as not to overlook retinal impairment.

We reviewed various therapeutic agents, some applied systemically and some topically, including antiherpes medicines, antibiotic eye drops, and artificial tears. Two patients were treated with a combination of antibacterial eye drops and corticosteroid eye drops.<sup>31,35</sup> However, the use of topical steroids as a treatment for viral keratitis may delay the recovery time and is a point of contention among clinicians.<sup>44</sup> Considering the lower possibility of severe keratoconjunctivitis caused by coronavirus compared to the risk associated with adenovirus, injudicious use of topical corticosteroid eye drops may only increase the risk of bacterial infection. Most ocular symptoms in patients with COVID-19 were mild, lasted for four to 14 days, and healed relatively rapidly, with no sight-threatening complications observed. Nevertheless, because there is currently no proven treatment for ocular symptoms in COVID-19, further studies are required.

No virions were detected in the tear samples from seventeen patients with COVID-19,<sup>30</sup> whereas positive results were obtained for 16.7% (10/60 cases) of conjunctival swabs for RT-PCR,<sup>14,15,24,26,28,29,33,45</sup> indicating that the risk of SARS-CoV-2 transmission from ocular to respiratory systems should be considered low. Nevertheless, the sampling time lag and the low amounts of viral RNA may contribute to the inefficiency of the detection rate. Viral loads may be approximately 10,000-fold different between conjunctival and nasal mucosa samples according to the number of amplification cycles in quantitative RT-PCR assays.<sup>24</sup> As the virus completes its replication cycle within the cell, it would be advantageous to collect samples by rubbing the swab onto the conjunctival epithelium. The other consideration is that diverse respiratory pathogens represent differing immune reactions. Unlike most respiratory viruses such as adenoviruses and influenza viruses, coronaviruses have been documented to rarely infect the conjunctiva.<sup>40</sup>

Recent studies have confirmed the transmissibility of SARS-CoV-2 during the presymptomatic period and within five days of symptom onset.<sup>46,47</sup> Although the transmission route of the virus is yet to be clarified, virus-containing droplets and aerosols are presumed to be the most likely pathways of SARS-CoV-2 transmission. Therefore, to prevent SARS-CoV-2 transmission from patients with presymptomatic COVID-19, it may be important to capture contact tracing events during the presymptomatic period<sup>48,49</sup> and to apply behavioral changes to prevent contact with droplets and aerosols by avoiding the following three Cs: closed spaces with insufficient ventilation, crowded conditions with people, and conversation at a short distance.<sup>50,51</sup> Prodromal conjunctivitis may signal presymp-

tomatic COVID-19, as demonstrated in 12.5% of the cases from the selected studies. Although this might indicate that conjunctival transmission may not be the major transmission route, it must be remembered that frontline health-care workers without adequate eye protection have been infected with SARS-CoV-2.<sup>45,52</sup> In routine ophthalmic examinations, noncontact tonometers can produce a large amount of aerosols by applying pressured gas to the eye,<sup>53</sup> and the use of face shields as well as good hygiene practice can afford protection to eye care providers and frontline health-care workers.

This study has several limitations. First, this systematic review covered a short period (three months); hence, the sample size might still be limited. Second, most of the articles included were published from China, possibly limiting the generalizability of the findings to non-Asian populations. Third, this review included only seven case reports with ocular examinations; other articles with large sample sizes did not include detailed ocular examinations and prognosis. In addition, it may be difficult to distinguish presymptomatic-COVID-19 conjunctivitis from conjunctivitis of other causes, unless SARS-CoV-2 is confirmed by RT-PCR of the conjunctiva. Fourth, because there is currently no proven treatment for COVID-19, no consensus treatment has emerged. During the pandemic, the lack of consultation with ophthalmologists may inadvertently trivialize the importance of ocular symptoms with COVID-19. Two patients had positive results on conjunctival swab testing in the absence of ocular symptoms. More detailed assessments with larger sample sizes may be needed.

This systematic review assessed clinical ocular findings and discussed the possibility of ocular findings as prodromal symptoms and as the source of transmission from patients with COVID-19. Ocular findings occurred in 11.2% of patients with COVID-19, and it should be noted that ocular manifestations such as conjunctivitis may represent one of the prodromal symptoms of COVID-19. This review suggests that there is a potential risk of transmission from the conjunctiva and necessitates appropriate precautions, especially for ophthalmologists who may encounter presymptomatic patients with COVID-19.

### Acknowledgments

The authors thank all members of the Department of Ophthalmology, Juntendo University Faculty of Medicine for giving critical comments on this manuscript.

Disclosure: **T. Inomata**, None; **K. Kitazawa**, None; **T. Kuno**, None; **J. Sung**, None; **M. Nakamura**, None; **M. Iwagami**, None; **H. Takagi**, None; **A. Midorikawa-Inomata**, None; **J. Zhu**, None; **K. Fujimoto**, None; **Y. Okumura**, None; **M. Miura**, None; **K. Fujio**, None; **K. Hirose**, None; **Y. Akasaki**, None; **M. Kuwahara**, None; **R. Dana**, None; **A. Murakami**, None

### References

1. Zhu N, Zhang D, Wang W, et al. A novel coronavirus from patients with pneumonia in China, 2019. *N Engl J Med*. 2020;382:727-733.
2. World Health Organization (WHO). *WHO Director-General's remarks at the media briefing on 2019-nCoV on 11 February 2020*. Geneva: World Health Organization. Available at: <https://www.who.int/dg/speeches/detail/who-director-general-s-remarks-at-the-media-briefing-on-2019-ncov-on-11-february-2020>. Accessed June 10, 2020.

3. COVID, CSSE. Dashboard by the Center for Systems Science and Engineering (CSSE) at Johns Hopkins University (JHU). 2020. (19)
4. Chu HY, Englund JA, Starita LM, et al. Early detection of COVID-19 through a citywide pandemic surveillance platform. *N Engl J Med*. 2020;383:185–187.
5. Ferretti L, Wymant C, Kendall M, et al. Quantifying SARS-CoV-2 transmission suggests epidemic control with digital contact tracing. *Science*. 2020;368:eabb6936.
6. World Health Organization. *Modes of transmission of virus causing COVID-19: implications for IPC precaution recommendations, 27 March 2020*. No. WHO/2019-nCoV/Sci\_Brief/Transmission\_modes/2020.1. Geneva: World Health Organization. 2020.
7. Meselson M. Droplets and aerosols in the transmission of SARS-CoV-2. *N Engl J Med*. 2020;382:2063.
8. Guan WJ, Ni ZY, Hu Y, et al. Clinical characteristics of Coronavirus disease 2019 in China. *N Engl J Med*. 2020;382:1708–1720.
9. Gandhi M, Yokoe DS, Havlir DV. Asymptomatic Transmission, the Achilles' Heel of Current Strategies to Control COVID-19. *N Engl J Med*. 2020;382:2158–2160.
10. Sungnak W, Huang N, Bécavin C, et al. SARS-CoV-2 entry factors are highly expressed in nasal epithelial cells together with innate immune genes. *Nat Med*. 2020;26:681–687.
11. Tay MZ, Poh CM, Rénia L, MacAry PA, Ng LFP. The trinity of COVID-19: immunity, inflammation and intervention. *Nat Rev Immunol*. 2020;20:1–12.
12. Arons MM, Hatfield KM, Reddy SC, et al. Presymptomatic SARS-CoV-2 infections and transmission in a skilled nursing facility. *N Engl J Med*. 2020;382:2081–2090.
13. Wölfel R, Corman VM, Guggemos W, et al. Virological assessment of hospitalized patients with COVID-2019. *Nature*. 2020;581:465–469.
14. Wu P, Duan F, Luo C, et al. Characteristics of ocular findings of patients with Coronavirus disease 2019 (COVID-19) in Hubei Province, China. *JAMA Ophthalmol*. 2020;138:575–578.
15. Cheema M, Aghazadeh H, Nazarali S, et al. Keratoconjunctivitis as the initial medical presentation of the novel coronavirus disease 2019 (COVID-19). *Can J Ophthalmol*. 2020;55:e125–e129.
16. Moher D, Liberati A, Tetzlaff J, Altman DG, Group P. Preferred reporting items for systematic reviews and meta-analyses: the PRISMA statement. *PLoS Med*. 2009;6:e1000097.
17. Stroup DF, Berlin JA, Morton SC, et al. Meta-analysis of observational studies in epidemiology: a proposal for reporting. Meta-analysis Of Observational Studies in Epidemiology (MOOSE) group. *JAMA*. 2000;283:2008–2012.
18. Kuno T, Takagi H, Ando T, et al. Oral anticoagulation for patients with atrial fibrillation on long-term hemodialysis. *J Am Coll Cardiol*. 2020;75:273–285.
19. Takagi H, Hari Y, Kawai N, Ando T. Meta-Analysis and Meta-Regression of Transcatheter Aortic Valve Implantation for Pure Native Aortic Regurgitation. *Heart Lung Circ*. 2020;29:729–741.
20. Daruich A, Martin D, Bremond-Gignac D. Unilateral conjunctivitis as first presentation of Coronavirus Disease 2019 (COVID-19): A telemedicine diagnosis. *J Fr Ophtalmol*. 2020;43:e167–e168.
21. Gutiérrez-Ortiz C, Méndez-Guerrero A, Rodrigo-Rey S, et al. Miller Fisher syndrome and polyneuritis cranialis in COVID-19. *Neurology*. 2020;95:e601–e605.
22. Dinkin M, Gao V, Kahan J, et al. COVID-19 presenting with ophthalmoparesis from cranial nerve palsy. *Neurology*. 2020;95:221–223.
23. Vaninov N. In the eye of the COVID-19 cytokine storm. *Nat Rev Immunol*. 2020;20:277.
24. Chen L, Liu M, Zhang Z, et al. Ocular manifestations of a hospitalised patient with confirmed 2019 novel coronavirus disease. *Br J Ophthalmol*. 2020;104:748–751.
25. Zhang X, Chen X, Chen L, et al. The evidence of SARS-CoV-2 infection on ocular surface. *Ocul Surf*. 2020;18:360–362.
26. Zhou Y, Duan C, Zeng Y, et al. Ocular findings and proportion with conjunctival SARS-CoV-2 in COVID-19 patients. *Ophthalmology*. 2020;127:982–983.
27. Wu P, Liang L, Chen C, Nie S. A child confirmed COVID-19 with only symptoms of conjunctivitis and eyelid dermatitis. *Graefes Arch Clin Exp Ophthalmol*. 2020;258: 1565–1566.
28. Hong N, Yu W, Xia J, Shen Y, Yap M, Han W. Evaluation of ocular symptoms and tropism of SARS-CoV-2 in patients confirmed with COVID-19. *Acta Ophthalmol*. <https://doi.org/10.1111/aos>, published online ahead of print.
29. Xie HT, Jiang SY, Xu KK, et al. SARS-CoV-2 in the ocular surface of COVID-19 patients. *Eye Vis*. 2020;7:23.
30. Seah IYJ, Anderson DE, Kang AEZ, et al. Assessing viral shedding and infectivity of tears in coronavirus disease 2019 (COVID-19) patients. *Ophthalmology*. 2020;127:977–979.
31. Daruich A, Martin D, Bremond-Gignac D. Ocular manifestation as first sign of coronavirus disease 2019 (COVID-19): interest of telemedicine during the pandemic context. *J Fr Ophtalmol*. 2020;43:389–391.
32. Tostmann A, Bradley J, Bousema T, et al. Strong associations and moderate predictive value of early symptoms for SARS-CoV-2 test positivity among healthcare workers, the Netherlands, March 2020. *Euro Surveill*. 2020;25:2000508.
33. Khavandi S, Tabibzadeh E, Naderan M, Shoar S. Corona virus disease-19 (COVID-19) presenting as conjunctivitis: atypically high-risk during a pandemic. *Cont Lens Anterior Eye*. 2020;43:211–212.
34. Salducci M, La Torre G. COVID-19 emergency in the cruise's ship: a case report of conjunctivitis. *Clin Ter*. 2020;171:e189–e191.
35. Casalino G, Monaco G, Di Sarro PP, David A, Scialdone A. Coronavirus disease 2019 presenting with conjunctivitis as the first symptom. *Eye*. 2020;34:1235–1236.
36. Hogan MJ, Crawford JW. Epidemic keratoconjunctivitis: (superficial punctate keratitis, keratitis subepithelialis, keratitis maculosa, keratitis nummularis) with a review of the literature and a report of 125 cases. *Am J Ophthalmol*. 2018;190:xxix–xlii.
37. Nilsson EC, Storm RJ, Bauer J, et al. The GD1a glycan is a cellular receptor for adenoviruses causing epidemic keratoconjunctivitis. *Nat Med*. 2011;17:105–109.
38. Harvey SA, Romanowski EG, Yates KA, Gordon YJ. Adenovirus-directed ocular innate immunity: the role of conjunctival defensin-like chemokines (IP-10, I-TAC) and phagocytic human defensin-alpha. *Invest Ophthalmol Vis Sci*. 2005;46:3657–3665.
39. Rajaiya J, Sadeghi N, Chodosh J. Specific NFkappaB subunit activation and kinetics of cytokine induction in adenoviral keratitis. *Mol Vis*. 2009;15:2879–2889.
40. Belser JA, Rota PA, Tumpey TM. Ocular tropism of respiratory viruses. *Microbiol Mol Biol Rev*. 2013;77:144–156.
41. Sungnak W, Huang N, Bécavin C, et al. SARS-CoV-2 entry factors are highly expressed in nasal epithelial cells together with innate immune genes. *Nat Med*. 2020;26:681–687.
42. Marinho PM, Marcos AAA, Romano AC, Nascimento H, Belfort R, Jr. Retinal findings in patients with COVID-19. *Lancet*. 2020;395:1610.
43. Senanayake P, Drazba J, Shadrach K, et al. Angiotensin II and its receptor subtypes in the human retina. *Invest Ophthalmol Vis Sci*. 2007;48:3301–3311.

44. Laibson PR, Dhiri S, Oconer J, Ortolan G. Corneal infiltrates in epidemic keratoconjunctivitis. Response to double-blind corticosteroid therapy. *Arch Ophthalmol*. 1970;84:36–40.
45. Zhang X, Chen X, Chen L, et al. The evidence of SARS-CoV-2 infection on ocular surface. *Ocul Surf*. 2020;18:360–362.
46. He X, Lau EHY, Wu P, et al. Temporal dynamics in viral shedding and transmissibility of COVID-19. *Nat Med*. 2020;26:672–675.
47. Steinbrook R. Contact tracing, testing, and control of COVID-19-learning from Taiwan. *JAMA Intern Med*. doi:10.1001/jamainternmed.2020.2072, published online ahead of print.
48. Drew DA, Nguyen LH, Steves CJ, et al. Rapid implementation of mobile technology for real-time epidemiology of COVID-19. *Science*. 2020;368:1362–1367.
49. Li Q, Guan X, Wu P, et al. Early transmission dynamics in Wuhan, China, of novel coronavirus-infected pneumonia. *N Engl J Med*. 2020;382:1199–1207.
50. West R, Michie S, Rubin GJ, Amlôt R. Applying principles of behaviour change to reduce SARS-CoV-2 transmission. *Nat Hum Behav*. 2020;4:451–459.
51. Japanese Ministry of Health, Labour and Welfare. About coronavirus disease 2019 (COVID-19). 2020. Accessed May 16, 2020, [https://www.mhlw.go.jp/stf/seisakunitsuite/bunya/newpage\\_00032.html](https://www.mhlw.go.jp/stf/seisakunitsuite/bunya/newpage_00032.html).
52. Lu C-w, Liu X-f, Jia Z-f. 2019-nCoV transmission through the ocular surface must not be ignored. *Lancet*. 2020;395:e39.
53. Britt JM, Clifton BC, Barnebey HS, Mills RP. Microaerosol formation in noncontact 'air-puff' tonometry. *Arch Ophthalmol*. 1991;109:225–228.