

Efficacy, Toxicity, and Pharmacokinetics of Intra-Arterial Chemotherapy Versus Intravenous Chemotherapy for Retinoblastoma in Animal Models and Patients

Anthony B. Daniels¹⁻⁴, Michael T. Froehler⁵, Jessica V. Kaczmarek^{1,*}, Carley M. Bogan¹, Pranav R. Santapuram^{1,6,**}, Janene M. Pierce¹, Sheau-Chiann Chen^{4,7}, Emma A. Schrepf⁶, Kelli L. Boyd^{4,8,†}, Yuankai K. Tao^{9,10}, Marion W. Calcutt¹¹, Tatsuki Koyama^{4,7}, Ann Richmond^{3,4,12,13}, and Debra L. Friedman^{4,6}

¹ Division of Ocular Oncology and Pathology, Department of Ophthalmology and Visual Sciences, Vanderbilt University Medical Center, Nashville, TN, USA

² Department of Radiation Oncology, Vanderbilt University Medical Center, Nashville, TN, USA

³ Program in Cancer Biology, Vanderbilt University, Nashville, TN, USA

⁴ Vanderbilt-Ingram Cancer Center, Vanderbilt University Medical Center, Nashville, TN, USA

⁵ Cerebrovascular Program, Vanderbilt University Medical Center, Nashville, TN, USA

⁶ Department of Pediatrics, Vanderbilt University Medical Center, Nashville, TN, USA

⁷ Department of Biostatistics, Vanderbilt University Medical Center, Nashville, TN, USA

⁸ Department of Pathology, Microbiology and Immunology, Vanderbilt University Medical Center, Nashville, TN, USA

⁹ Department of Biomedical Engineering, Vanderbilt University, Nashville, TN, USA

¹⁰ Department of Ophthalmology and Visual Sciences, Vanderbilt University Medical Center, Nashville, TN, USA

¹¹ Department of Chemistry, Vanderbilt University, Nashville, TN, USA

¹² Tennessee Valley Healthcare System, Department of Veterans Affairs, Nashville, TN, USA

¹³ Department of Pharmacology, Vanderbilt University, Nashville, TN, USA

Correspondence: Anthony B. Daniels, Department of Ophthalmology and Visual Sciences, Vanderbilt Eye Institute, Vanderbilt University Medical Center, 2311 Pierce Avenue, Nashville, TN 37232, USA. e-mail:

anthony.b.daniels@vumc.org

Received: December 7, 2020

Accepted: August 1, 2021

Published: September 8, 2021

Keywords: animal models; carboplatin; efficacy; intra-arterial chemotherapy; intravenous chemotherapy; melphalan; ocular tumors; pharmacokinetics; rabbit; retinoblastoma; toxicity

Citation: Daniels AB, Froehler MT, Kaczmarek JV, Bogan CM, Santapuram PR, Pierce JM, Chen SC, Schrepf EA, Boyd KL, Tao YK, Calcutt MW, Koyama T, Richmond A, Friedman DL. Efficacy, toxicity, and pharmacokinetics of intra-arterial

Purpose: Through controlled comparative rabbit experiments and parallel patient studies, our purpose was to understand mechanisms underlying differences in efficacy and toxicity between intra-arterial chemotherapy (IAC) and intravenous chemotherapy (IVC).

Methods: In rabbits, ocular tissue drug levels were measured following IAC and IVC. Retinal toxicity was assessed using electroretinography, fluorescein angiography, optical coherence tomography (OCT) and OCT angiography. Efficacy to eradicate retinoblastoma orthotopic xenografts was compared. In IAC and IVC patients, we measured blood carboplatin pharmacokinetics and compared efficacy and toxicity.

Results: In rabbits receiving IAC, maximum carboplatin levels were 134 times greater in retina ($P = 0.01$) and 411 times greater in vitreous ($P < 0.001$), and total carboplatin (area under the curve) was 123 times greater in retina ($P = 0.005$) and 131 times greater in vitreous ($P = 0.02$) compared with IVC. Melphalan levels were 12 times greater ($P = 0.003$) in retina and 26 times greater in vitreous ($P < 0.001$) for IAC. Blood levels were not different. IAC melphalan (but not IV melphalan or IV carboplatin, etoposide, and vincristine) caused widespread apoptosis in retinoblastoma xenografts but no functional retinal toxicity or cytopenias. In patients, blood levels following IVC were greater ($P < 0.001$) but, when adjusted for treatment dose, were not statistically different. Per treatment cycle in patients, IVC caused higher rates of anemia (0.32 ± 0.29 vs. 0.01 ± 0.04 ; $P = 0.0086$), thrombocytopenia (0.5 ± 0.42 vs. 0.0 ± 0.0 ; $P = 0.0042$), and neutropenia (0.58 ± 0.3 vs. 0.31 ± 0.25 ; $P = 0.032$) but lower treatment success rates ($P = 0.0017$).

chemotherapy versus intravenous chemotherapy for retinoblastoma in animal models and patients. *Transl Vis Sci Technol.* 2021;10(11):10, <https://doi.org/10.1167/tvst.10.11.10>

Conclusions: The greater efficacy and lower systemic toxicity with IAC appear to be attributable to the greater ocular-to-systemic drug concentration ratio compared with IVC.

Translational Relevance: Provides an overarching hypothesis for a mechanism of efficacy/toxicity to guide future drug development.

Introduction

Intravenous chemotherapy (IVC) achieves relatively poor rates of globe salvage for more advanced retinoblastoma (RB) eyes (International Classification groups D and E),^{1,2} particularly in eyes with vitreous seeds.³ During the past decade, intra-arterial chemotherapy (IAC), with chemotherapy delivered endovascularly via a microcatheter directly to the ophthalmic artery,⁴ has increasingly replaced IVC as primary therapy for RB at many centers around the world.⁵ IAC has been shown to have greater success at eradicating intraocular RB and salvaging eyes than IVC.^{6,7} This difference is most pronounced when treating tumor types that historically were more difficult to treat with IVC, such as eyes with vitreous seeds^{1,7} or the highly differentiated (or “cavitary”) form of RB.⁸

IVC is associated with systemic toxicities, including cytopenias, neutropenic fever, and the need for transfusions.^{6,9–12} Although systemic adverse events such as neutropenia can also occur with IAC,^{1,13,14} clinical evidence suggests that these events are less common than with IVC.⁶ However, IAC can be associated with ocular toxicities, including minor and transient events such as eyelid swelling and erythema, as well as vision-threatening consequences including chorioretinal infarctions and atrophy.^{1,6,9,10,15} Serious complications represent a minority of ocular complications with IAC^{1,6} and appear to decrease with procedural experience.¹⁵ However, taken together, IAC ocular complications are not rare,^{6,10} and the prevalence of vision-threatening complications in particular is higher with IAC than with IVC.

There are several challenges when using clinical experience to compare the efficacy and systemic and ocular toxicity of IAC versus IVC:

1. *Patients have very variable disease*—Because an eye can only receive, as first line, either IAC or IVC, it is difficult to compare responses among eyes directly, and there is likely selection bias, where eyes with more advanced disease are more likely to receive IAC as first-line therapy.

2. *Variable number of treatments and variable drugs and drug combinations utilized*—Chemotherapy regimens and number of cycles are relatively standardized for IVC,^{11,16} but IAC regimens may involve different combinations of drugs that vary from one cycle to the next.^{1,17,18}
3. *Variable measures of success*—With IAC available for “rescue,” one may declare treatment “failure” with IVC sooner, even if that eye could ultimately be salvaged with increased intensity IV regimens.
4. *Variable measures of toxicity*—Because a course of IAC usually requires fewer treatment cycles than a course of IVC,⁶ the opportunity to develop cytopenias and other adverse events (the denominator) is numerically greater with IVC, and the drug regimens used for IAC may vary from one cycle to the next, making it difficult to identify the agent associated with the toxicity seen, especially when multiple agents are given simultaneously.
5. *Pharmacokinetic measures*—It is very difficult to measure and compare tissue drug levels during ongoing therapy, especially for intraocular structures.
6. *Patient-based dosing*—IVC dosing is based almost exclusively on patient weight or body surface area,¹⁶ whereas IAC doses are more standardized for all patients (with only broad attempts to alter dosing based on patient age).^{19,20}

Because of the difficulties studying IAC parameters in patients directly and to facilitate future drug discovery for IAC, we recently developed a rabbit model of IAC^{21,22} and a rabbit xenograft model^{21,23} in which to directly assess the efficacy of IAC²¹ and intravitreal chemotherapy.²⁴ We have also previously described a complete toxicity-assessment platform to better understand the mechanisms and drivers of ocular toxicity with IAC.¹³

Using our animal models combined with parallel studies in RB patients, the goal of this study was to compare the pharmacokinetics, efficacy, and ocular and systemic toxicity of IAC versus IVC in a highly controlled fashion that obviates some of the above-described challenges. Through these controlled

experiments, this study has created a unified model for the increased efficacy and decreased toxicity observed with IAC, based on the principle of relative ocular versus systemic pharmacokinetics, thus explaining the findings of many previous studies in the field.

Methods

Statement of Research Ethics

All animal experiments were performed under the auspices of the Vanderbilt Institutional Animal Care and Use Committee and adhered to the ARVO Statement for the Use of Animals in Ophthalmic and Vision Research. For clinical studies, Vanderbilt University Medical Center Institutional Review Board approval was obtained; this study adhered to the tenets of the Declaration of Helsinki and was performed in accordance with the Health Insurance Portability and Accountability Act. Informed consent was obtained from patients for all procedures performed.

Rabbit IAC Technique

All experiments used 2.7 – 3.2 kg New Zealand White rabbits. IAC was performed using the technique we have described previously.^{21,22} Briefly, surgical exposure of the femoral artery was obtained via cut-down, and an arteriotomy was created with a 4-French micropuncture system. The rabbits were heparinized, and a 1.5-French microcatheter was advanced into the common carotid artery under fluoroscopic guidance. Rabbits have both an internal and external ophthalmic artery (OA),²² and the dominant OA was determined angiographically. The microcatheter was navigated to the dominant OA for each particular rabbit, and the selected drug and dose of chemotherapy was infused over 5 minutes in a pulsatile fashion. All melphalan infusions were performed within 1 hour following reconstitution of the melphalan hydrochloride.

Pharmacokinetic Studies

We first explored the pharmacokinetics of drugs administered either intra-arterially or intravenously. Controlled experiments were performed in rabbits using the same dose of each drug via different routes, and drug levels in blood and ocular tissues were analyzed at serial time points. In humans, the studies focused on blood pharmacokinetics. Below, we describe the methodology for the rabbit studies and for the human studies, as well as the statistical analyses performed.

Rabbit Pharmacokinetic Studies

For carboplatin, the pharmacokinetic (PK) experiments utilized the clinically used dose of 50 mg for IAC, and an equivalent dose of 50 mg was used intravenously (comparable to the 18.6 mg/kg used in small children, for these 2.7- to 2.8-kg rabbits).¹⁷ For melphalan experiments, the intra-arterial or intravenous dose was 1.2 mg (0.4 mg/kg), based on prior work by our group and others.^{14,21} In the carboplatin experiments, rabbits were euthanized at one of five different time points: 30 minutes, 1 hour, 2 hours, 4 hours, or 6 hours following completion of the carboplatin infusion. For the carboplatin experiments, there were three rabbits per time point per route (IAC or IVC). For the melphalan experiments, all rabbits were sacrificed 30 minutes following completion of melphalan administration. For the melphalan experiments, there were three rabbits per route (IAC or IVC). Thus, there were 36 total rabbits across the PK experiments. All rabbits in the PK experiments were non-tumor-bearing. At the specified time points, the eyes were removed and ocular tissues isolated. All samples were immediately frozen on dry ice and stored at -80°C .

For the melphalan studies, vitreous, retina, and plasma samples were prepared with internal calibration standards as we described previously.^{21,23} Samples were analyzed on a TSQ Quantum Ultra mass spectrometer (Thermo Fisher Scientific, Waltham, MA) interfaced to an Acquity UPLC system (Waters, Milford, MA). For carboplatin studies, samples were thawed, and an aliquot of 200 μL was digested with 800 μL concentrated nitric acid (Optima grade; Thermo Fisher Scientific) overnight at 37°C . Digests were diluted to a total volume of 5 mL with deionized water and analyzed by direct injection using an Agilent 7700 series ICP-MS (Agilent Technologies, Santa Clara, CA) with a Cetac ASX-560 Autosampler (Teledyne Technologies, Thousand Oaks, CA). Platinum reference standards (TraceCERT) were procured from Sigma-Aldrich, St. Louis, MO); the instrument response was calibrated over a concentration range of 0.1 ppb to 10 ppm.

Patient Pharmacokinetics Studies

Patients receiving intra-arterial carboplatin to treat intraocular RB ($n = 3$ patients) or receiving IV carboplatin either for the treatment of intraocular RB or as adjuvant therapy following an enucleation in which there were pathologic high risk features ($n = 5$ patients) were included in this study, with all treatments provided as part of standard of care. Serial blood samples were obtained at 30 minutes, 1 hour, 2 hours, 4 hours, and 6 hours following completion of the carboplatin infusion, and plasma was isolated and frozen prior to being analyzed as described above.

Statistics for Pharmacokinetic Studies

The PK metrics (maximum concentration [C_{\max}] and area under the concentration time curve [AUC]) in rabbits and in patients were summarized in the figures using mean \pm SE unless otherwise specified. In rabbits, C_{\max} values between two treatment groups (or two sample types) were compared using Welch's *t*-test for independent samples and a paired *t*-test for related samples. In patients, the C_{\max} values from two treatment groups were evaluated using the linear mixed-effects model to account for the correlated observations within a patient. Using model-based (least-square) means, the concentrations by treatment were estimated and compared with the Wald test. The AUC from zero to the last observed time point ($AUC_{0-t_{\text{last}}}$) was estimated using the linear trapezoidal rule to approximate the integral. The 95% confidence interval for $AUC_{0-t_{\text{last}}}$ by sample type and their difference were estimated based on a *t*-distribution without assuming equal variance (Satterthwaite degrees of freedom). For correlated observations within a rabbit, the differences between sample types were calculated and used to estimate the difference mean AUC_D and its 95% confidence interval. Data were analyzed on a natural log, if necessary, to reduce variability of data or to meet normality assumptions.

Efficacy Studies

To compare the efficacy of IAC versus IVC, we first performed controlled experiments in rabbits. We then analyzed the real-world efficacy of IAC versus IVC in our clinical patient cohort. The methodology for these experiments is presented below, first for rabbits and then for the clinical patient cohort.

Rabbit Efficacy Studies

RB vitreous seeds were generated by injection of 1,000,000 WERI-Rb1 cells into the vitreous of cyclosporine-immunocompromised rabbits, as we have described previously.^{21,23,25,26} After waiting 2 weeks for the cells to form into vitreous seeds, rabbits were treated with a single administration of intra-arterial melphalan 3.6 mg (a clinically relevant dose, based on work by our group²¹ and others), intra-arterial saline, intravenous melphalan 3.6 mg, or intravenous carboplatin (18.6 mg/kg), etoposide (5 mg/kg), and vincristine (0.025 mg/kg) (IV CEV). Rabbits were sacrificed 2 weeks following treatment, and the eyes were removed, fixed, and prepared as we have described previously.^{13,21,23,25} Immunohistochemistry for cleaved caspase-3 antibody (ab208161; Abcam, Cambridge, UK) at a dilution of 1:100 was performed to assess for apoptosis with a BOND-MAX Autostainer (Leica

Microsystems, Wetzlar, Germany) using H2 antigen retrieval for 20 minutes. This caspase-3 antibody labels activated caspase-3 following induction of apoptosis. Slides were evaluated by an experienced veterinary pathologist (KLB).

Patient Efficacy Studies

We retrospectively reviewed the last 50 cycles of IAC and 50 cycles of IVC administered at our institution, for RB patients in whom there was at least 2 years of follow-up. Treatment success was defined as complete eradication of intraocular tumor by the primary treatment (IAC or IVC), without need for enucleation or external beam radiation and without the need for IAC rescue of IVC-treated eyes, and was compared using Kaplan–Meier survival estimates. This cohort has partial overlap with some patients included in a previously described cohort,⁶ although the outcome measures being assessed here are not the same.

Toxicity Studies

To study the ocular and systemic toxicity associated with IAC versus IVC, we first performed controlled rabbit experiments. We then analyzed the real-world toxicity of IAC versus IVC in our clinical patient cohort. The methodology for these experiments is presented below, first for rabbits and then for the clinical patient cohort.

Rabbit Toxicity Studies

Prior to planned chemotherapy administration, baseline retinal testing was performed using a previously described toxicity-assessment platform consisting of electroretinography (ERG), clinical ophthalmic examination, fundus photography, fluorescein angiography (FA), optical coherence tomography (OCT), and OCT angiography (OCTA), using protocols that we have described previously.^{13,23,26} OCT and OCTA were performed using a custom-built engine and ophthalmic scanner.²⁷ Complete blood counts (CBCs) were obtained prior to treatment and weekly until the time of euthanasia. Five to six weeks following the IAC or IVC treatment, the exact same retinal testing was performed prior to euthanasia, and both eyes were submitted for histopathology. Our predefined criteria for toxicity have been described in detail previously.^{13,23–25} Briefly, for a given cohort, toxicity for a given ERG parameter was defined for each cohort as a statistically significant worsening of 25% when comparing the post-treatment values with the pre-treatment values for that ERG parameter.

To evaluate the toxicity and compare the effect of treatment group over time (pre- or post-), a

linear mixed-effects model was fitted for each parameter and each test, as described previously.²³ Using model-based (least-square) means, the average change from pre- versus post-treatment and the difference in change between different treatment groups (difference of differences) were estimated and compared with the Wald test. The toxicity for a treatment is defined as above. Bonferroni-adjusted *P* values were reported to account for multiple comparisons between groups. All tests were two sided, with the *P* value cut-off for statistical significance set at 0.05. The analyses were performed using R 3.6.3, including packages “nlme” and “emmeans” (R Foundation for Statistical Computing, Vienna, Austria).

Patient Toxicity Studies

CBC data were obtained 7 to 10 days following IAC or IVC chemotherapy treatment to correspond with the known nadir in blood counts.²⁸ Combined Common Terminology Criteria for Adverse Events (CTCAE, v5.0) grade 3/4 anemia, thrombocytopenia, and neutropenia were recorded, as were the number of red cell transfusions, platelet transfusions, and granulocyte colony-stimulating factor administrations. These were compared between the IAC group and the IVC group using two-sample *t*-tests.

Results

Pharmacokinetics of IAC Versus IVC

In the PK experiments, IAC was compared to IVC in terms of total systemic exposure and drug levels in ocular tissues relative to total systemic exposure. In rabbits, doses were standardized regardless of route, and ocular tissue and blood levels were both measured. In patients undergoing active treatment, studies were limited to comparisons of systemic drug exposure (blood concentrations).

Pharmacokinetics in Rabbits

Following IAC administration of 50-mg carboplatin, maximum drug levels (C_{\max}) achieved in the retina of the treated eye ($1435 \pm 753 \mu\text{M}$) were greater than those achieved in the vitreous ($419 \pm 124 \mu\text{M}$), which in turn were greater than those achieved in the blood ($148 \pm 27 \mu\text{M}$); for retina versus vitreous, $P = 0.04$, and for vitreous versus blood, $P = 0.05$ (note that retina has a specific gravity of 1.0 g/mL²⁹). C_{\max} values for retina and vitreous were achieved by the 30-minute time point, and in the blood at 1 hour. The total carboplatin exposure, as measured by the AUC was also greater in the retina ($1446 \pm 325 \mu\text{M}\cdot\text{hr}$) than in the vitreous ($583 \pm 129 \mu\text{M}\cdot\text{hr}$; $P = 0.02$), consistent with

our previous findings of drug accumulation of melphalan in the retina following IAC.²¹ The observed AUC in the vitreous was greater than that in the blood ($359 \pm 55.5 \mu\text{M}\cdot\text{hr}$), but this effect did not reach statistical significance ($P = 0.106$).

Retina carboplatin levels achieved a C_{\max} following IAC ($1435 \pm 753 \mu\text{M}$) that was 134-fold greater than for IVC ($10.7 \pm 0.27 \mu\text{M}$; $P = 0.01$), and a 123-fold greater AUC following IAC ($1446 \pm 325 \mu\text{M}\cdot\text{hr}$) compared with IVC ($11.8 \pm 0.67 \mu\text{M}\cdot\text{hr}$; $P = 0.005$). Vitreous carboplatin levels achieved a C_{\max} following IAC ($419 \pm 124 \mu\text{M}$) that was 411-fold greater than IVC ($1.02 \pm 0.136 \mu\text{M}$; $P < 0.001$), and a 131-fold greater AUC following IAC ($583 \pm 129 \mu\text{M}\cdot\text{hr}$) compared with IVC ($4.44 \pm 0.907 \mu\text{M}\cdot\text{hr}$; $P = 0.02$). Blood carboplatin levels achieved a C_{\max} following IAC ($148 \pm 27 \mu\text{M}$) that was not statistically different from IVC ($145 \pm 14 \mu\text{M}$), and the AUC following IAC ($359 \pm 55 \mu\text{M}\cdot\text{hr}$) likewise did not differ statistically from IVC ($224 \pm 8.8 \mu\text{M}\cdot\text{hr}$) (Fig. 1).

Similarly, 30 minutes after intra-arterial administration of 1.2 mg of melphalan, the concentration achieved in the retina of the treated eye ($4.95 \pm 1.18 \mu\text{M}$) was 12-fold greater than that achieved following IVC ($0.415 \pm 0.058 \mu\text{M}$; $P = 0.003$), and the concentration achieved in the vitreous of the treated eye ($1.401 \pm 0.315 \mu\text{M}$) was 26-fold greater than that achieved following IVC ($0.054 \pm 0.013 \mu\text{M}$; $P < 0.001$). The concentration achieved in the vitreous of the untreated eye after IAC ($0.017 \pm 0.019 \mu\text{M}$), presumably via systemic recirculation following venous return, was statistically the same as that achieved following IVC. There was no difference between the concentrations achieved in the blood following IAC ($1.044 \pm 0.151 \mu\text{M}$) or IVC ($1.153 \pm 0.121 \mu\text{M}$; $P = 0.60$) (Fig. 2).

Pharmacokinetics in Patients

To corroborate our rabbit systemic drug exposure findings, we collected serial blood levels from RB patients following intra-arterial or intravenous administration of carboplatin being performed as part of standard-of-care treatment. The carboplatin dose was 18.6 mg/kg when given intravenously in a regimen that also included IV etoposide and vincristine. The intra-arterial carboplatin dose was 50 mg. Mixed-effect modeling demonstrated that the maximum carboplatin plasma concentrations were higher following IVC ($66.67 \mu\text{M}$; 95% confidence interval [CI], 50.90–87.33) than following IAC ($26.18 \mu\text{M}$; 95% CI, 21.34–32.12; $P = 0.01$). Similarly, AUCs were greater following IVC ($135.6 \mu\text{M}\cdot\text{hr}$; 95% CI, 114.3–156.9) than following IAC ($45.8 \mu\text{M}\cdot\text{hr}$; 95% CI, 39.5–52.1; $P < 0.001$) (Fig. 3).

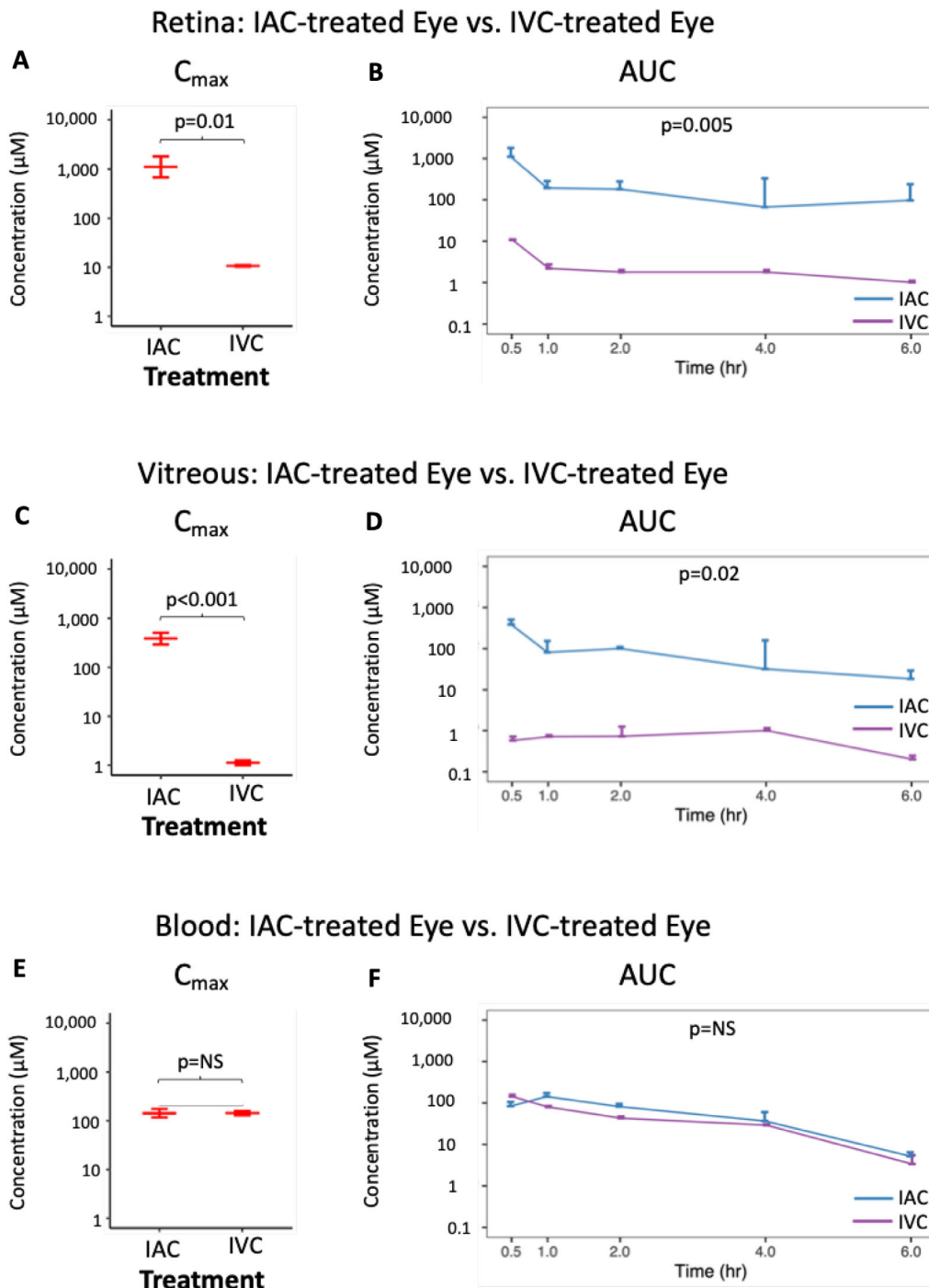


Figure 1. Carboplatin levels in the retina (A, B), vitreous (C, D), or blood plasma (E, F) following intra-arterial or intravenous administration in the rabbit model. The highest concentration achieved (C_{max}) is shown in panels A, C, and E, and the AUCs are shown in B, D, and F. For the same dose of carboplatin administered, the highest drug concentrations achieved (C_{max}) and overall drug exposure (AUC) in the retina and vitreous were both significantly greater for intra-arterial chemotherapy than for intravenous chemotherapy. However, the C_{max} and AUC in the blood was not significantly different based on the administration route. C_{max} values were analyzed on a natural log scale.

Because the plasma concentration is dependent on the volume of blood into which the chemotherapy dose is diluted and the patients were of different sizes, we compared the total carboplatin present

in the blood as the concentration \times estimated blood volume (EBV; estimated based on patient weight and the formula $EBV [mL] = weight [kg] \times 75 [mL/kg]$). Mixed-effect modeling demonstrated that

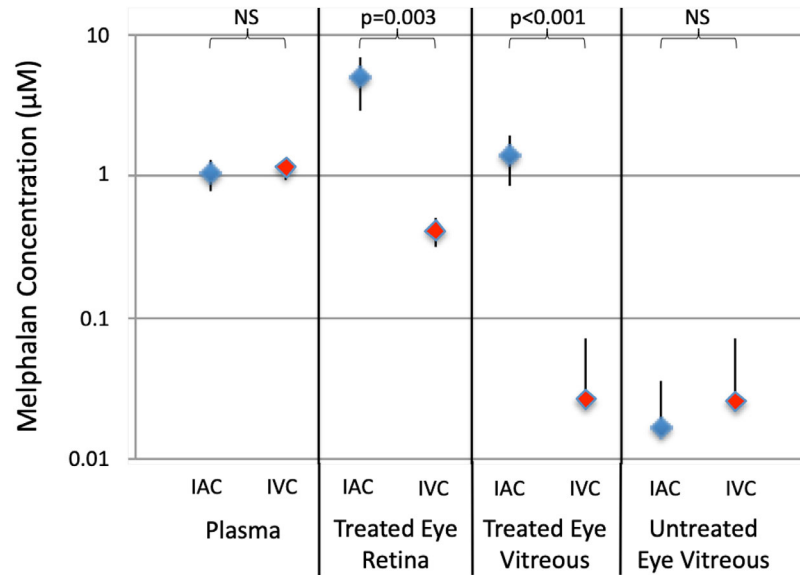


Figure 2. Melphalan levels in the retina, vitreous, and blood 30 minutes following either intravenous or unilateral intra-arterial administration in the rabbit model. For intravenous administration, the right eye was assigned as the treated eye, and retinal and vitreous drug levels were measured, whereas only vitreous levels were measured in the comparator left (untreated) eye. C_{max} values were analyzed on a natural log scale.

EBV-adjusted carboplatin levels were higher following IVC (55,023 $\mu\text{M}\cdot\text{mL}$; 95% CI, 37,534–80,660) than following IAC (18,938 $\mu\text{M}\cdot\text{mL}$; 95% CI, 14,280–25,115; $P = 0.01$). Similarly, AUCs were greater following IVC (111,478 $\mu\text{M}\cdot\text{mL}\cdot\text{hr}$; 95% CI, 99,270–123,686) than following IAC (36,019 $\mu\text{M}\cdot\text{mL}\cdot\text{hr}$; 95% CI, 30,938–41,099; $P < 0.001$) (Fig. 3).

It should be noted, however, that IVC patients received a much higher dose of carboplatin, on average, than did IAC patients (mean of 212 ± 57 mg for IV vs. 50 mg for IAC). Therefore, to truly compare the carboplatin blood exposure, we divided the total blood carboplatin calculated for each patient by the dose of carboplatin that was administered to give us the carboplatin plasma dose per dose of drug administered. Mixed-effect modeling demonstrated that there was no statistically significant difference between the C_{max} following IVC (264 $\mu\text{M}\cdot\text{mL}/\text{mg}$; 95% CI, 191–364) or IAC (396 $\mu\text{M}\cdot\text{mL}/\text{mg}$; 95% CI, 313–502), or between the AUC following IVC (547 $\mu\text{M}\cdot\text{mL}\cdot\text{hr}/\text{mg}$; 95% CI, 461–633) or IAC (720 $\mu\text{M}\cdot\text{mL}\cdot\text{hr}/\text{mg}$; 95% CI, 618–822), when accounting for the varying doses administered.

Comparative Efficacy of IAC Versus IVC

In rabbits, disease burden was standardized by injection of identical numbers of tumor cells, and identical melphalan doses were administered by IAC or IVC (and compared with the standard IV CEV regimen). In patients, efficacy was assessed based on

clinical response and treatment success in a retrospective cohort of patients.

Efficacy in Rabbits

A single intra-arterial administration of 3.6 mg melphalan in rabbits caused widespread disruption of vitreous seed xenografts and apoptosis in all tumor cells *in vivo*, as measured by the widespread induction of cleaved caspase-3 on immunohistochemistry 2 weeks following treatment (Fig. 4). In contrast, the same 3.6-mg dose of melphalan administered intravenously caused no apoptosis. Similarly, standard IV chemotherapy with CEV (see Methods section for dosing) was not effective against vitreous seed xenografts in rabbits (Fig. 4).

Efficacy in Patients

The planned cohort of ~ 50 IAC treatment cycles and ~ 50 IVC cycles actually consisted of 50 IAC cycles and 55 IVC cycles, as we did not want to break up the final IVC patient's six-cycle course. All eyes have at least 2 years of follow-up after treatment. There were no group E eyes in either group, as our practice at the time was to treat all group E eyes with primary enucleation. The 12 IVC-treated eyes (10 patients) included six group D eyes with diffuse seeds, and the 15 IAC-treated eyes (12 patients) included eight group D eyes with diffuse seeds (fraction group D for IVC vs. IAC, $P = 1.0$). Treatment success was achieved with IVC and local consolidation in six of 12 eyes (50%). Of the

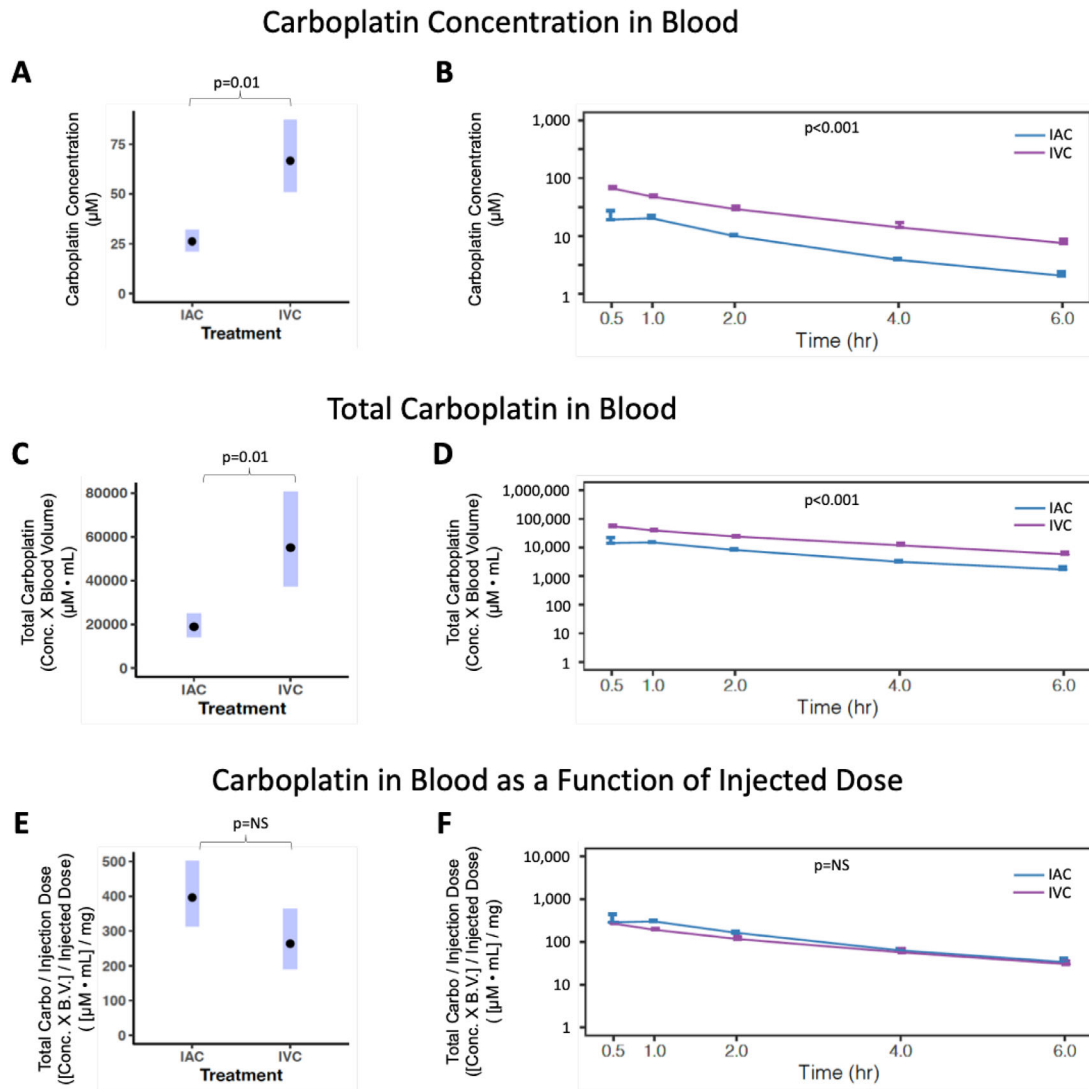


Figure 3. Carboplatin levels in the blood of patients following intra-arterial or intravenous administration. Blood levels of carboplatin vary as a function of infusion dose, not route of administration, with the same fraction of the initial drug entering the systemic circulation regardless of how it was administered. (A, B) Carboplatin concentrations measured in blood plasma. Significantly higher carboplatin concentrations were found with IVC than IAC. (C, D) When accounting for the calculated total blood volumes of the specific treated individuals, the total blood carboplatin concentrations were still greater with IVC than IAC. (E, F) Patients initially received different doses of carboplatin; IVC patients received much higher initial doses than IAC patients. When accounting for both the calculated total blood volume of each patient and the initial carboplatin dose that was infused, the total amount of carboplatin in the patients' blood was no different for IAC versus IVC patients. Data were analyzed on a natural log scale. The predicted mean with 95% CI are presented in parts A, C, and E.

six failures, one was immediately enucleated; the other five received IAC and were all rescued (and are also included in the IAC cohort). Treatment success was achieved in all 15 of the IAC-treated eyes (10 primarily treated and five treated as rescue following IVC). By Kaplan–Meier survival analysis, the probability of treatment success at 3 years was greater for IAC (100%; 95% CI, 100–100) than for IVC (47%; 95% CI, 25–88; $P = 0.0017$, log-rank test).

Toxicity With IAC Versus IVC

In rabbits, ocular and systemic toxicity was assessed during standardized experiments where identical melphalan doses were administered by IAC or IVC (and compared with the standard IV CEV regimen). In patients, toxicity was evaluated in a retrospective cohort of patients undergoing treatment with IAC or IVC for active RB.

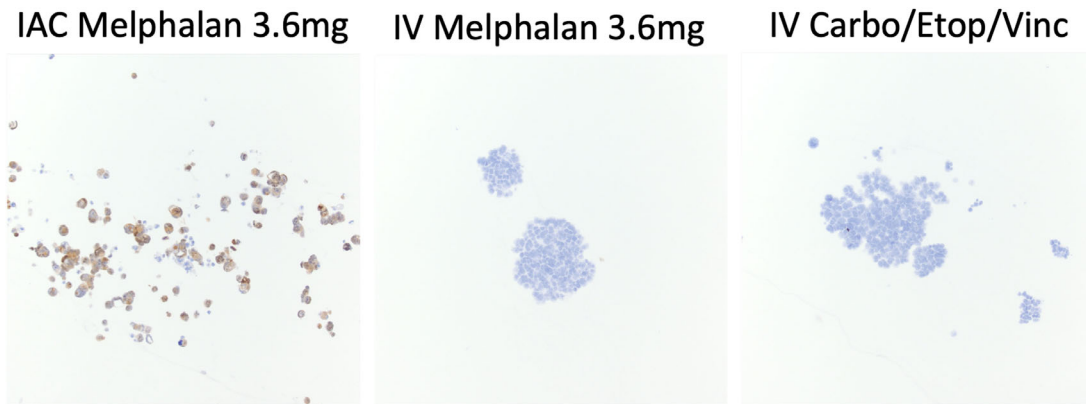


Figure 4. Efficacy of intra-arterial chemotherapy versus intravenous chemotherapy against retinoblastoma xenograft vitreous seeds in the rabbit model. This figure shows immunohistochemical staining with cleaved caspase-3, a marker for apoptosis. In this immunohistochemistry figure, *brown-stained* cells are undergoing apoptosis, and *blue cells* (i.e., cells that are not stained brown) are not undergoing apoptosis. (A) All vitreous seeds were significantly regressed in the IAC treated eye, with all retinoblastoma cells staining positively for cleaved caspase-3 via immunohistochemistry, indicating that they were all already undergoing apoptosis. In contrast, immunohistochemistry for cleaved caspase-3 revealed no positivity for retinoblastoma vitreous seed cells following administration of the same dose of melphalan intravenously (B) or following standard intravenous CEV administration (C).

Toxicity in Rabbits

Non-tumor-bearing rabbits were treated with unilateral intra-arterial melphalan (3.6 mg) or intra-arterial saline as a control, with IV melphalan (3.6 mg), or with IV CEV at standard weight-based doses (see Methods for CEV dosing). ERGs, fundus photos, FA, OCT, OCTA, and clinical examination were performed prior to chemotherapy treatment, and again at 5 to 6 weeks following treatment.

There were no significant reductions in ERG amplitudes, or prolongations of ERG implicit times, in any of the four treatment cohorts (Fig. 5). There were no major vascular occlusions on FA, no retinal microvascular loss on OCTA, no retinal thinning seen on OCT, and no retinal degeneration seen on histopathology in the IAC melphalan-treated cohort. Similarly, none of these signs of retinal structural toxicity was seen in the IV melphalan, IV CEV, or IA saline-treated cohorts.

For the rabbits treated with IAC carboplatin, massive periocular swelling necessitated euthanasia earlier than the 5–6 week time point, and so post-treatment ERGs, OCTs, or OCTAs were not performed. We have reported the carboplatin-induced toxicity findings previously.³⁰ Briefly, at both the 50-mg dose and at the rabbit eye size-adjusted dose of 25 mg, these findings included massive vasogenic edema of intraocular and extraocular structures, including conjunctival edema, extraocular muscle myodegeneration, and myonecrosis; temporally progressive choroidal necrotizing endarteritis; and retinal detachment and degeneration.

Weekly CBCs showed no cytopenias in any of the IAC melphalan, IA saline, IV melphalan, or IV CEV-treated cohorts. When looking at individual rabbits within each treatment cohort, rather than just the average across the entire cohort, we found that no rabbits in any of the cohorts experienced sustained cytopenias (Fig. 6).

Toxicity in Patients

Compared with patients treated with IAC, IVC-treated patients experienced more episodes of grade 3 or 4 anemia (IVC vs. IAC: 1.7 ± 1.6 vs. 0.08 ± 0.29 ; $P = 0.0098$), more episodes of grade 3/4 thrombocytopenia (2.7 ± 2.3 vs. 0.0 ± 0.0 ; $P = 0.0044$), and more episodes of grade 3/4 neutropenia (3.4 ± 1.9 vs. 1.3 ± 1.2 ; $P = 0.0075$) over the course of their treatment (Figs. 7A–7C). However, eyes treated with IAC received fewer treatments overall compared with IVC-treated eyes (3.9 ± 2.0 vs. 5.4 ± 1.1 ; $P = 0.02$). We therefore recalculated the likelihood of a grade 3 or 4 adverse hematological event per treatment cycle. IVC still caused higher rates of anemia (0.32 ± 0.29 vs. 0.01 ± 0.04 ; $P = 0.0086$), thrombocytopenia (0.5 ± 0.42 vs. 0.0 ± 0.0 ; $P = 0.0042$), and neutropenia (0.58 ± 0.3 vs. 0.31 ± 0.25 ; $P = 0.032$) even when calculating on a per-treatment-cycle basis (Figs. 7D–7F).

Discussion

In this study, which examines pharmacokinetics in a rabbit model and in RB patients in parallel, we propose

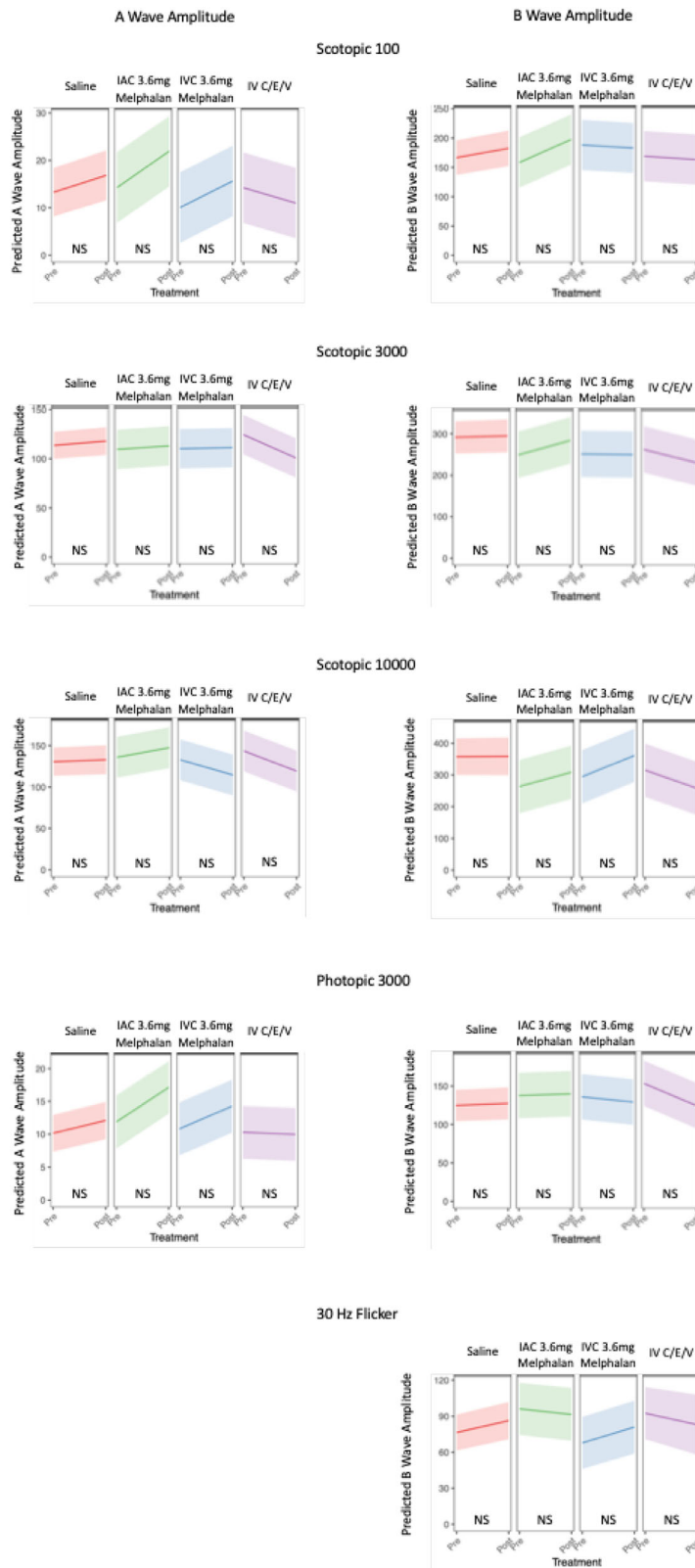


Figure 5. Comparative retinal toxicity of intra-arterial versus intravenous chemotherapy in the rabbit model. ERGs were obtained prior to and 6 weeks following treatment with intra-arterial saline, intra-arterial melphalan, intravenous melphalan, or intravenous CEV. Each is represented as an average of all rabbits in the treatment cohort, with the *shaded areas* representing the 95% confidence intervals. Changes in A-wave and B-wave amplitudes are shown for each test (except for 30-Hz flicker, for which there only exists a B-wave).

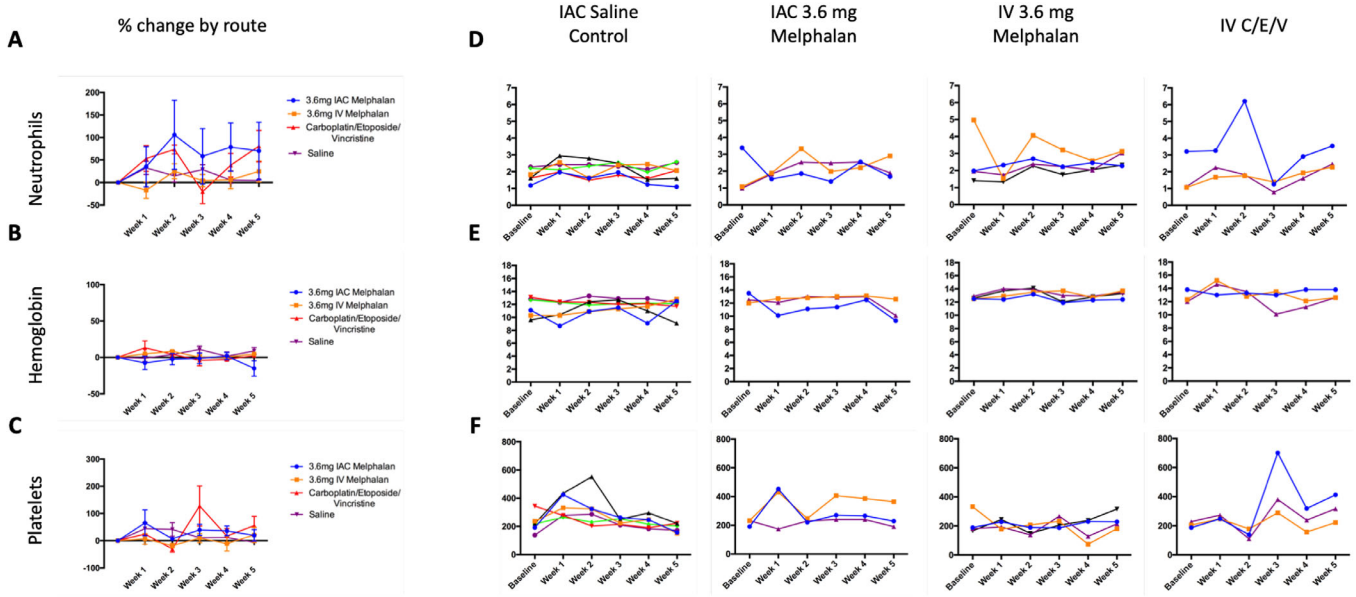


Figure 6. Comparative systemic toxicity of intra-arterial versus intravenous chemotherapy in the rabbit model. Weekly CBCs were obtained following intra-arterial saline, intra-arterial melphalan, intravenous melphalan, or intravenous CEV. (A–C) There were no significant differences in post-treatment absolute neutrophil counts (A), hemoglobin levels (B), or platelet counts (C) among the different treatment cohorts. In panels A to C, all are graphed as percent change from baseline. (D–F) Levels of each blood line are shown for individual rabbits in each cohort, demonstrating that there were no rabbits in any cohort that developed persistent reductions in absolute neutrophil counts (D), hemoglobin levels (E), or platelet levels (F) following treatment, regardless of route. For D–F, the different color line tracings each represent a different individual rabbit, and absolute blood counts (not percent change) are graphed.

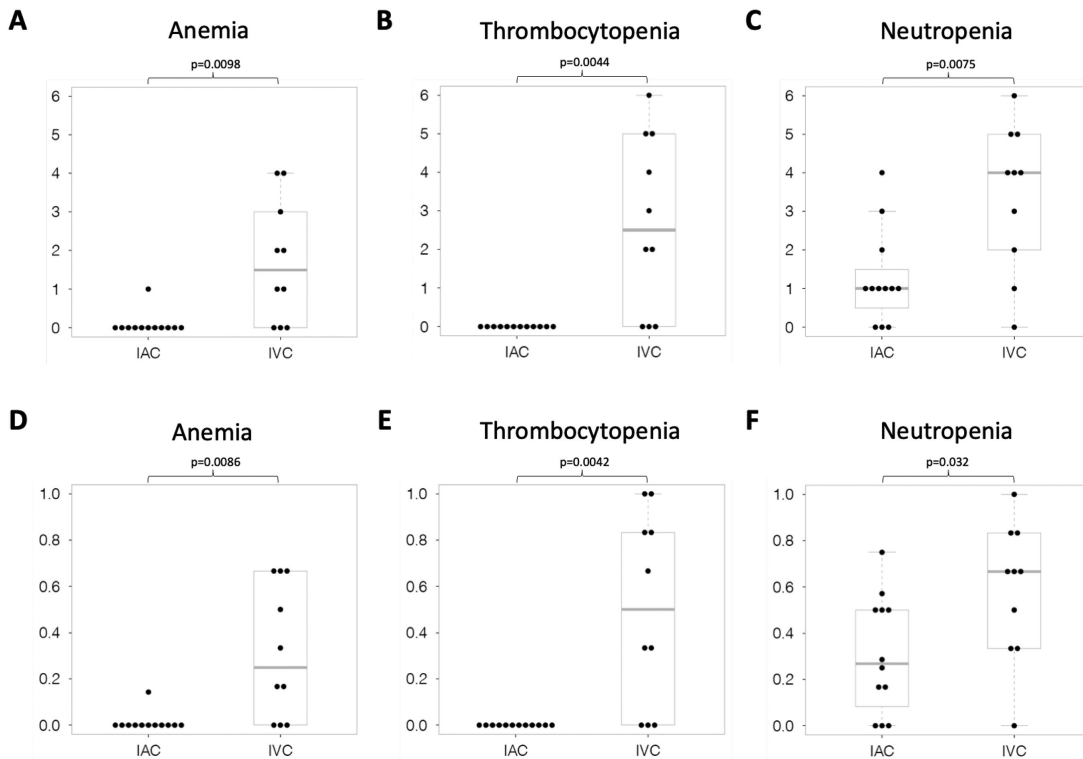


Figure 7. Comparative systemic toxicity of intra-arterial versus intravenous chemotherapy in retinoblastoma patients. (A–C) Total number of CTCAE grade 3 or 4 anemia (A), thrombocytopenia (B), and neutropenia (C) events over the entire course of either IAC or IVC treatment. (D–F) Number of CTCAE grade 3 or 4 anemia (D), thrombocytopenia (E), and neutropenia (F) events *per treatment cycle*, for patients treated with either IAC or IVC.

a potential overarching explanation for the clinically observed increased efficacy of IAC compared with IVC for advanced RB with vitreous seeds. These findings also explain toxicities specific to each treatment modality.

In the rabbit model, we confirmed that IAC ocular pharmacokinetics are superior to IVC; however, systemic exposure (blood levels) did not differ for a given infusion dose regardless of route. In the rabbit experiments, eradication of all xenograft vitreous seeds was achieved following a single intra-arterial treatment of melphalan, whereas IV CEV (or IV melphalan) could not eradicate the vitreous seeds in rabbits. In the rabbit model, IAC melphalan at clinically used doses did not cause retinal functional/structural toxicity or cytopenias. Similarly, in our patient cohort, carboplatin blood levels did not differ following IVC or IAC after normalizing for patient blood volume and treatment dose. Tumor eradication rates were higher in the IAC cohort, and treatment with IVC resulted in greater grade 3 and 4 cytopenias than did IAC.

We initially studied carboplatin, because this is the only drug used routinely in clinical practice via both the intra-arterial and intravenous routes (although it should be noted that carboplatin is used somewhat less frequently as monotherapy for IAC^{17,31} and is more commonly administered as part of a multi-agent intra-arterial regimen^{8,18}). In the rabbit model, the ocular tissue drug levels achieved in the treated eye were many times higher when delivered via IAC compared with IVC. Conversely, it would require a much higher IV dose to achieve the high intraocular drug levels seen with IAC. This difference in ocular drug levels has clinical implications, as a clinically used dose of melphalan administered intra-arterially completely eradicated vitreous seed xenografts in the rabbit model, whereas the same dose given intravenously did not. Similarly, the standard IV CEV regimen had no effect on vitreous seeds in rabbit eyes. The greatest relative advantage of IAC occurs in those advanced eyes with vitreous seeds⁷; thus, these experiments used a xenograft model of vitreous seeds to compare the efficacy of IAC and IVC.

The efficacy with IAC seen in our patients is unsurprising given the higher ocular drug levels in the pharmacokinetic experiments in the rabbits. We acknowledge that the higher globe salvage observed in IAC patients may be due in part to treatment bias. Treatment bias exists in retrospective clinical studies of efficacy such as ours because treating physicians know that IAC is readily available as “rescue.” Thus, they might abandon the initial IVC treatment course even if a prolonged course of IVC or second-line chemotherapy agents or extensive local consolidation near vision-

critical structures might have ultimately allowed the globe to be salvaged. Indeed, this was a factor in our IVC patients, as five patients were transitioned to IAC for rescue, and this might account for the relatively low rate of globe salvage seen with IVC in this study, which was consistent with other reported IVC success rates.³² This limitation of reporting with retrospective treatment cohorts is well known in the field and thus underscores the utility of the controlled animal experiments conducted in our study.

Our rabbit and patient pharmacokinetic studies demonstrate that systemic doses of drug achieved in the blood are equivalent, regardless of route of administration, for an equal infusion dose. In the rabbits, this point was underscored by the observation that contralateral (untreated) eyes of unilaterally treated IAC rabbits achieved drug concentrations equivalent to those seen in (both) eyes of IVC-treated rabbits. This demonstrates that the full chemotherapy dose infused into the ophthalmic artery ultimately enters the blood supply through systemic recirculation. Schaiquevich’s group previously showed that differences in topotecan³³ or melphalan³⁴ plasma concentrations following IAC are largely attributable to differences in patient weight. Our findings support and extend this point by demonstrating that, when comparing IAC to IVC, the differences in plasma concentrations are a function of both differences in patient weight and also differences in the dose that is infused with each treatment route.

Systemic adverse events are well documented with IVC treatment for RB.^{11,12} Cytopenias and resultant transfusions have been reported to be lower with IAC than IVC,²⁰ although grade 3 or 4 neutropenias occur in ~40% of IAC patients at some point during their IAC course.^{1,13} The question is whether this reduced systemic toxicity is truly related to the route of administration. In these rabbit experiments, which directly compared the same dose of melphalan injected intra-arterially versus intravenously, we demonstrated that there were no differences in hematologic parameters based on route. In the patient cohort, cytopenia events were more common with IVC, because the increased efficacy of a given dose of chemotherapy administered intra-arterially allows lower doses to be given with IAC. Higher doses of chemotherapy must be given intravenously to achieve tumor control, consistent with previous findings of low vitreous chemotherapy levels following IVC in patients.³⁵ Similarly, although the blood concentrations in patients following IAC or IVC did not differ on a “per milligram administered” basis, the actual drug concentrations measured in patient blood samples were much higher with IVC. This underscores that greater doses of drug are required with each IVC treatment to achieve the desired ocular

efficacy. In addition, the higher ocular concentrations observed with IAC in our rabbit experiments (underlying the greater efficacy of IAC) likely contribute to the reduced number of treatment cycles required. This reduces the number of cycles in which a cytopenia event could occur. Taken together, the above indicates that the greater ocular efficacy-to-systemic toxicity “ratio” seen with IAC compared with IVC is a function of the greater ocular drug concentration-to-systemic drug concentration “ratio” seen with IAC.

A possible adverse consequence of IAC is that it does not address unrecognized micrometastatic disease, which is a potential benefit of IVC pointed out by Wilson et al.³⁶ Our finding that the full dose of IAC enters the systemic circulation is therefore important, although it is not known if IAC drugs have an impact on RB micrometastases at these blood concentrations. This secondary systemic effect of drugs infused into the ophthalmic artery may explain the low rate of metastases reported in IAC patients,³⁷ which is lower than expected based on the known prevalence of pathologic high-risk features in group D and E eyes and the risk of metastasis in eyes with high-risk features.^{38–40}

We previously reported a higher rate of ocular adverse events with IAC than IVC in patients.⁶ However, the majority of ocular complications reported in that study were minor and transient, such as periocular erythema or edema. This clinical experience was recapitulated in the rabbit experiments presented here, with periocular edema with IAC carboplatin being similar to what has been reported occasionally in IAC carboplatin-treated patients,^{13,30} or in patients who received carboplatin as part of multiagent therapy.⁴¹ We have previously demonstrated dose-dependent retinal toxicity with IAC melphalan in this rabbit model.¹³ However, with the clinically relevant melphalan doses used in the experiments presented here, these toxic effects were not seen. Other studies have reported rates of chorioretinal atrophy as high as 10% to 15% following IAC in clinical practice,¹⁵ and higher rates of retinal and orbital vascular adverse events were found in other animal IAC models.⁴² Treating physicians must be cognizant of this risk and the consequent possible effect on visual outcomes in selecting a treatment modality.

Conclusions

Through parallel rabbit and human studies, we demonstrated that the greater efficacy and lower toxicity associated with IAC compared with IVC is specifically attributable to the greater ocular-to-systemic drug concentration “ratio” achieved with IAC, which obviates the need for the otherwise massive intra-

venous doses that would be required to achieve the high intraocular concentrations seen with IAC, which are necessary to eradicate vitreous seeds. However, treating physicians should be aware that the entire intra-arterial drug dose does ultimately reach the systemic circulation. This unified theory for the increased efficacy and decreased toxicity seen with IAC, based on the underlying principle of relative ocular-to-systemic pharmacokinetics, therefore provides a rubric with which to understand many of the previously reported clinical findings in the IAC literature.

Acknowledgments

Supported by a grant from the National Eye Institute, National Institutes of Health (NIH/NEI K08EY027464 to ABD), by a Career Starter Grant from the Knights Templar Eye Foundation (ABD), by a Career Development Award from the Research to Prevent Blindness Foundation (ABD), and by an unrestricted departmental grant from Research to Prevent Blindness to the Vanderbilt Department of Ophthalmology and Visual Sciences. This work was also supported by a Department of Veterans Affairs Senior Research Career Scientist Award (AR) and by a Vanderbilt Ingram Cancer Center Support Grant (CA68485) for core facilities.

Portions of this work were presented at the International Society of Ocular Oncology Meeting in 2019 (Los Angeles, CA); the ARVO Annual Meeting in 2019 (Vancouver, British Columbia); the Macula Society Annual Meetings in 2017 (Los Angeles, CA) and 2019 (Bonita Springs, FL); and the American Academy of Ocular Oncology and Pathology Annual Meeting in 2019 (San Francisco, CA).

Disclosure: **A.B. Daniels**, Vanderbilt University (P), Spectrum Pharmaceuticals (R); **M.T. Froehler**, Medtronic (C, R), Stryker (C, R), Blockade Medical (C), Control Medical (C), Microvention (R), Penumbra (R); **J.V. Kaczmarek**, None; **C.M. Bogan**, None; **P.R. Santapuram**, None; **J.M. Pierce**, None; **S.-C. Chen**, None; **E.A. Schremp**, None; **K.L. Boyd**, None; **Y.K. Tao**, None; **M.W. Calcutt**, None; **T. Koyama**, None; **A. Richmond**, None; **D.L. Friedman**, Vanderbilt University (P)

* Current affiliation: Medical University of South Carolina, Charleston, SC, USA

** Emory University School of Medicine, Atlanta, GA, USA

† Gilead Sciences, Inc., Foster City, CA, USA

References

- Abramson DH, Daniels AB, Marr BP, et al. Intra-arterial chemotherapy (ophthalmic artery chemosurgery) for group D retinoblastoma. *PLoS One*. 2016;11(1):e0146582.
- Shields CL, Mashayekhi A, Au AK, et al. The International Classification of Retinoblastoma predicts chemoreduction success. *Ophthalmology*. 2006;113(12):2276–2280.
- Shields CL, Honavar SG, Meadows AT, et al. Chemoreduction plus focal therapy for retinoblastoma: factors predictive of need for treatment with external beam radiotherapy or enucleation. *Am J Ophthalmol*. 2002;133(5):657–664.
- Abramson DH, Dunkel IJ, Brodie SE, Kim JW, Gobin YP. A phase I/II study of direct intraarterial (ophthalmic artery) chemotherapy with melphalan for intraocular retinoblastoma initial results. *Ophthalmology*. 2008;115(8):1398–1404, 1404.e1.
- Abramson DH, Shields CL, Munier FL, Chantada GL. Treatment of retinoblastoma in 2015: agreement and disagreement. *JAMA Ophthalmol*. 2015;133(11):1341–1347.
- Santapuram PR, Schremp EA, Friedman DL, Koyama T, Froehler MT, Daniels AB. Adverse events, treatment burden, and outcomes of intravenous versus intra-arterial chemotherapy for retinoblastoma. *Ophthalmol Retina*. 2021;5(3):309–312.
- Shields CL, Jorge R, Say EA, et al. Unilateral retinoblastoma managed with intravenous chemotherapy versus intra-arterial chemotherapy. outcomes based on the international classification of retinoblastoma. *Asia Pac J Ophthalmol (Phila)*. 2016;5(2):97–103.
- Zheng Y, Froehler MT, Friedman DL, Daniels AB. Intra-arterial chemotherapy as primary treatment for cavitary retinoblastoma: excellent response in eight tumors. *Ophthalmol Retina*. 2021;5(5):479–485.
- Yuan S, Friedman DL, Daniels AB. Evolution of chemotherapy approaches for the treatment of intraocular retinoblastoma: a comprehensive review. *Int Ophthalmol Clin*. 2017;57(1):117–128.
- Yuan S, Friedman DL, Daniels AB. Alternative chemotherapeutic agents for the treatment of retinoblastoma using the intra-arterial and intravitreal routes: a path forward toward drug discovery. *Int Ophthalmol Clin*. 2017;57(1):129–141.
- Rodriguez-Galindo C, Wilson MW, Haik BG, et al. Treatment of intraocular retinoblastoma with vincristine and carboplatin. *J Clin Oncol*. 2003;21(10):2019–2025.
- Bartuma K, Pal N, Kosek S, Holm S, All-Ericsson C. A 10-year experience of outcome in chemotherapy-treated hereditary retinoblastoma. *Acta Ophthalmol*. 2014;92(5):404–411.
- Daniels AB, Froehler MT, Nunnally AH, et al. Rabbit model of intra-arterial chemotherapy toxicity demonstrates retinopathy and vasculopathy related to drug and dose, not procedure or approach. *Invest Ophthalmol Vis Sci*. 2019;60(4):954–964.
- Dunkel IJ, Shi W, Salvaggio K, et al. Risk factors for severe neutropenia following intra-arterial chemotherapy for intra-ocular retinoblastoma. *PLoS One*. 2014;9(10):e108692.
- Ancona-Lezama D, Dalvin LA, Lucio-Alvarez JA, Jabbour P, Shields CL. Ophthalmic vascular events after intra-arterial chemotherapy for retinoblastoma: real-world comparison between primary and secondary treatments. *Retina*. 2019;39(12):2264–2272.
- Murphree AL, Villablanca JG, Deegan WF, 3rd, et al. Chemotherapy plus local treatment in the management of intraocular retinoblastoma. *Arch Ophthalmol*. 1996;114(11):1348–1356.
- Francis JH, Gobin YP, Dunkel IJ, et al. Carboplatin +/- topotecan ophthalmic artery chemosurgery for intraocular retinoblastoma. *PLoS One*. 2013;8(8):e72441.
- Marr BP, Brodie SE, Dunkel IJ, Gobin YP, Abramson DH. Three-drug intra-arterial chemotherapy using simultaneous carboplatin, topotecan and melphalan for intraocular retinoblastoma: preliminary results. *Br J Ophthalmol*. 2012;96(10):1300–1303.
- Gobin YP, Dunkel IJ, Marr BP, Brodie SE, Abramson DH. Intra-arterial chemotherapy for the management of retinoblastoma: four-year experience. *Arch Ophthalmol*. 2011;129(6):732–737.
- Fischer C, Petriccione M, Vitolano S, Guarini E, Davis ME, Dunkel IJ. The effect of ophthalmic artery chemosurgery on immune function in retinoblastoma patients: a single institution retrospective analysis. *J Pediatr Hematol Oncol*. 2017;39(7):555–559.
- Daniels AB, Froehler MT, Pierce JM, et al. Pharmacokinetics, tissue localization, toxicity, and treatment efficacy in the first small animal (rabbit) model of intra-arterial chemotherapy for retinoblastoma. *Invest Ophthalmol Vis Sci*. 2018;59(1):446–454.

22. Froehler MT, Feldman MJ, Poitras B, Daniels AB. Angiographic investigation of orbital vascular variations in the rabbit and implications for endovascular intra-arterial chemotherapy models. *J Neurointerv Surg*. 2021;13(6):559–562.
23. Daniels AB, Pierce JM, Chen SC. Complete pre-clinical platform for intravitreal chemotherapy drug discovery for retinoblastoma: Assessment of pharmacokinetics, toxicity and efficacy using a rabbit model. *MethodsX*. 2021;8:101358.
24. Bogan CM, Pierce JM, Doss SD, et al. Intravitreal melphalan hydrochloride vs propylene glycol-free melphalan for retinoblastoma vitreous seeds: efficacy, toxicity and stability in rabbits models and patients. *Exp Eye Res*. 2021;204:108439.
25. Bogan CM, Kaczmarek JV, Pierce JM, et al. Evaluation of intravitreal topotecan dose levels, toxicity, and efficacy for retinoblastoma vitreous seeds: a preclinical and clinical study [online ahead of print]. *Br J Ophthalmol*, <https://doi.org/10.1136/bjophthalmol-2020-318529>.
26. Kaczmarek JV, Bogan CM, Pierce JM, et al. Intravitreal HDAC inhibitor, belinostat, effectively eradicates vitreous seeds without retinal toxicity in vivo in a rabbit retinoblastoma model [online ahead of print]. *Invest Ophthalmol Vis Sci*.
27. Bozic I, Li X, Tao Y. Quantitative biometry of zebrafish retinal vasculature using optical coherence tomographic angiography. *Biomed Opt Express*. 2018;9(3):1244–1255.
28. Xiang E, Ni J, Glotzbecker B, Laubach J, Soiffer R, McDonnell AM. Evaluating the adverse effects of melphalan formulations. *J Oncol Pharm Pract*. 2019;25(7):1631–1637.
29. Stefansson E, Wilson CA, Lightman SL, Kuwabara T, Palestine AG, Wagner HG. Quantitative measurements of retinal edema by specific gravity determinations. *Invest Ophthalmol Vis Sci*. 1987;28(8):1281–1289.
30. Oatess TL, Chen PH, Daniels AB, Himmel LE. Severe periocular edema after intraarterial carboplatin chemotherapy for retinoblastoma in a rabbit (*Oryctolagus cuniculus*) model. *Comp Med*. 2020;70(2):176–182.
31. Abramson DH, Marr BP, Francis JH, et al. Simultaneous bilateral ophthalmic artery chemosurgery for bilateral retinoblastoma (tandem therapy). *PLoS One*. 2016;11(6):e0156806.
32. Daniels AB, Patel SN, Milam RW, Kohanim S, Friedman DL, Koyama T. Effect of intravenous chemotherapy regimen on globe salvage success rates for retinoblastoma based on disease class—a meta-analysis. *Cancers (Basel)*. 2021;13(9):2216.
33. Taich P, Ceciliano A, Buitrago E, et al. Clinical pharmacokinetics of intra-arterial melphalan and topotecan combination in patients with retinoblastoma. *Ophthalmology*. 2014;121(4):889–897.
34. Schaiquevich P, Buitrago E, Taich P, et al. Pharmacokinetic analysis of melphalan after superselective ophthalmic artery infusion in preclinical models and retinoblastoma patients. *Invest Ophthalmol Vis Sci*. 2012;53(7):4205–4212.
35. Abramson DH, Frank CM, Chantada GL, et al. Intraocular carboplatin concentrations following intravenous administration for human intraocular retinoblastoma. *Ophthalmic Genet*. 1999;20(1):31–36.
36. Wilson MW, Haik BG, Dyer MA. Superselective intraophthalmic artery chemotherapy: what we do not know. *Arch Ophthalmol*. 2011;129(11):1490–1491.
37. Abramson DH, Shields CL, Jabbour P, et al. Metastatic deaths in retinoblastoma patients treated with intraarterial chemotherapy (ophthalmic artery chemosurgery) worldwide. *Int J Retina Vitreous*. 2017;3:40.
38. Fabian ID, Stacey AW, Chowdhury T, et al. High-risk histopathology features in primary and secondary enucleated International Intraocular Retinoblastoma Classification group D eyes. *Ophthalmology*. 2017;124(6):851–858.
39. Kaliki S, Shields CL, Rojanaporn D, et al. High-risk retinoblastoma based on international classification of retinoblastoma: analysis of 519 enucleated eyes. *Ophthalmology*. 2013;120(5):997–1003.
40. Wilson MW, Qaddoumi I, Billups C, Haik BG, Rodriguez-Galindo C. A clinicopathological correlation of 67 eyes primarily enucleated for advanced intraocular retinoblastoma. *Br J Ophthalmol*. 2011;95(4):553–558.
41. Friedman EL, Froehler MT, Daniels AB. Orbital swelling in a child with retinoblastoma following intra-arterial chemotherapy. *JAMA Ophthalmol*. 2021;139(3):357–358.
42. Tse BC, Steinle JJ, Johnson D, Haik BG, Wilson MW. Superselective intraophthalmic artery chemotherapy in a nonhuman primate model: histopathologic findings. *JAMA Ophthalmol*. 2013;131(7):903–911.